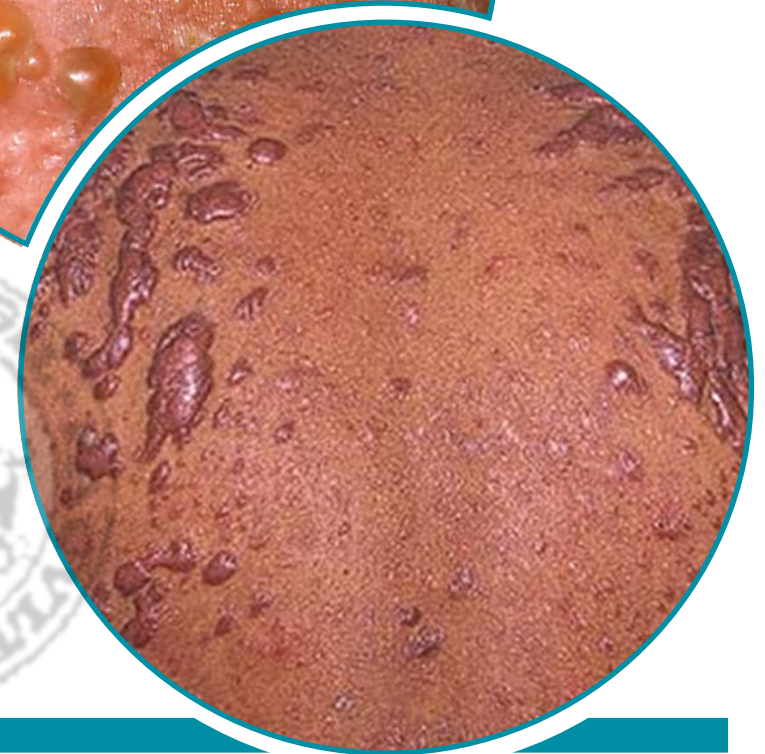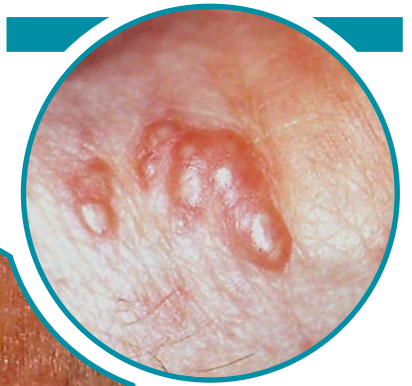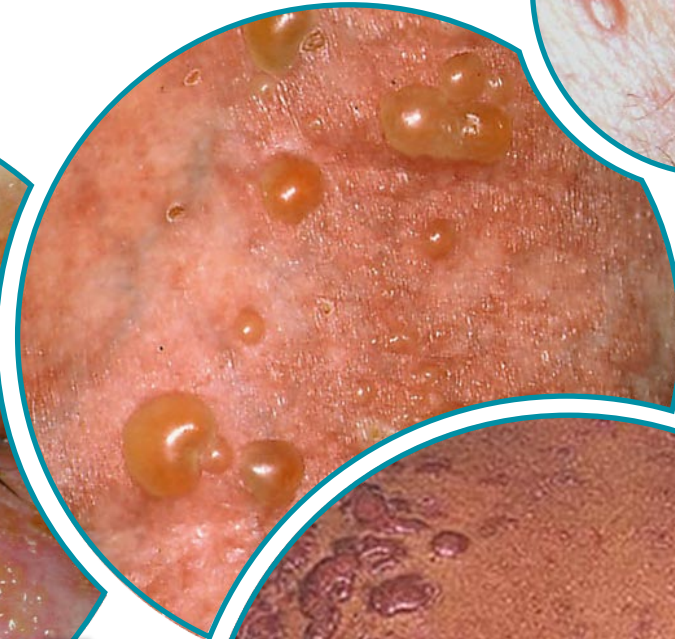
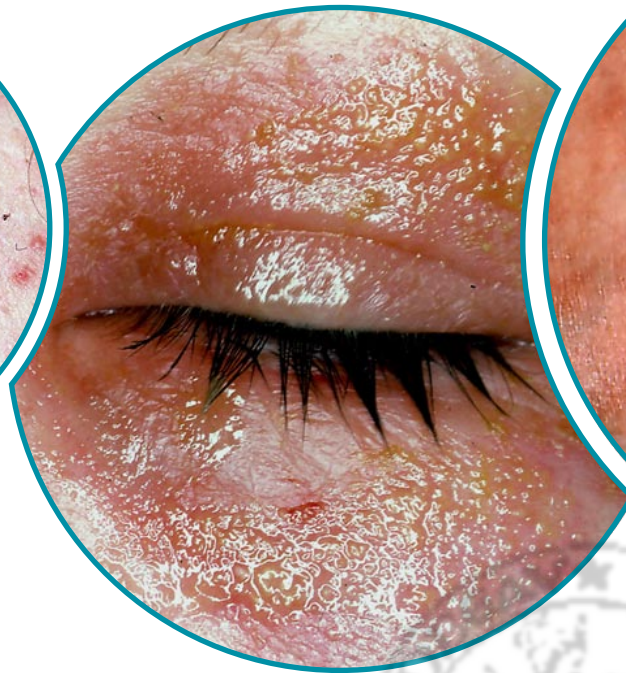
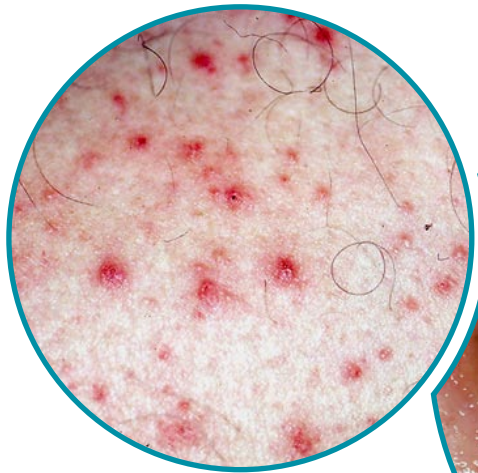


Lésions élémentaires cliniques et anatomo-pathologiques



- Dr. Anne Croué
- Pr. Ludovic Martin
- UE "Revêtement cutané" | L2
- 2011-2012



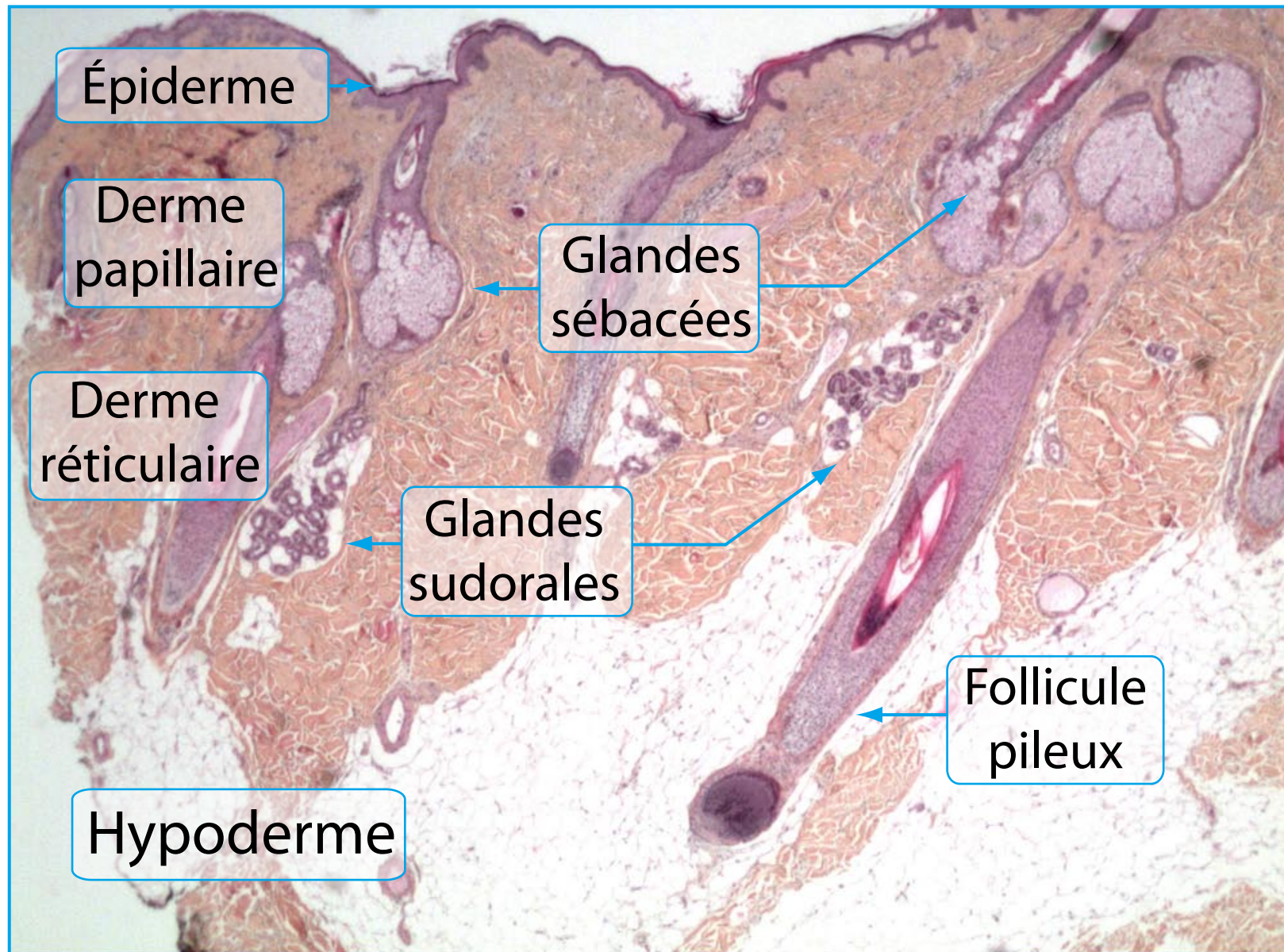
université
angers

FACULTÉ
DE MÉDECINE

Principes diagnostiques en dermatologie

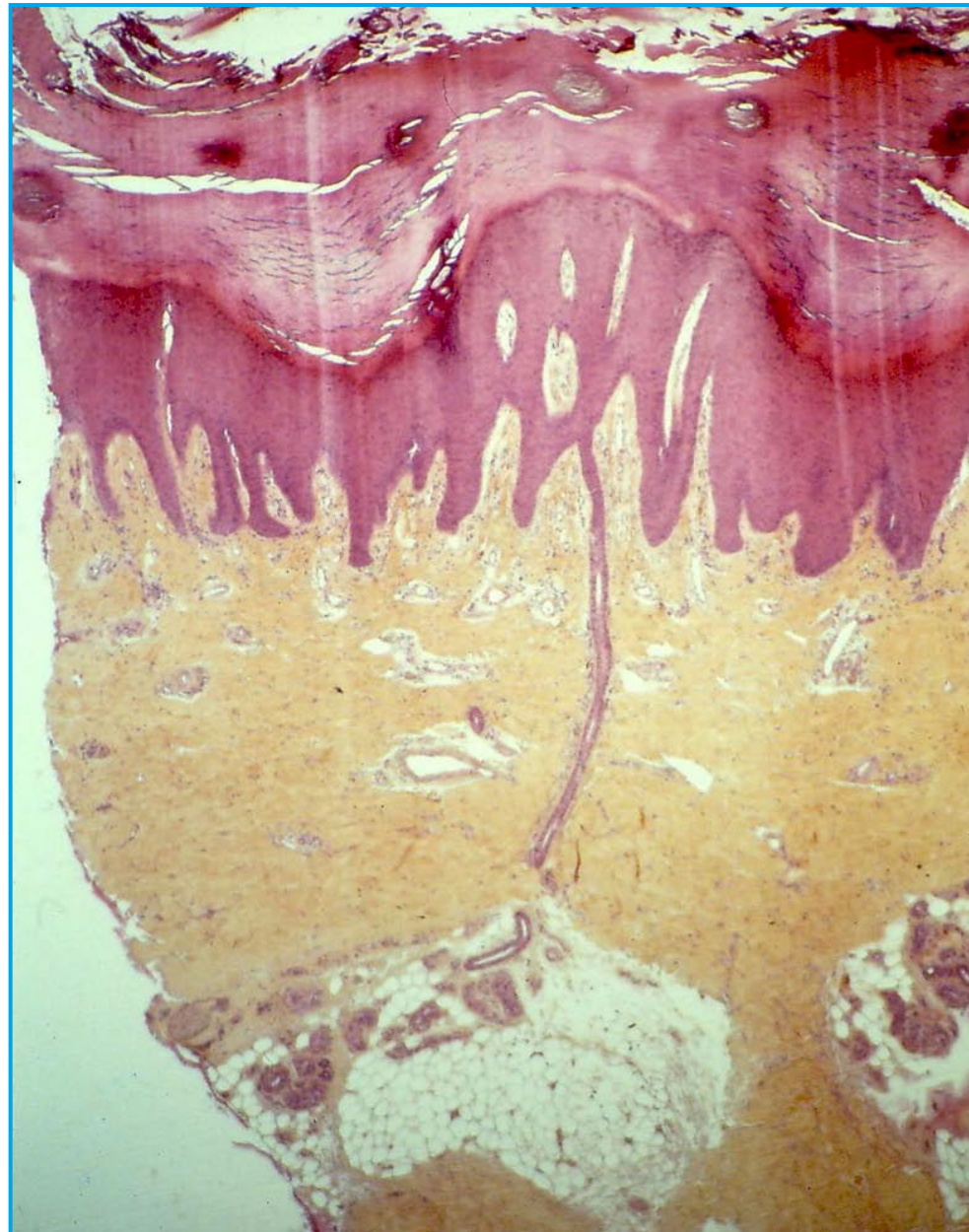
- ▶ Démarche diagnostique synthétique
 - ▷ Analyse des lésions élémentaires
 - ▷ Histoire naturelle
 - ▷ Distribution
 - ▷ Signes associés
 - ▷ Contexte
- ▶ La démarche diagnostique en dermatologie nécessite de maîtriser un vocabulaire précis

Principes diagnostiques en dermatologie



Principes diagnostiques en dermatologie

- — Peau acrale
- — Couche cornée
- — Épiderme
- — Derme
- — Hypoderme

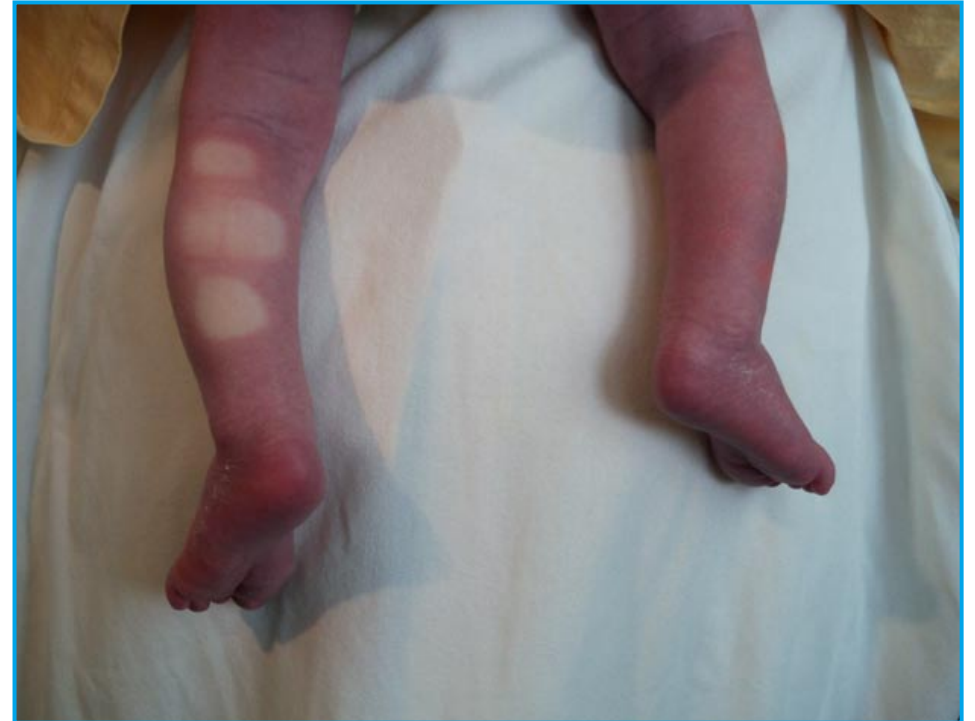
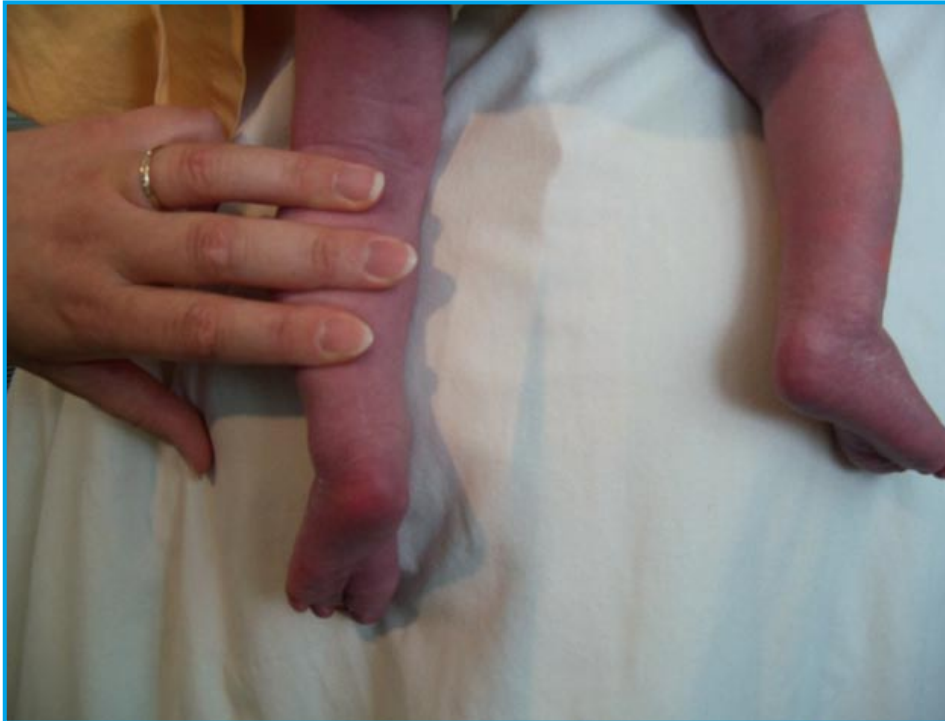
Lésion tissulaire non palpable

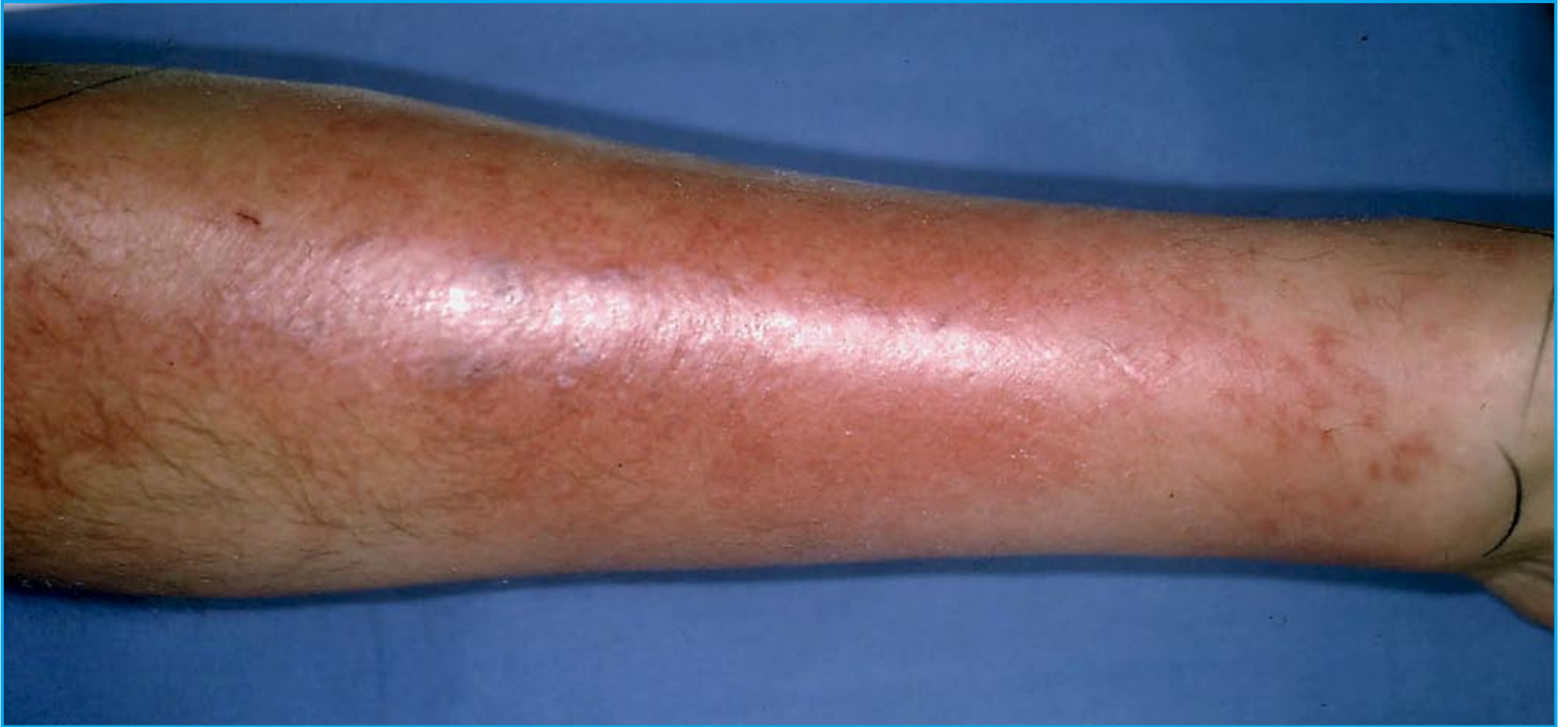Macule

- ▶ Simple modification de la couleur de la peau
- ▶ Macule érythémateuse
 - ▷ Érythème : rouge
- ▶ Macule purpurique
 - ▷ Purpura : violacé
- ▶ Macule pigmentée
- ▶ Macule dépigmentée
- ▶ Macule vasculaire

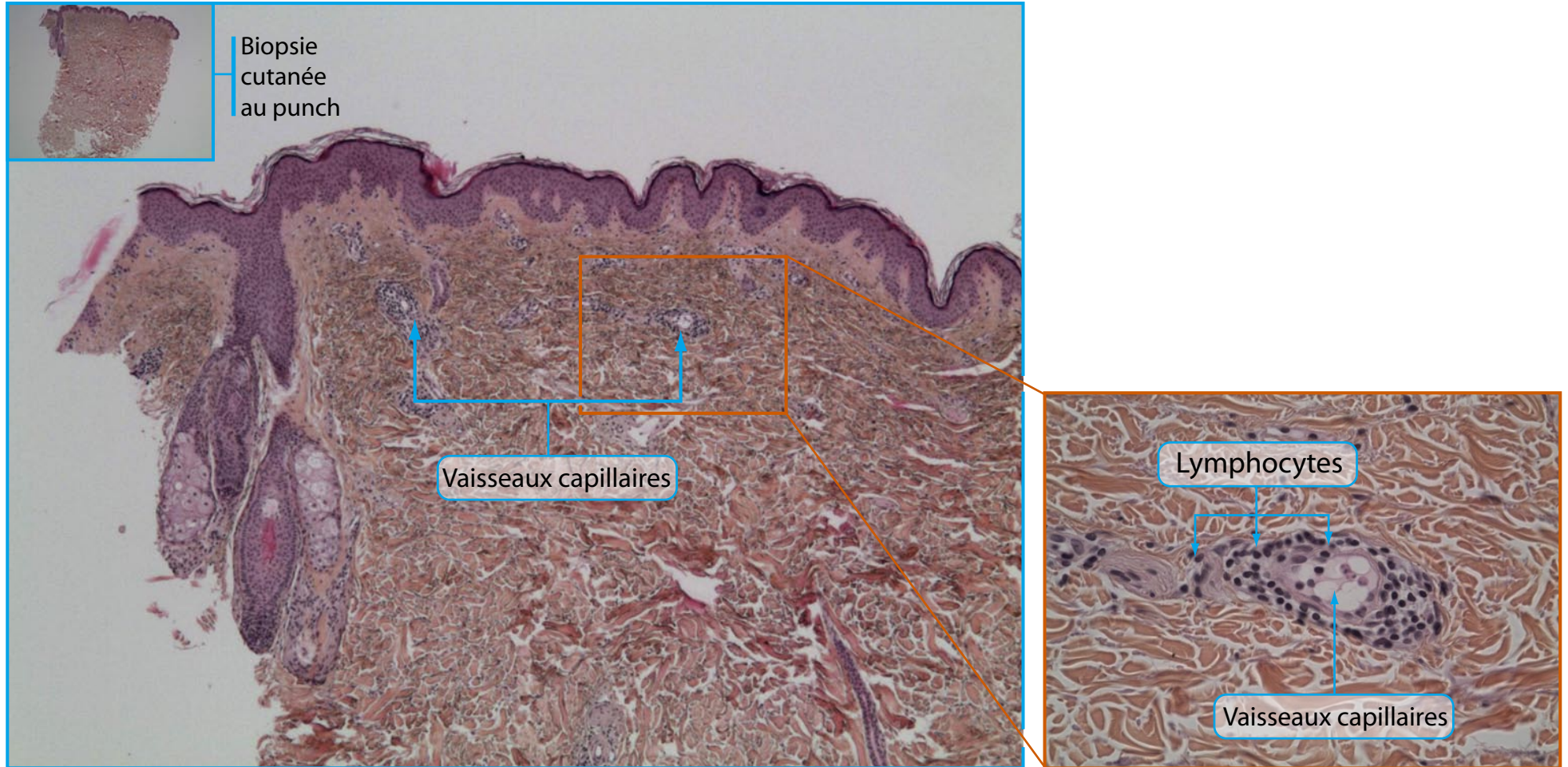
Érythème



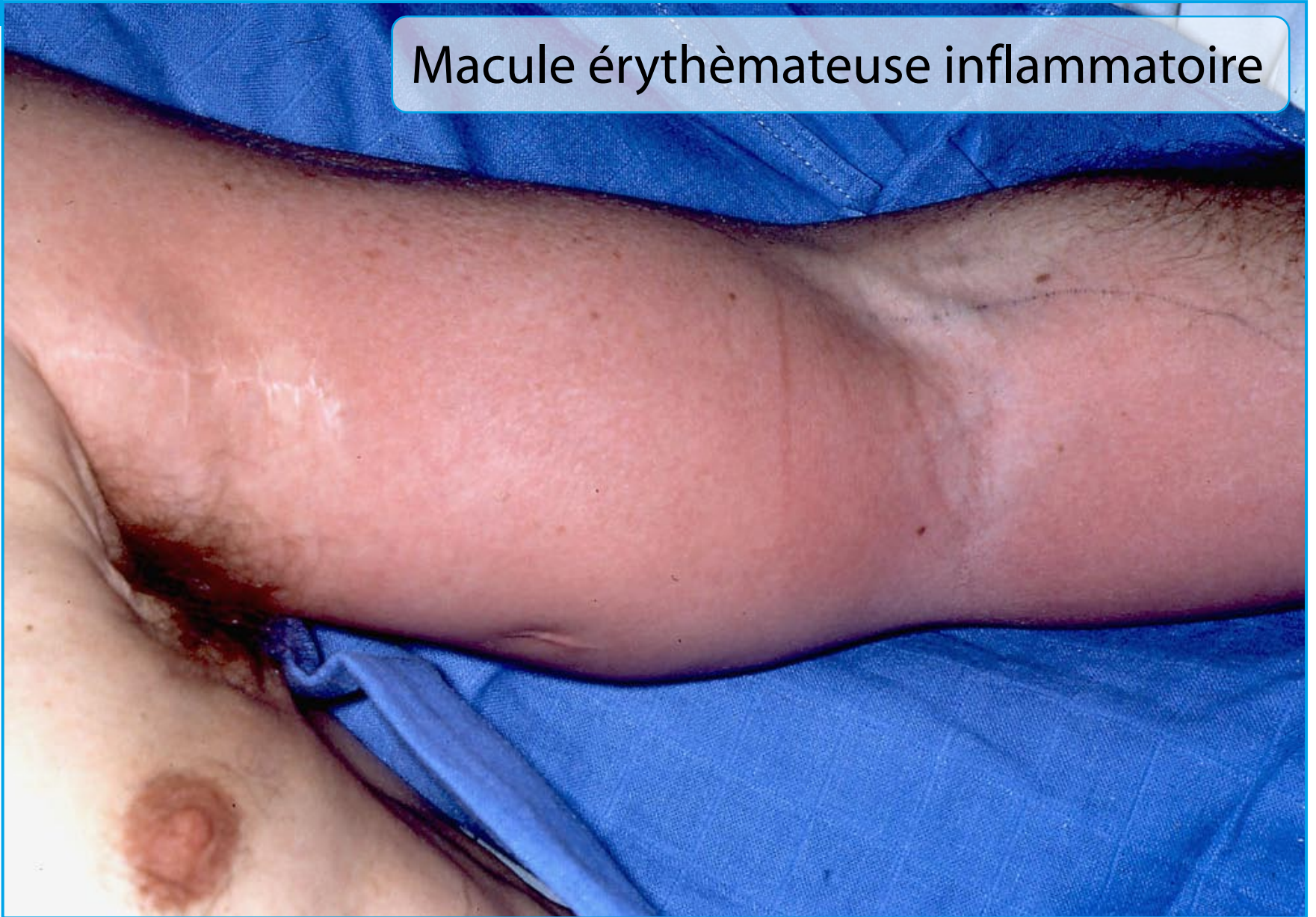
Macule érythémateuse inflammatoire

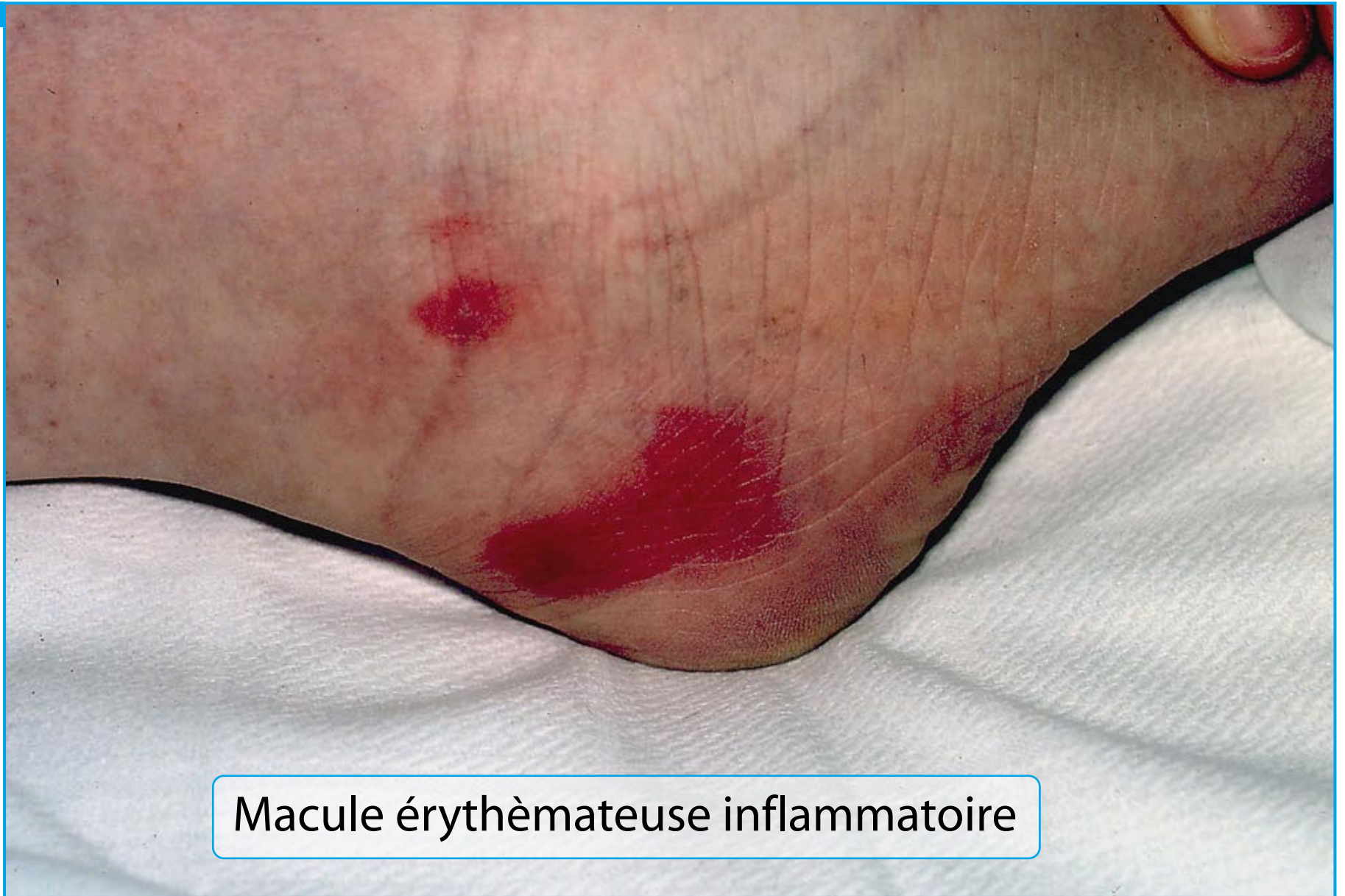

Biopsie cutanée



Macule érythémateuse inflammatoire

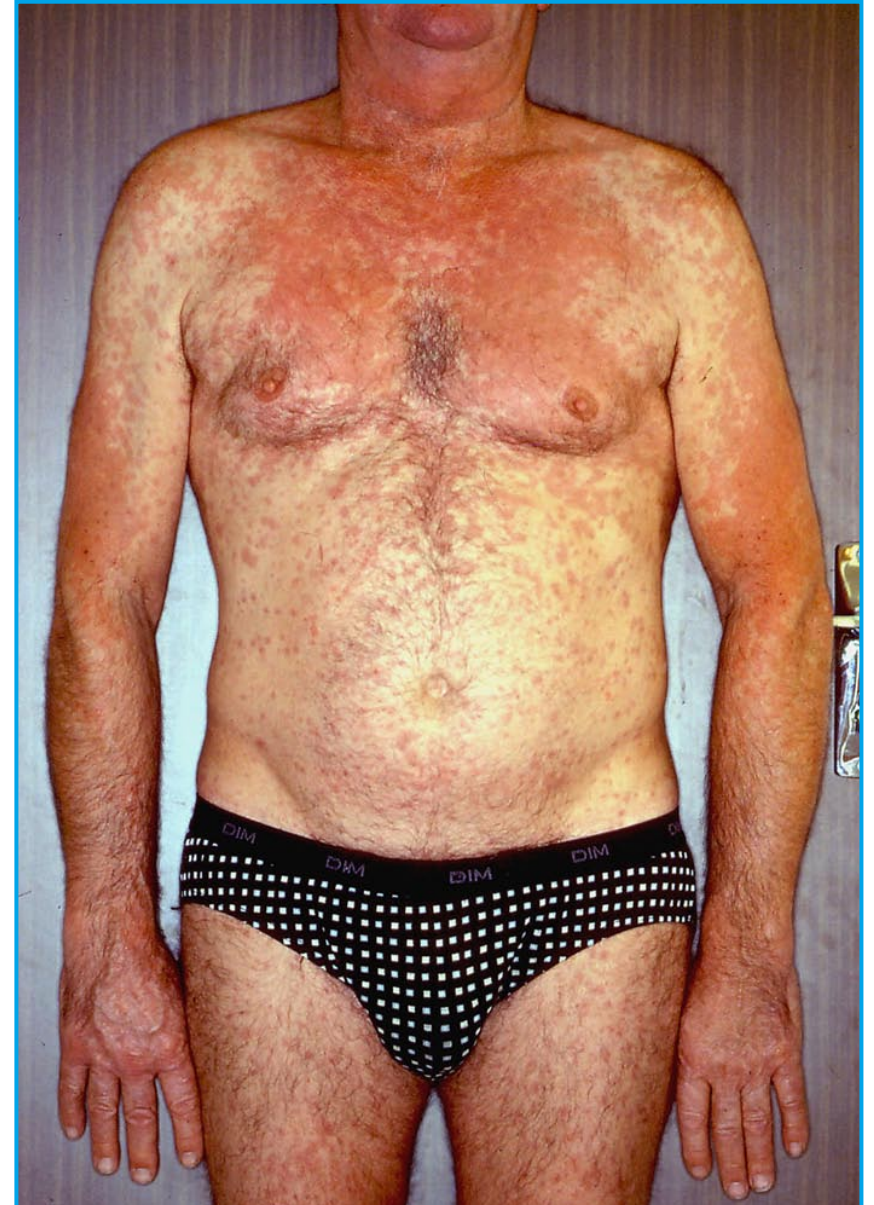



Macule érythémateuse inflammatoire

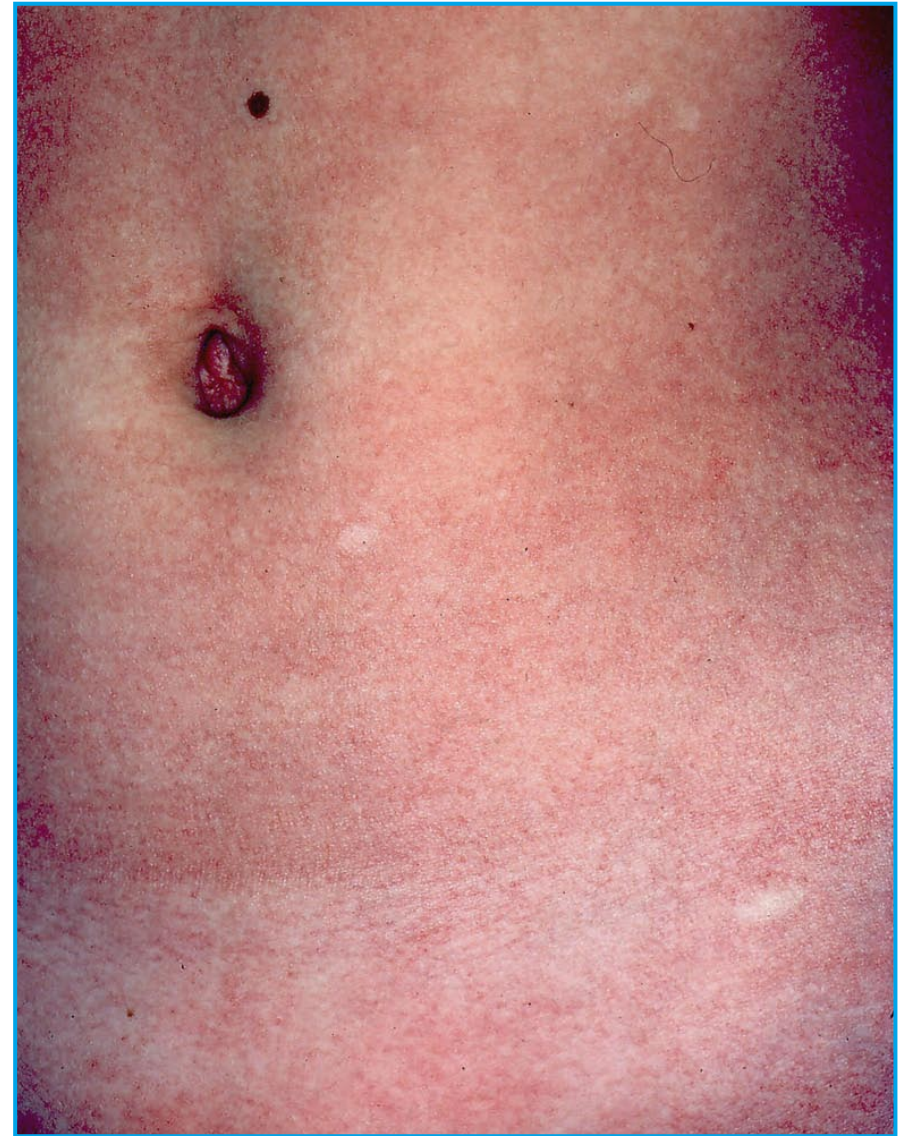Éruption érythémateuse

- ▶ Exanthème morbilliforme, avec intervalles de peau saine



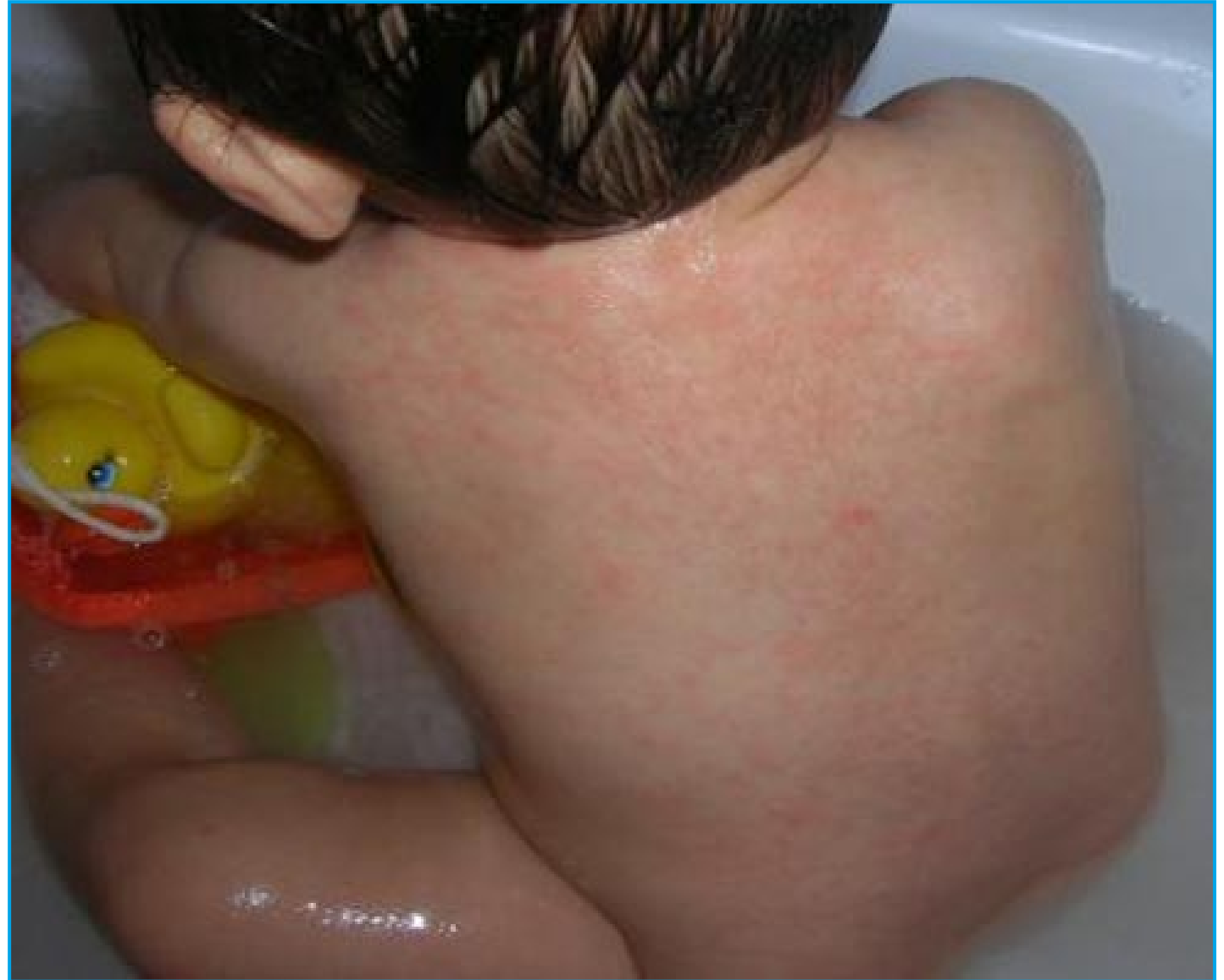Exanthème scarlatiniforme

- ▶ Pas d'intervalle de peau saine
Desquamation



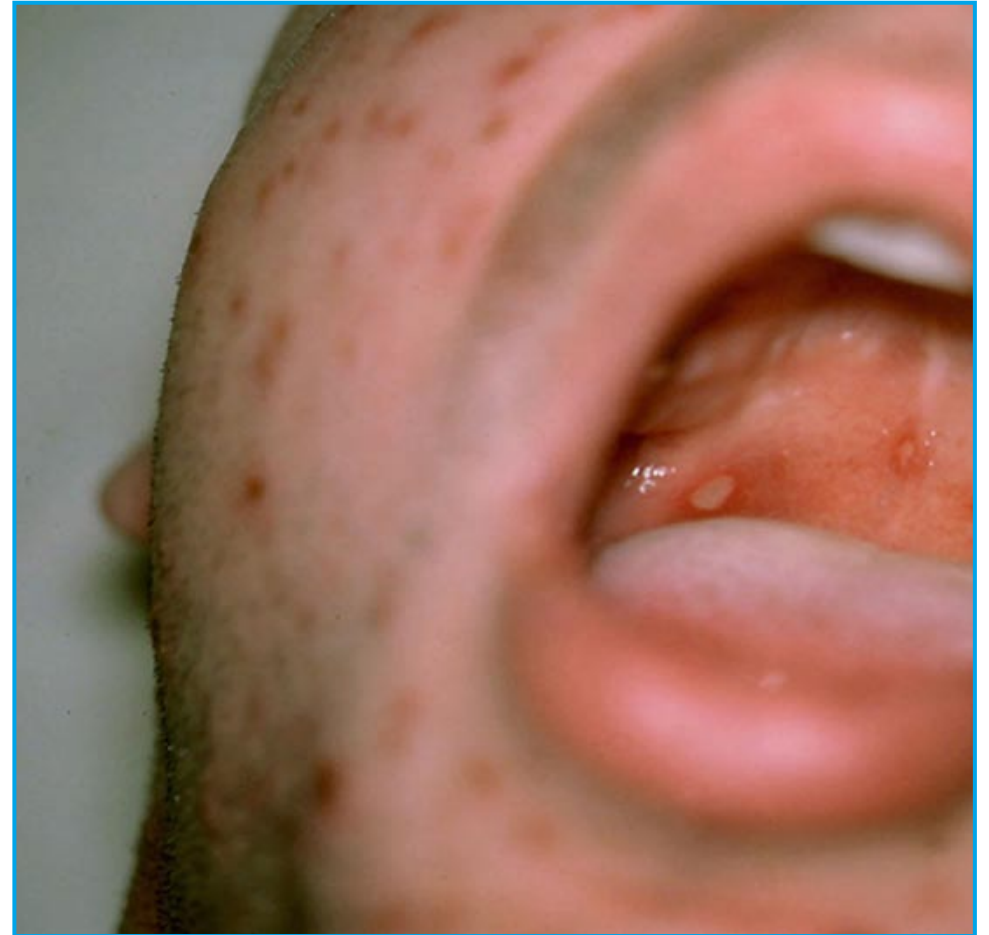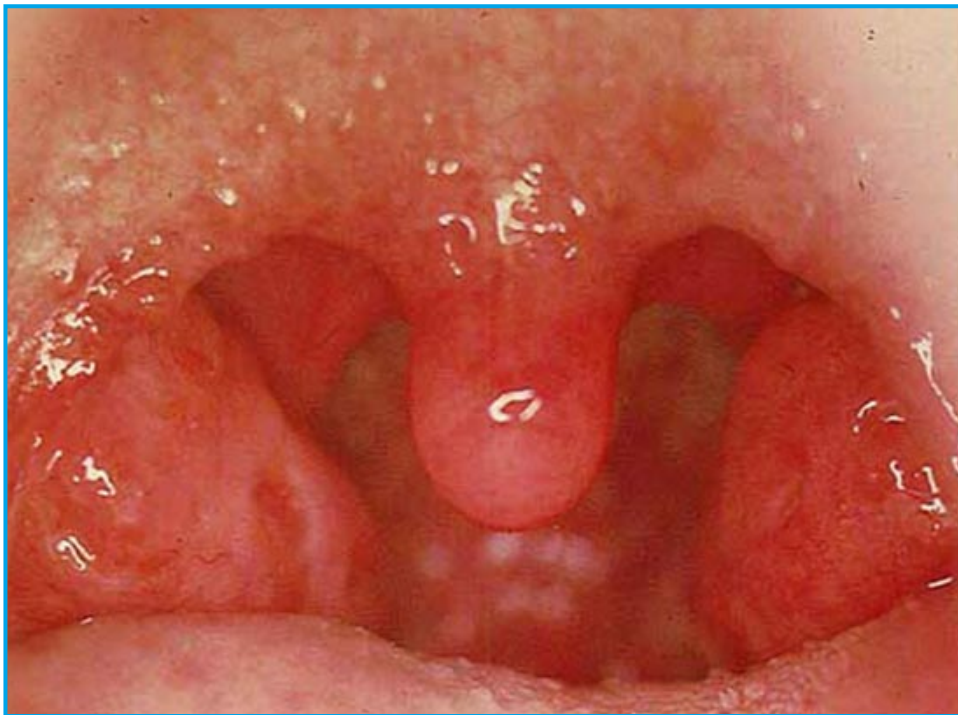Exanthème roséoliforme

- ▶ Plus discret

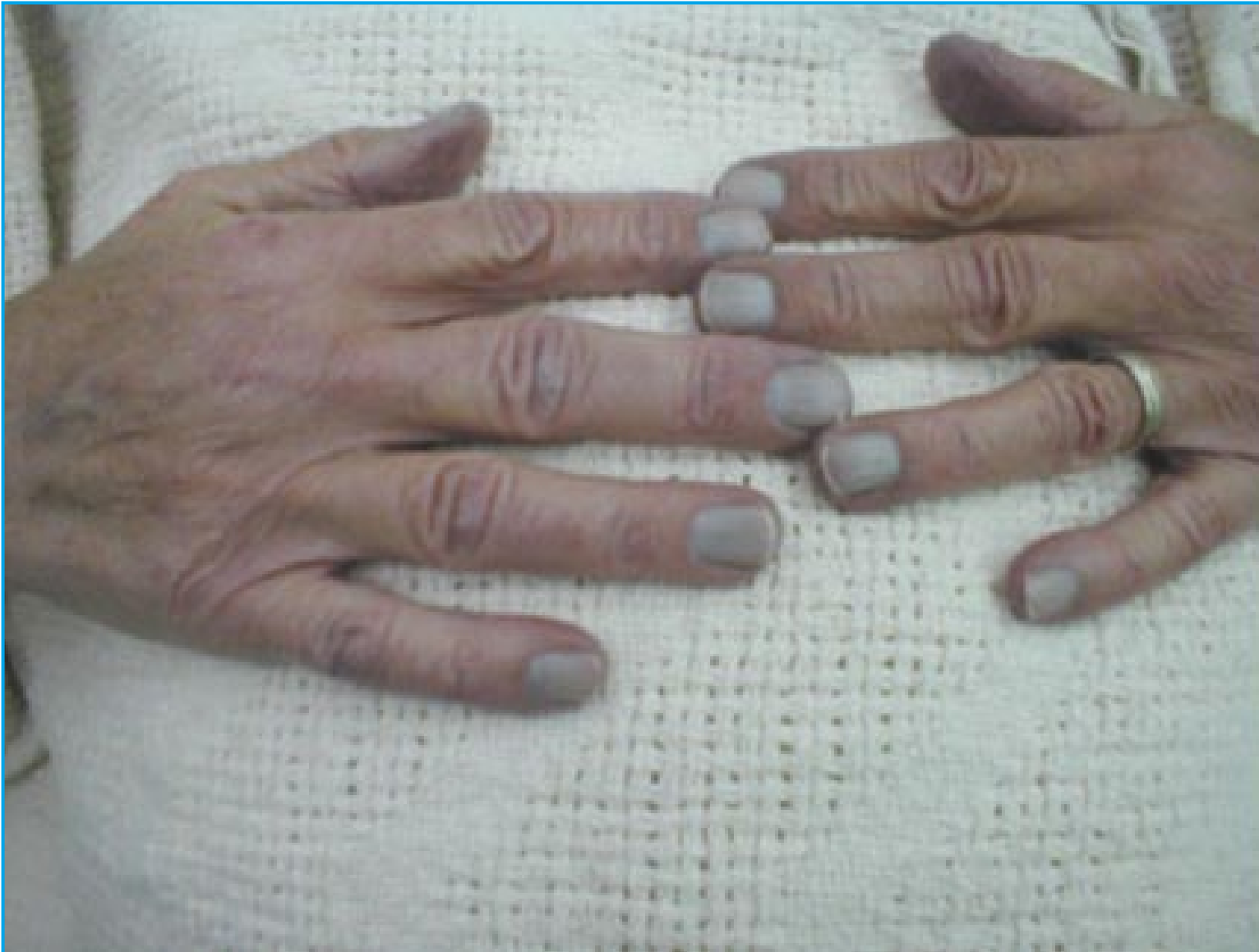

Énanthème

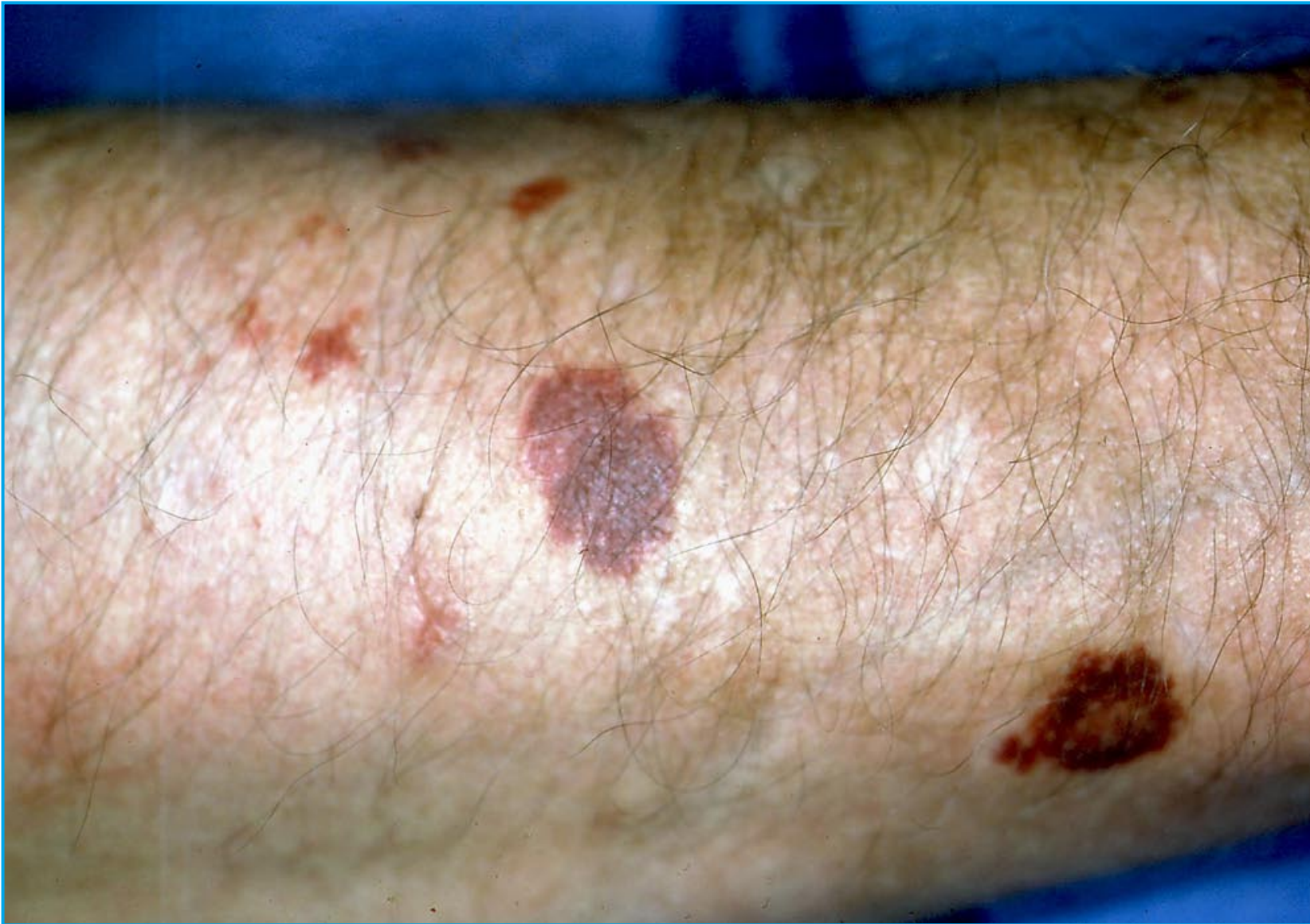- ▶ Éruption muqueuse



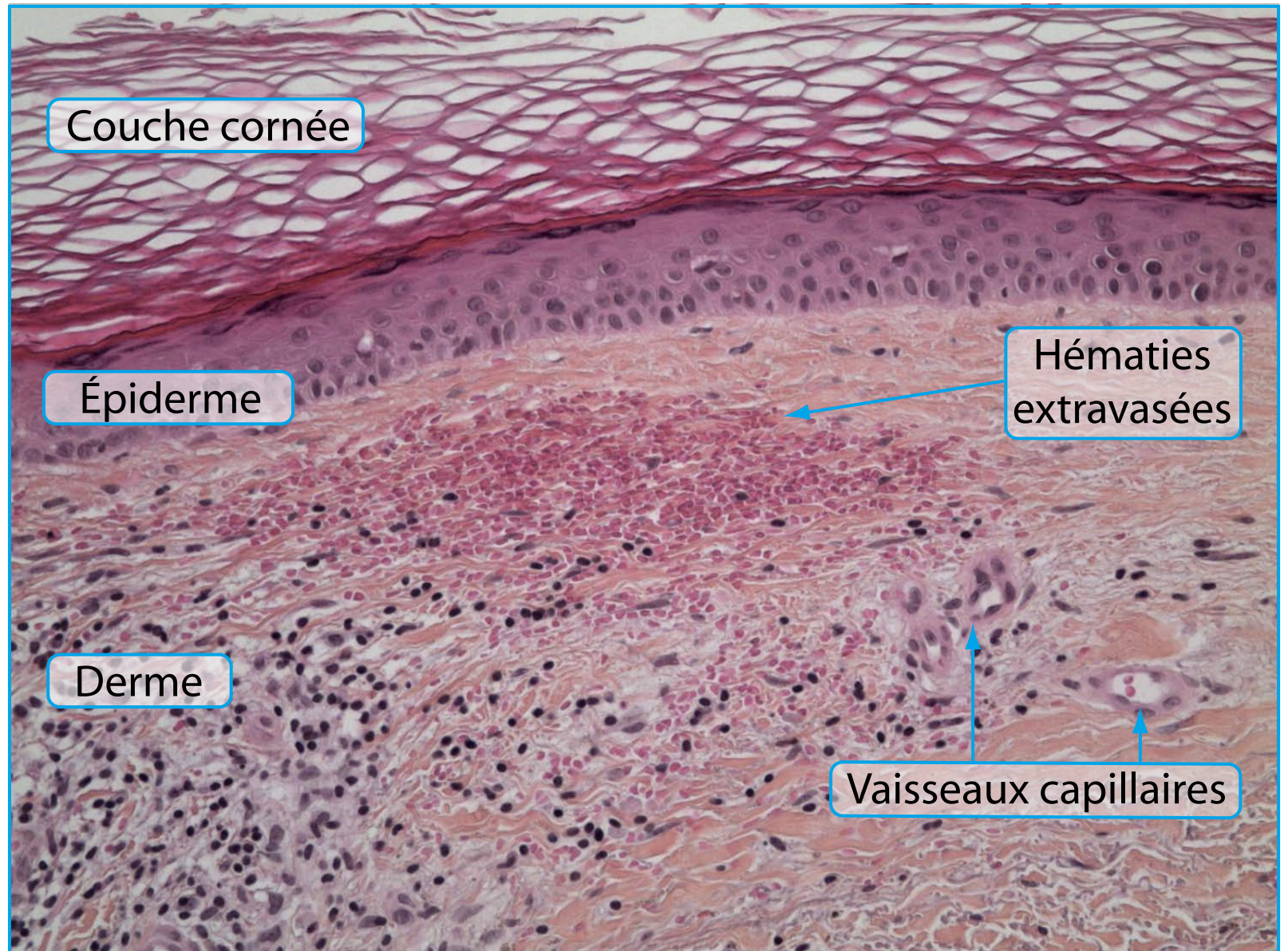
Érythème cyanotique



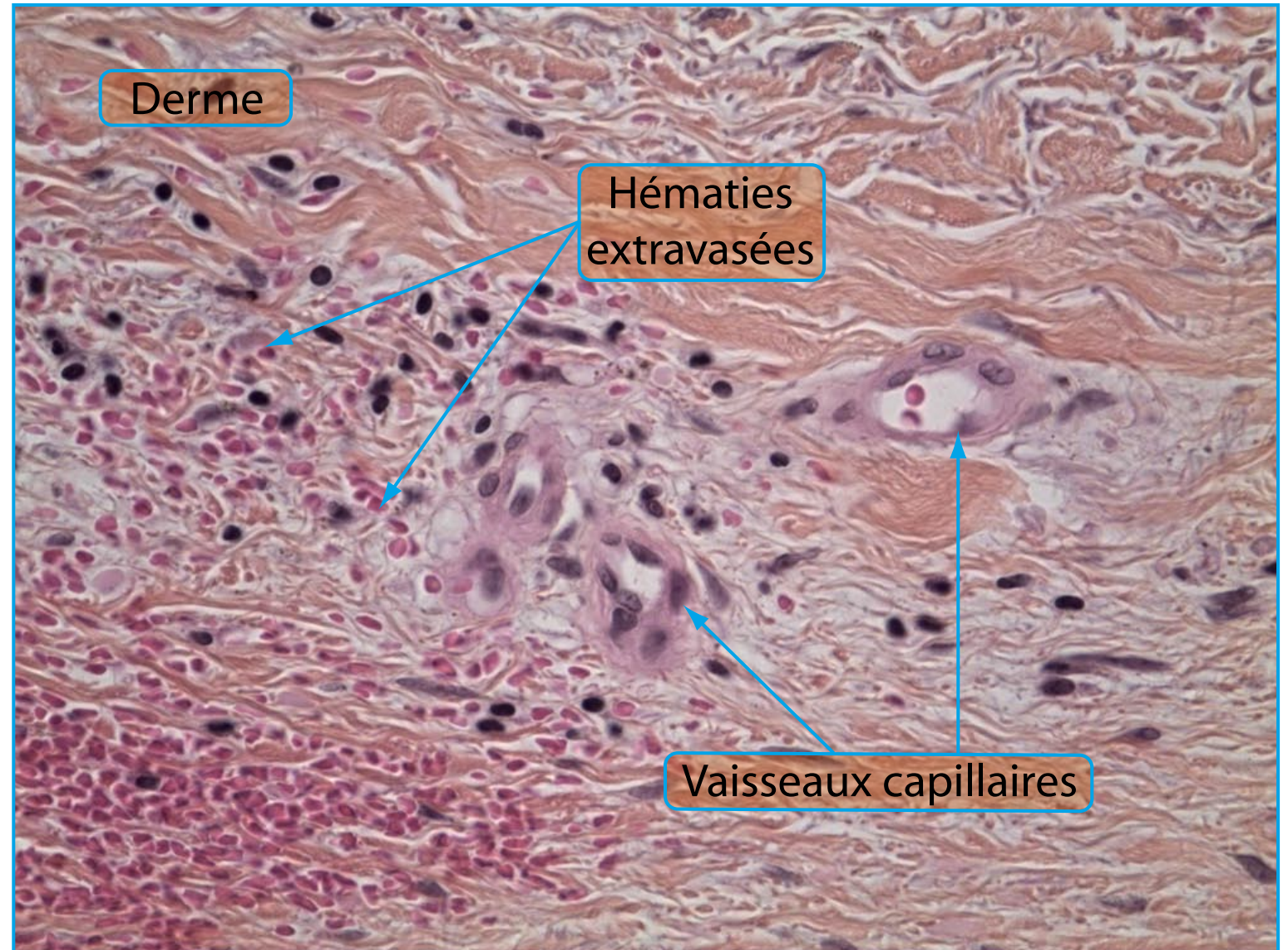
Macule purpurique



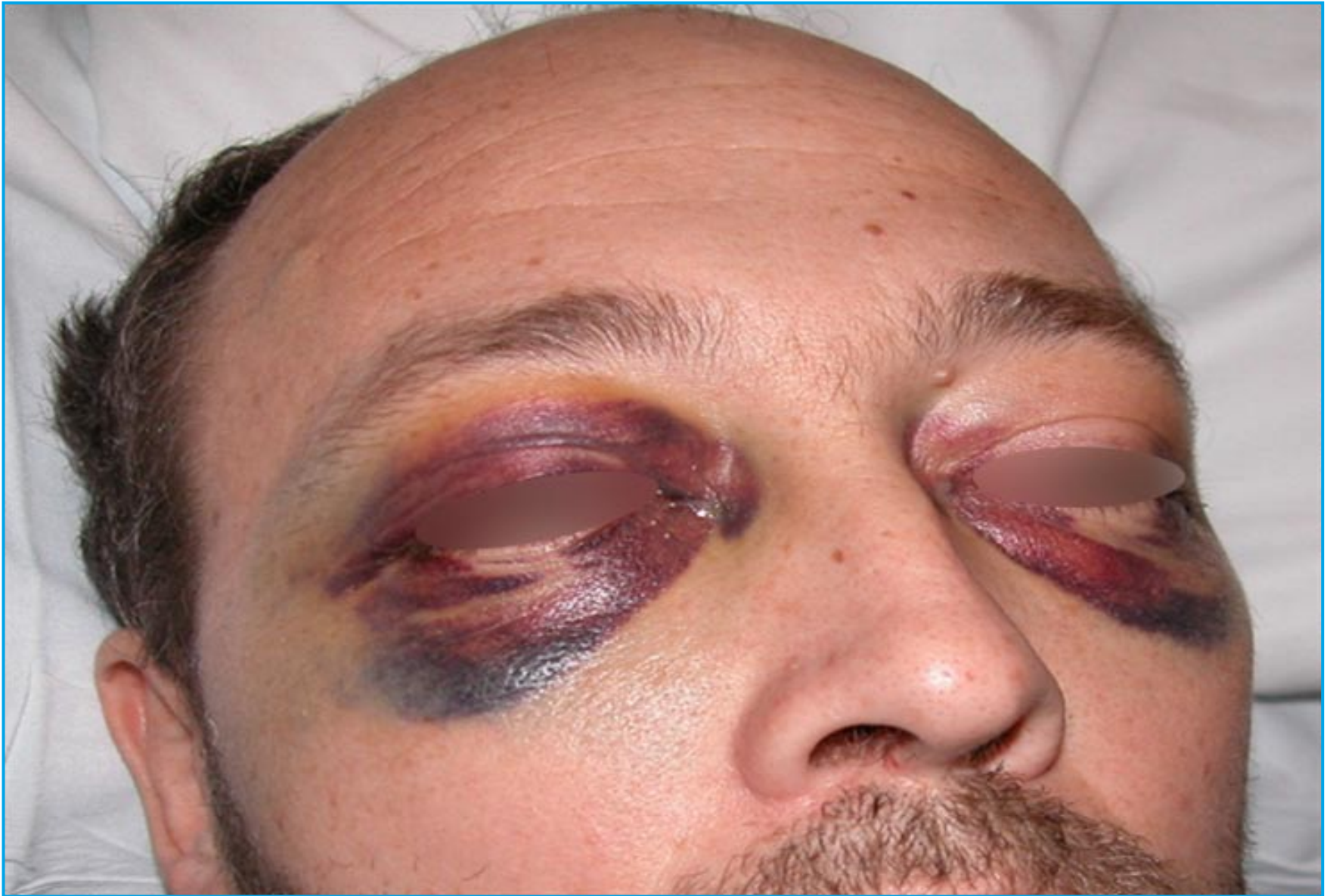Macule purpurique



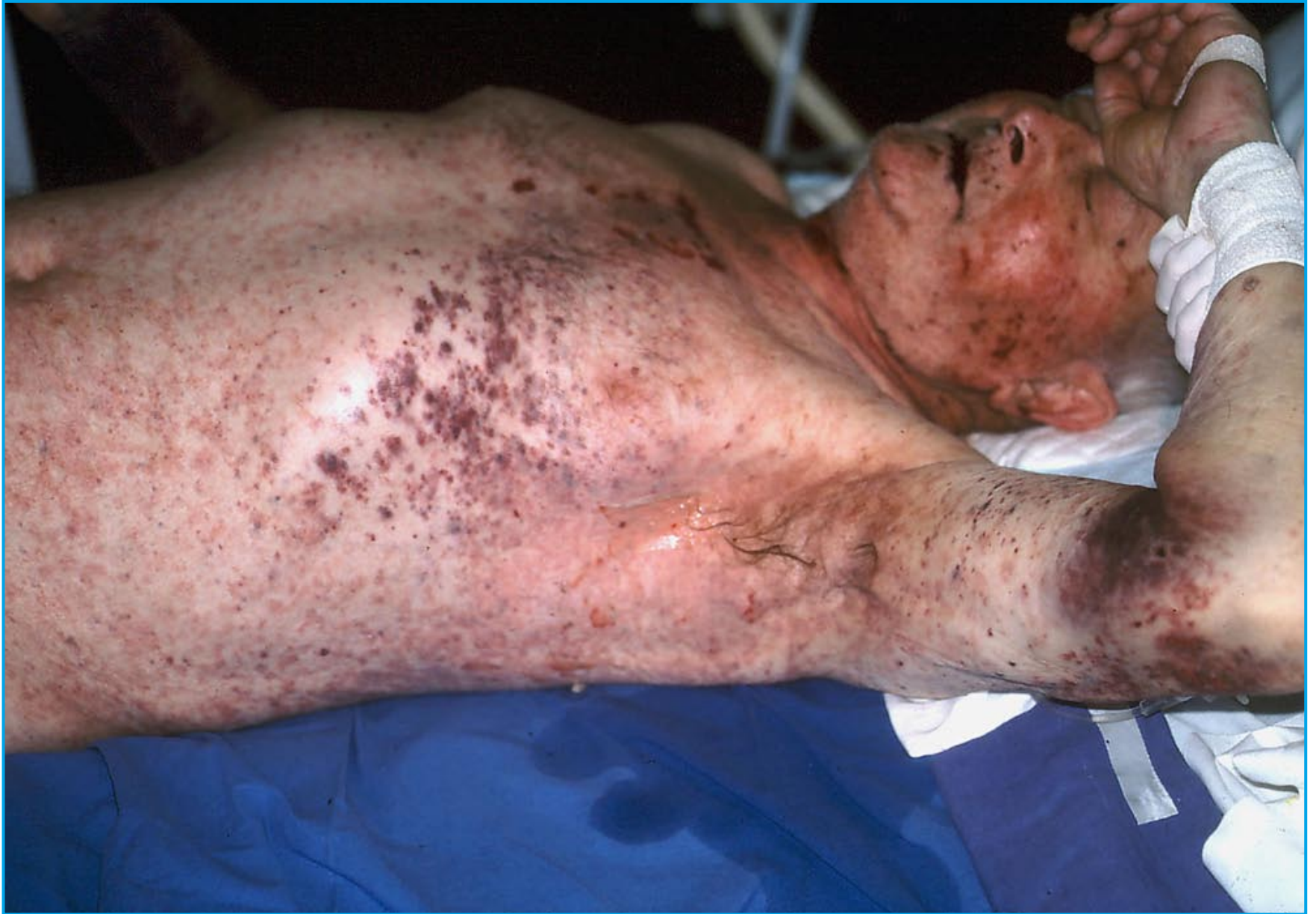Macule purpurique



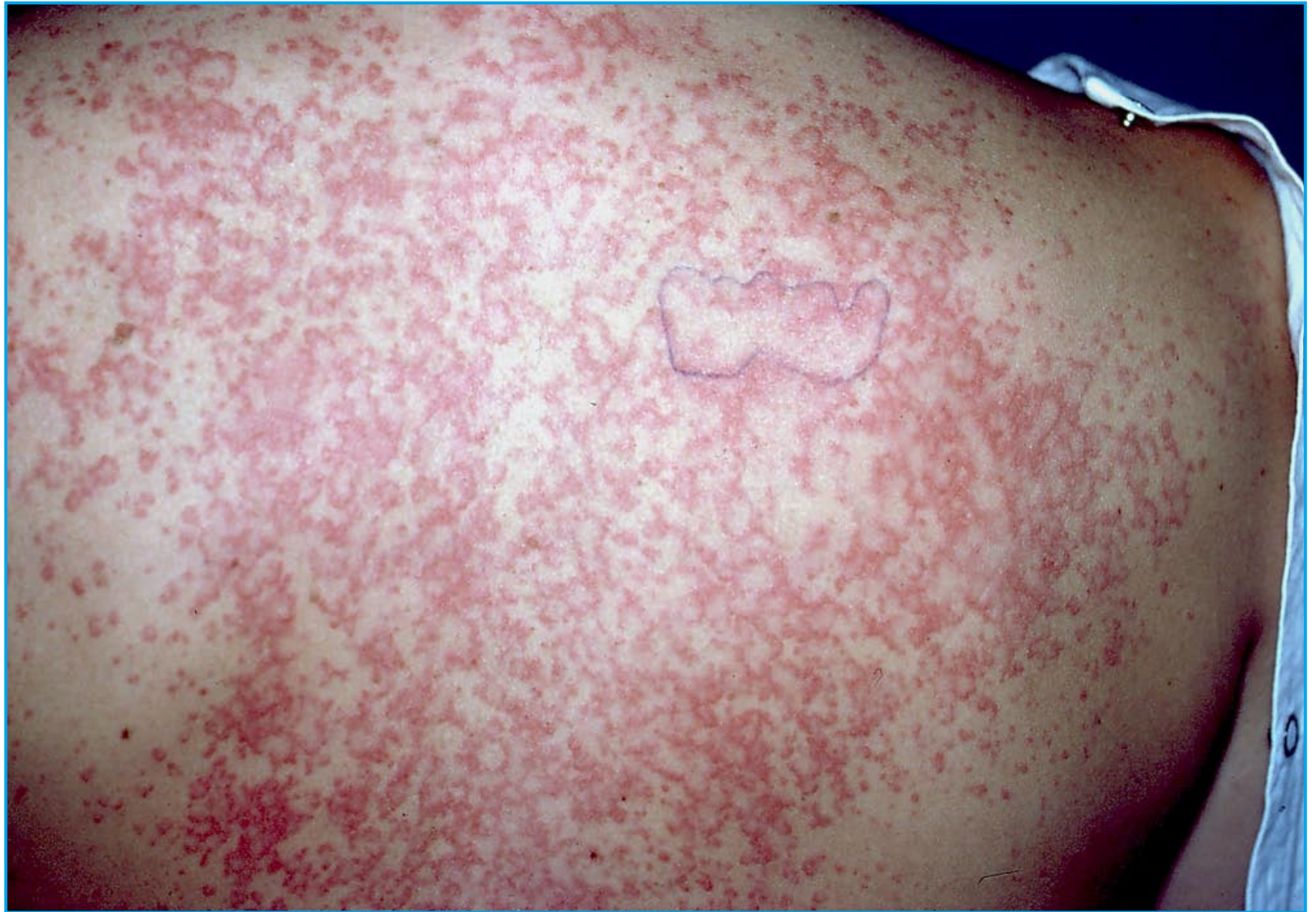Macule purpurique : ecchymose



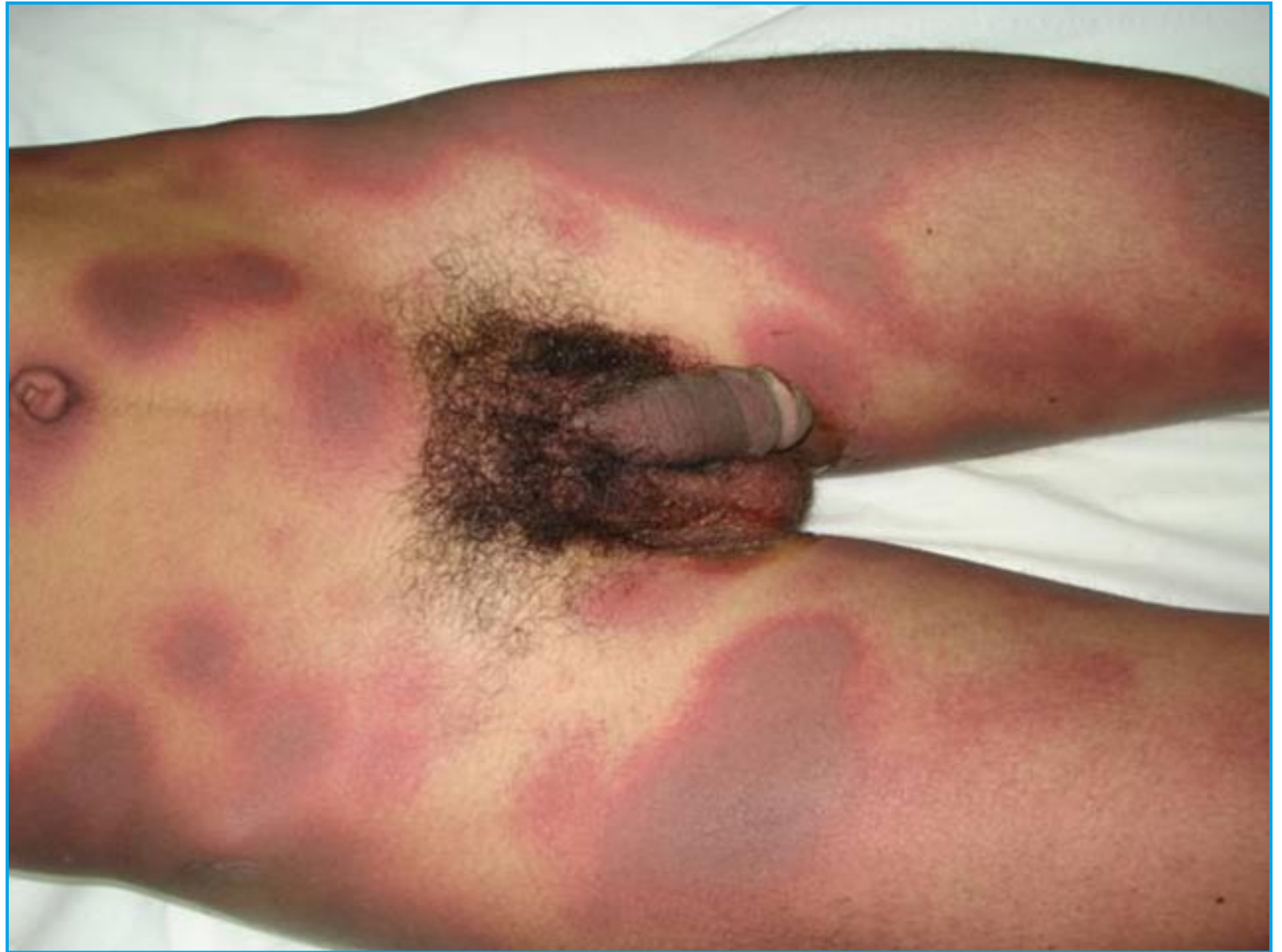Macules purpuriques : Pétéchies



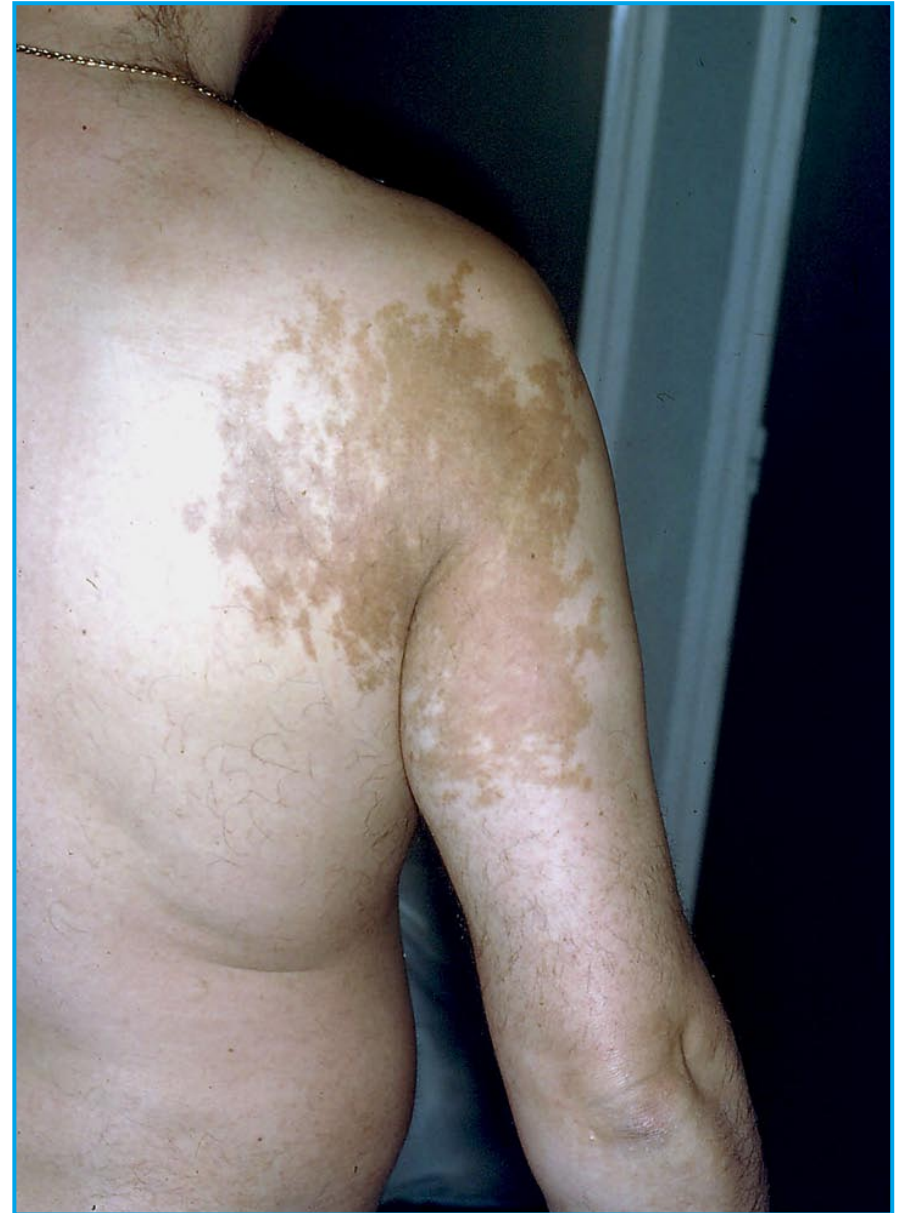Érythème vs purpura



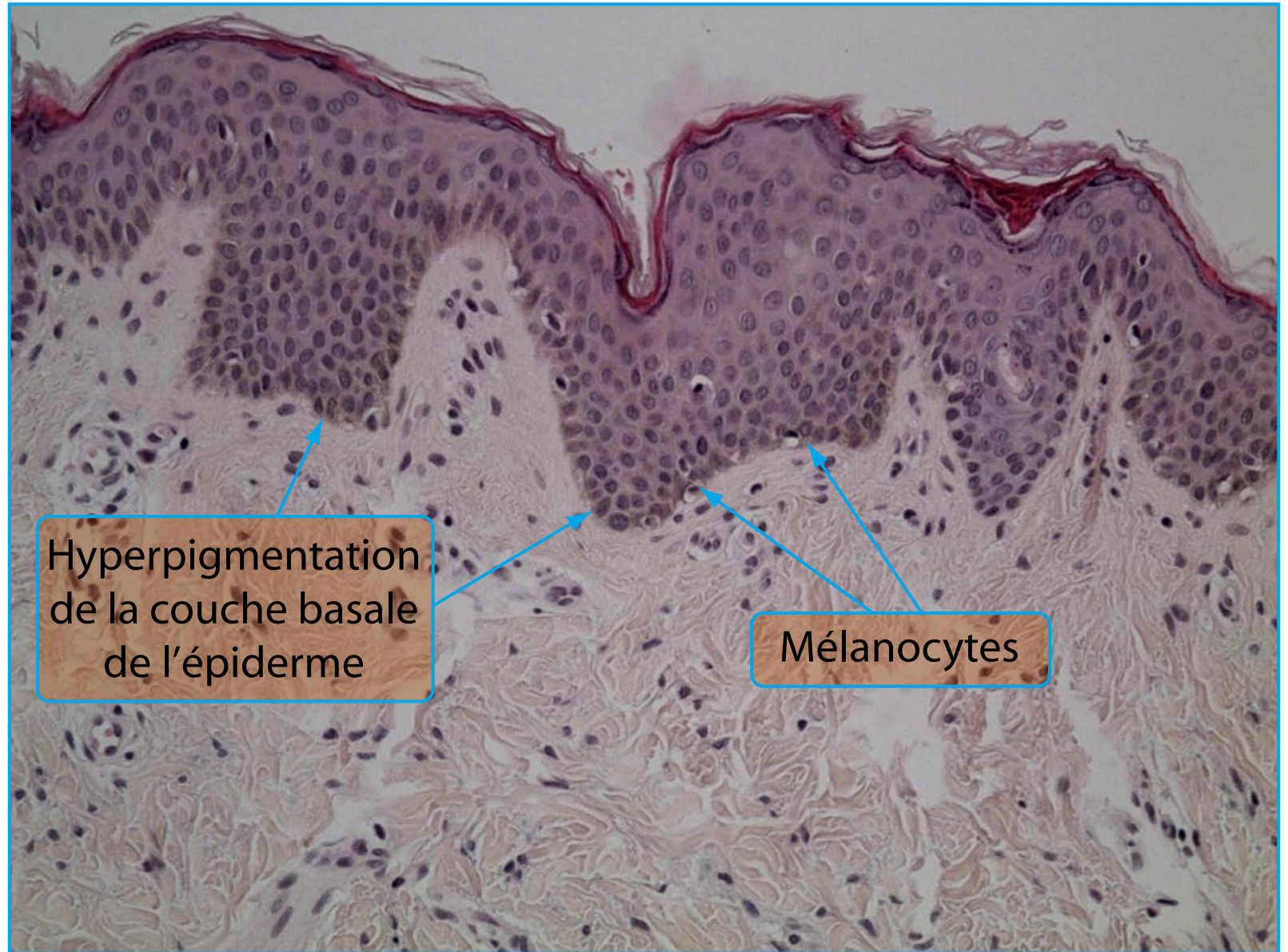
Érythème vs purpura



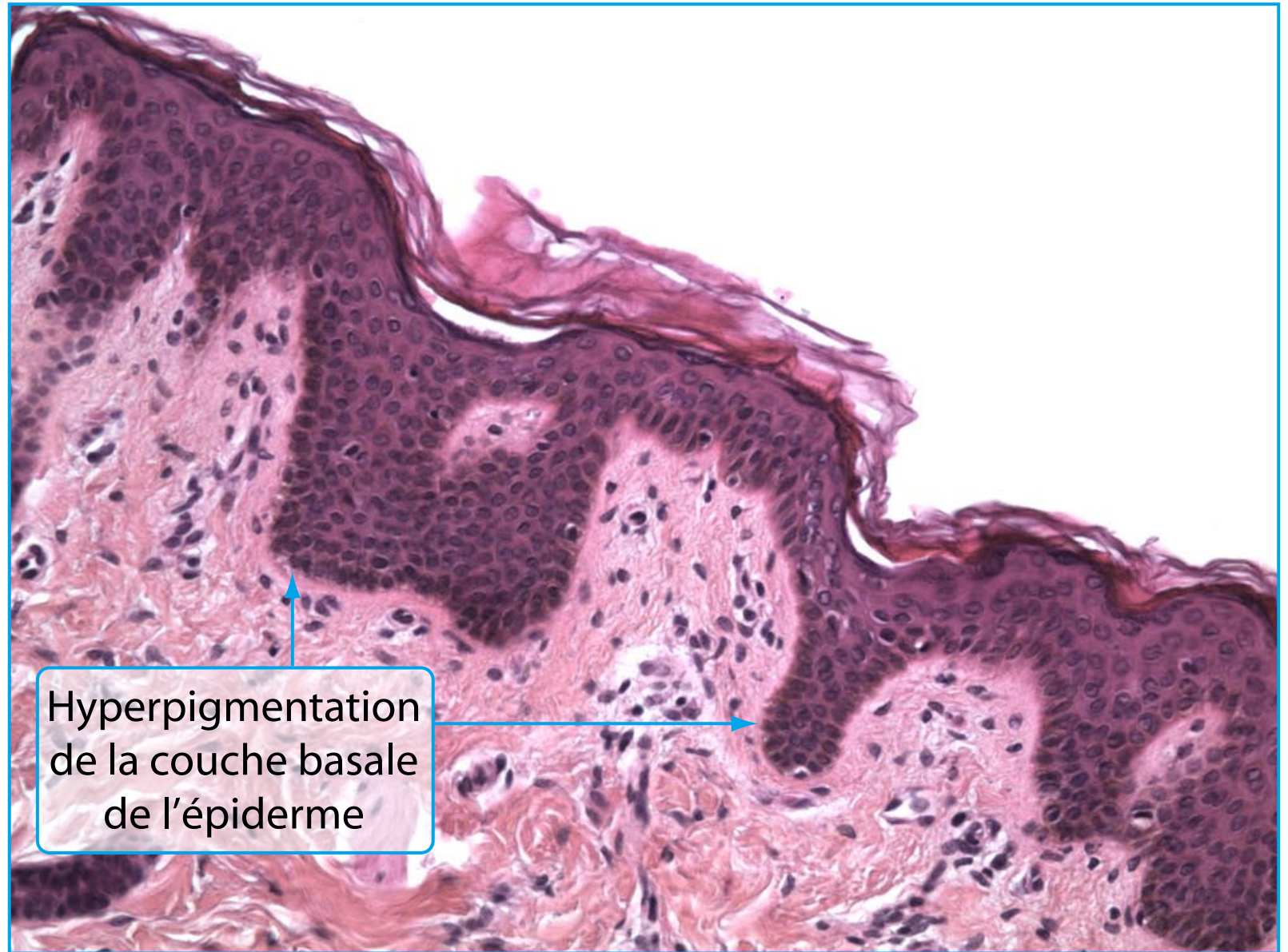
Macule pigmentée



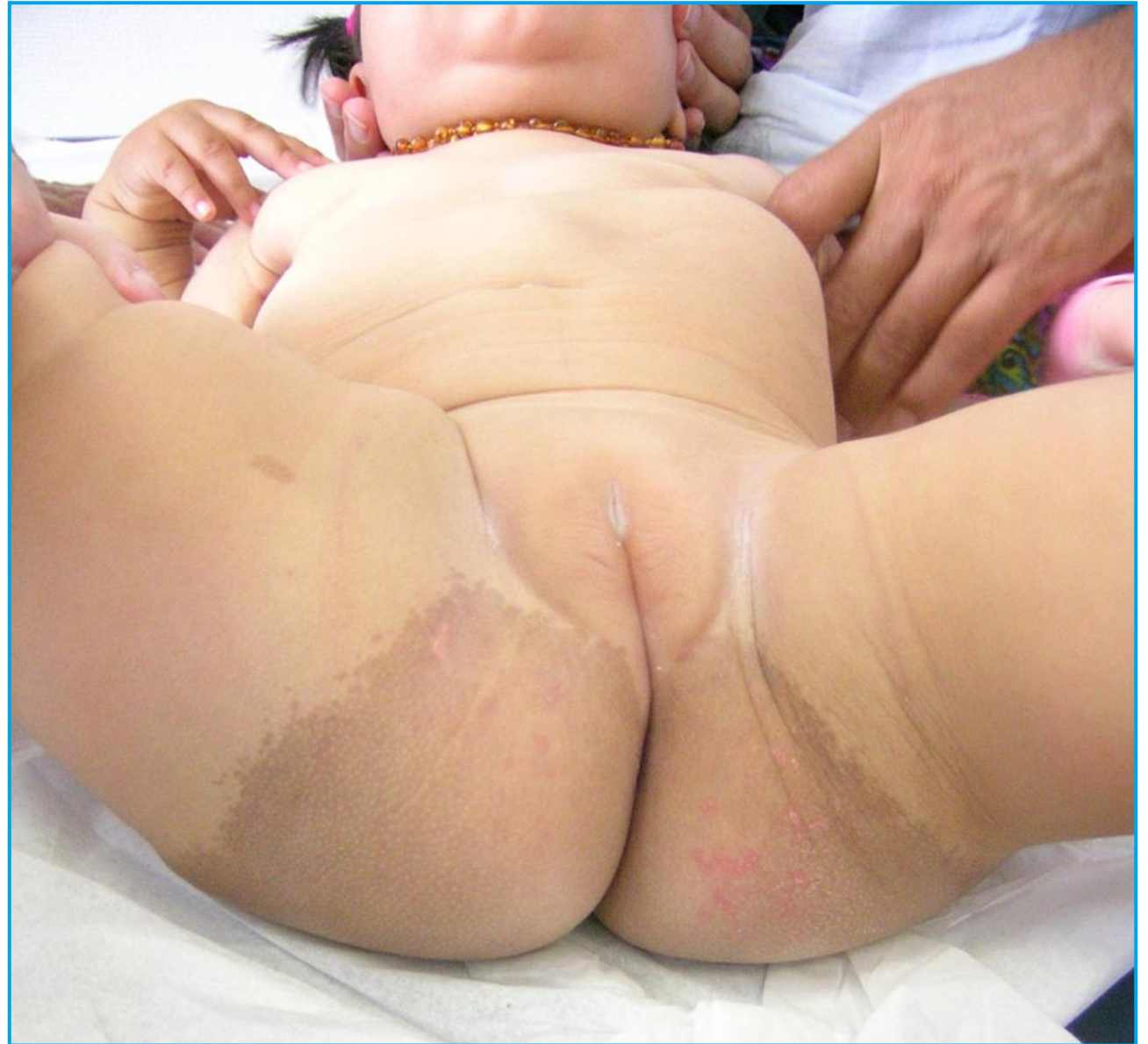Macule pigmentée



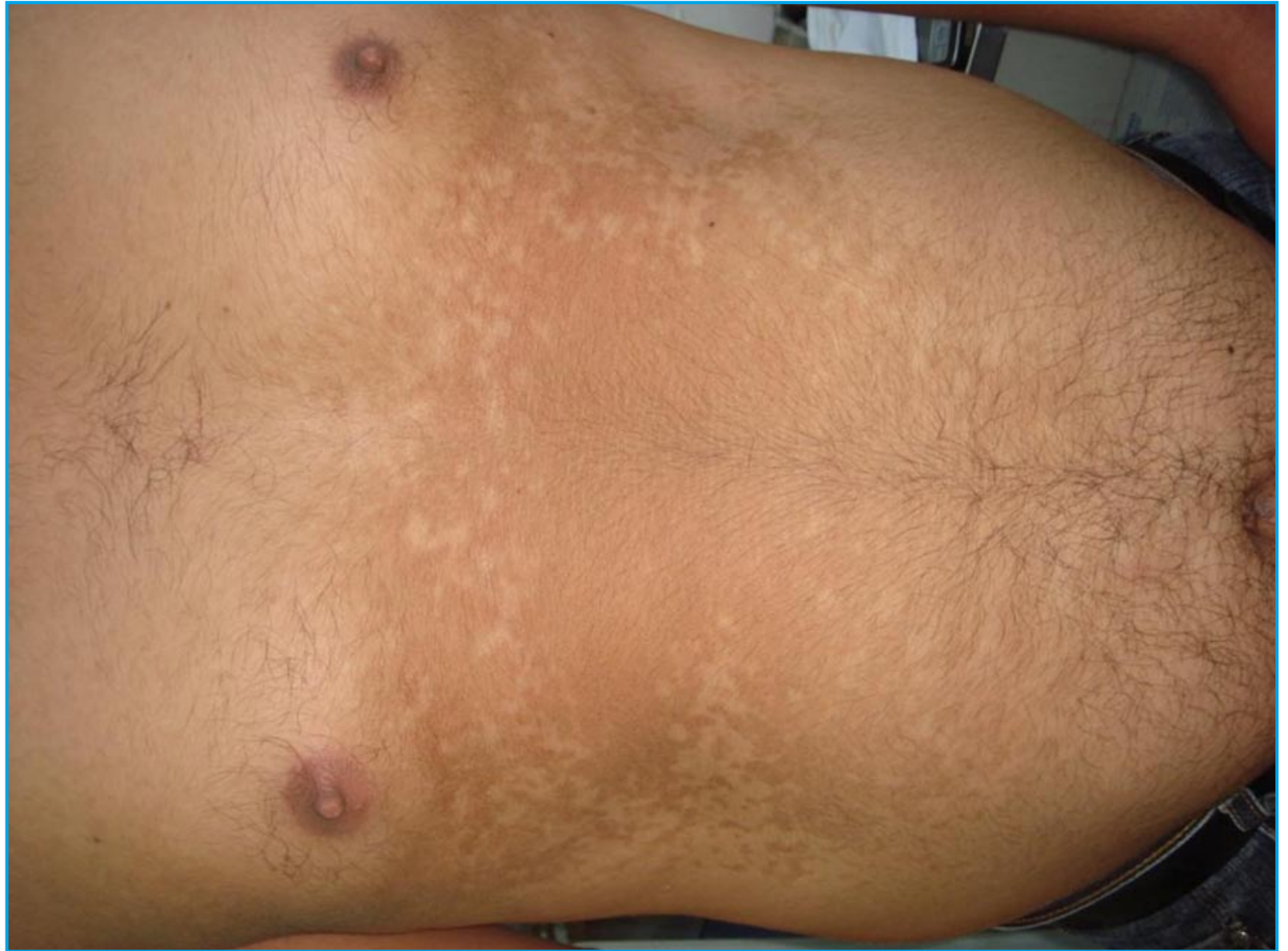Macule pigmentée



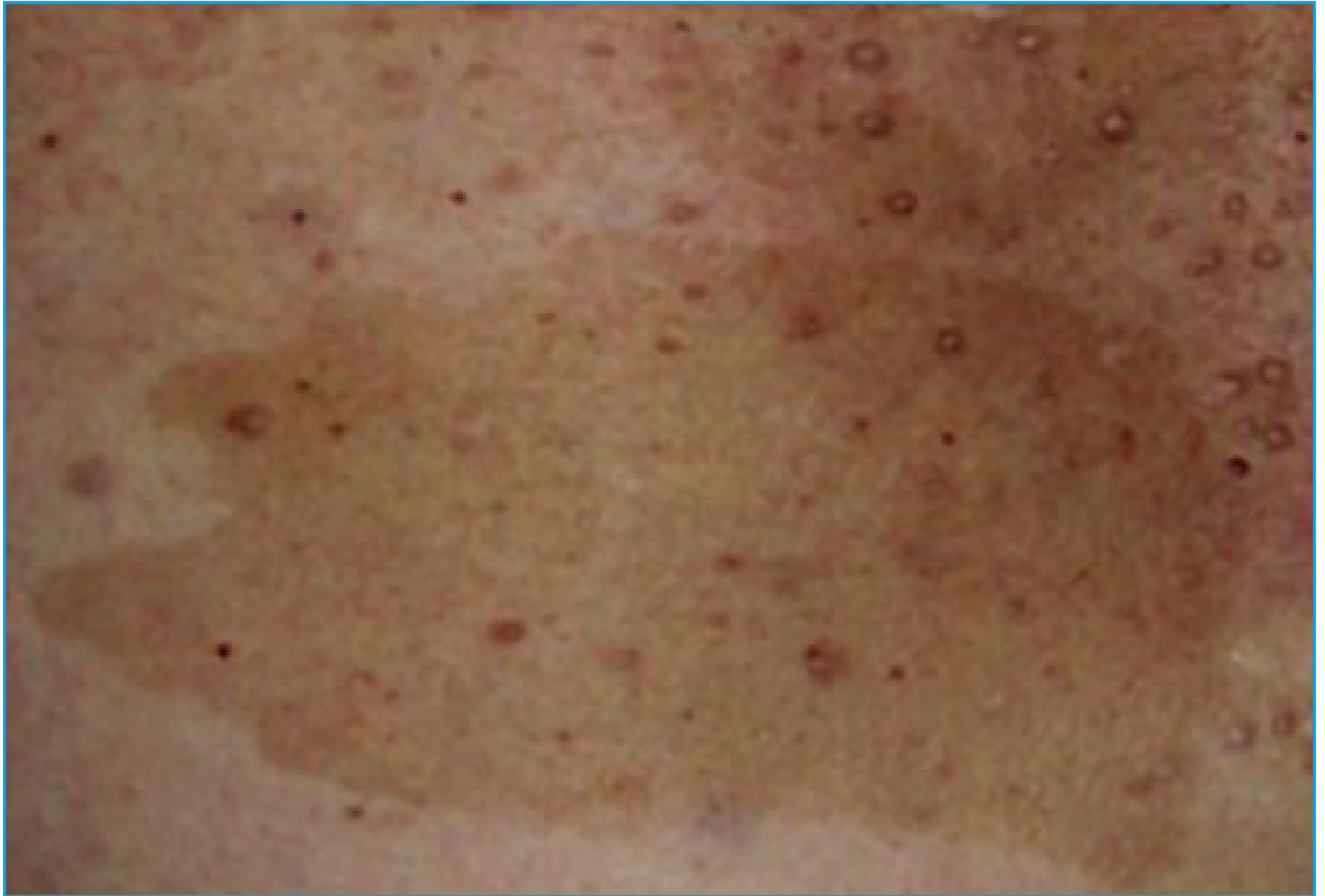Macule pigmentée



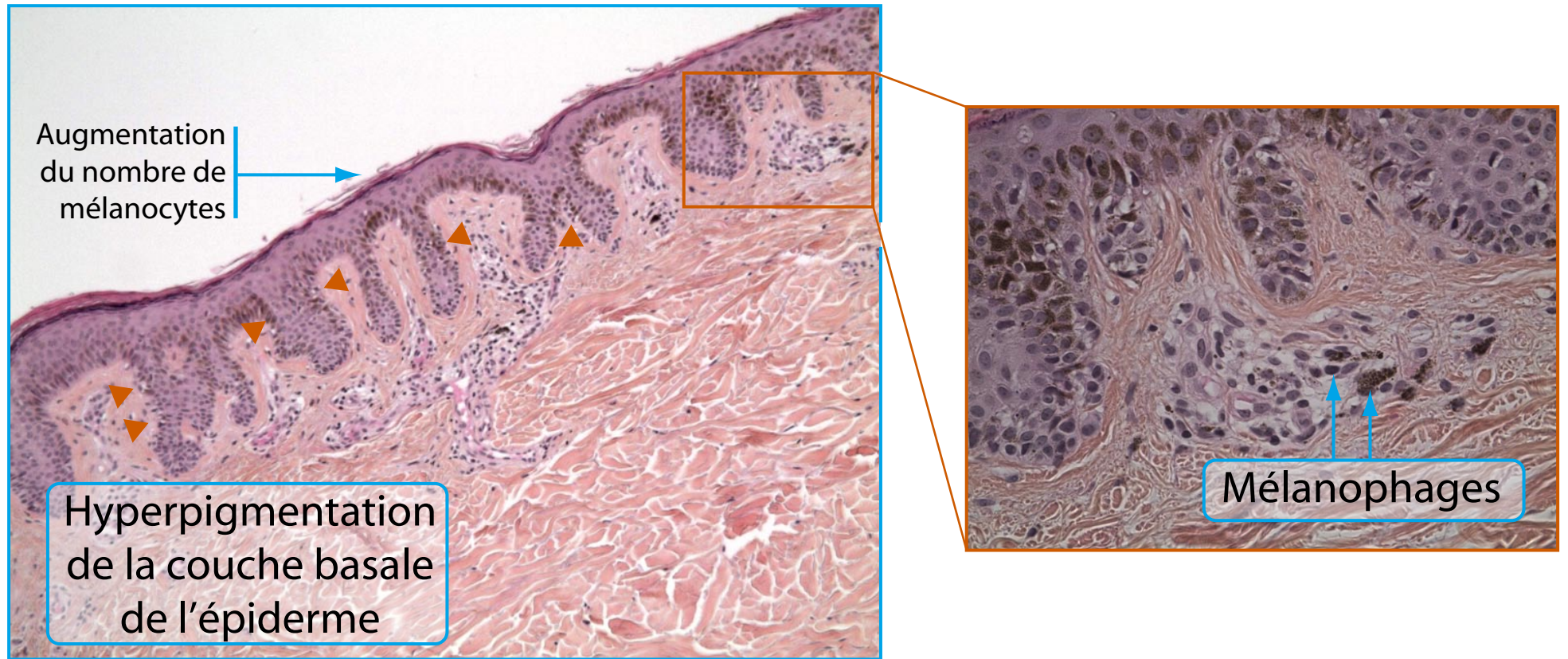
Macule pigmentée



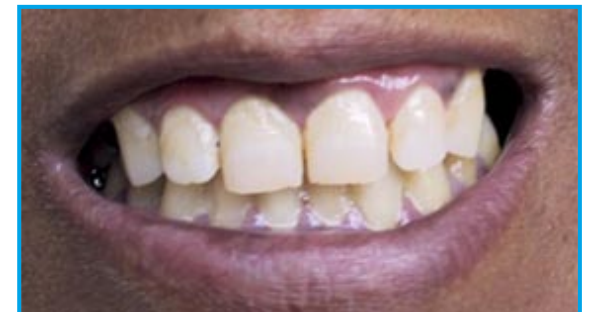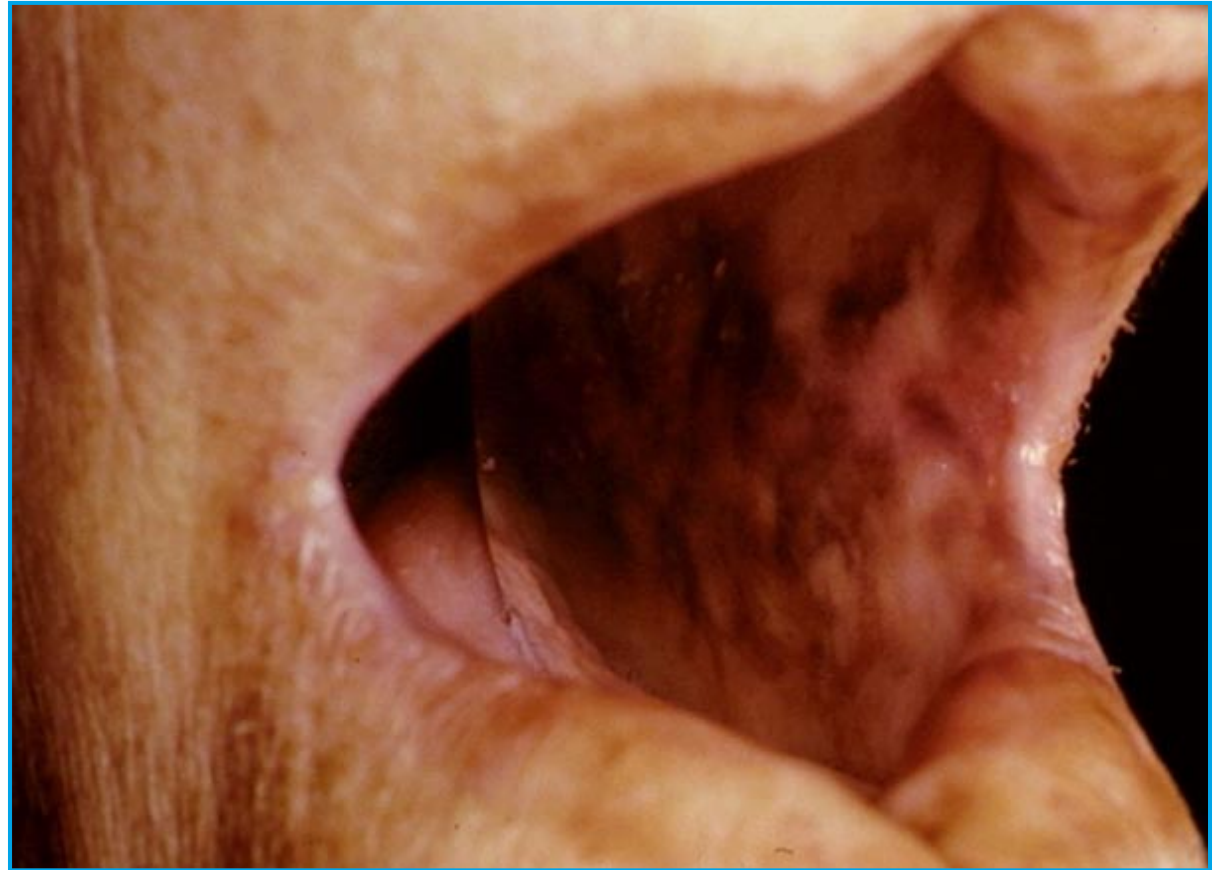
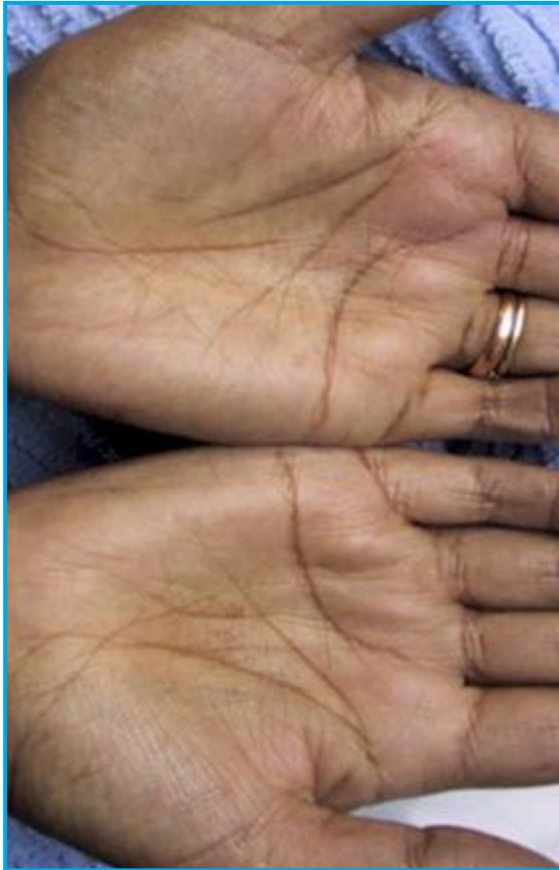Macule pigmentée



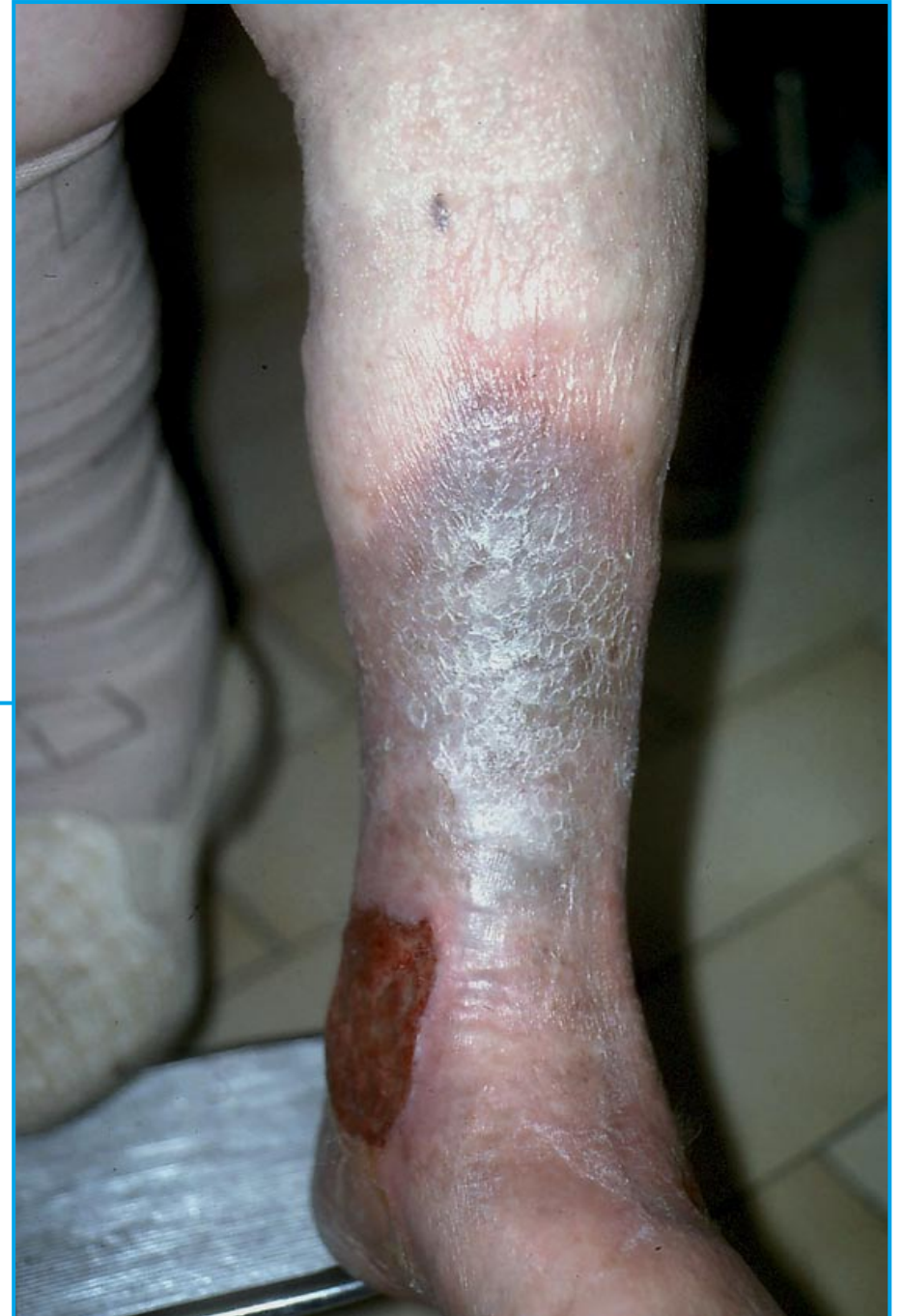Lentigo



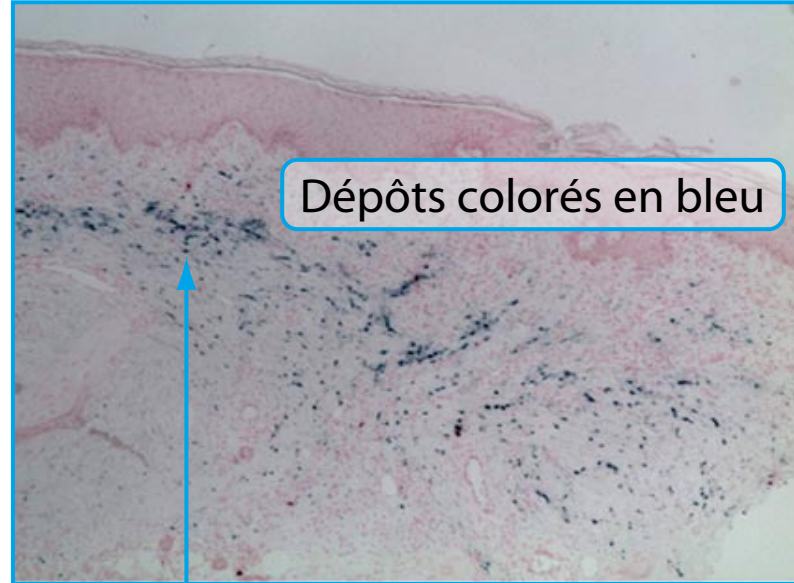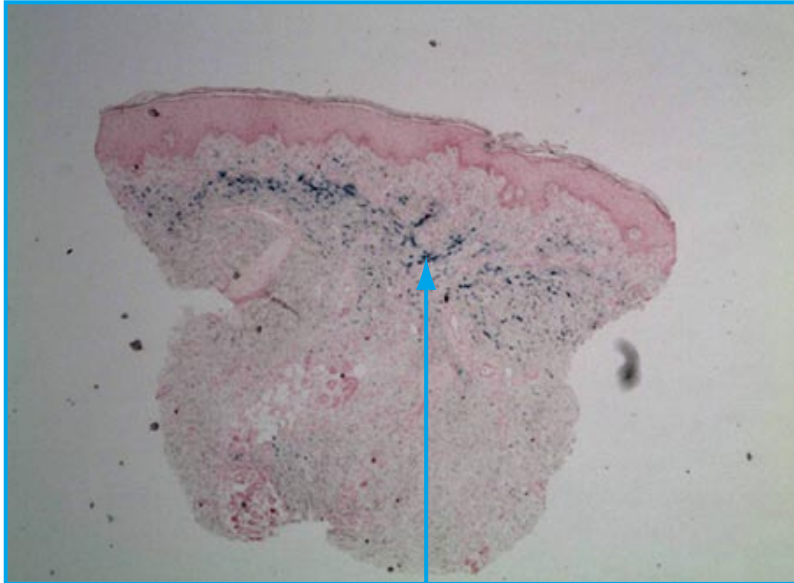
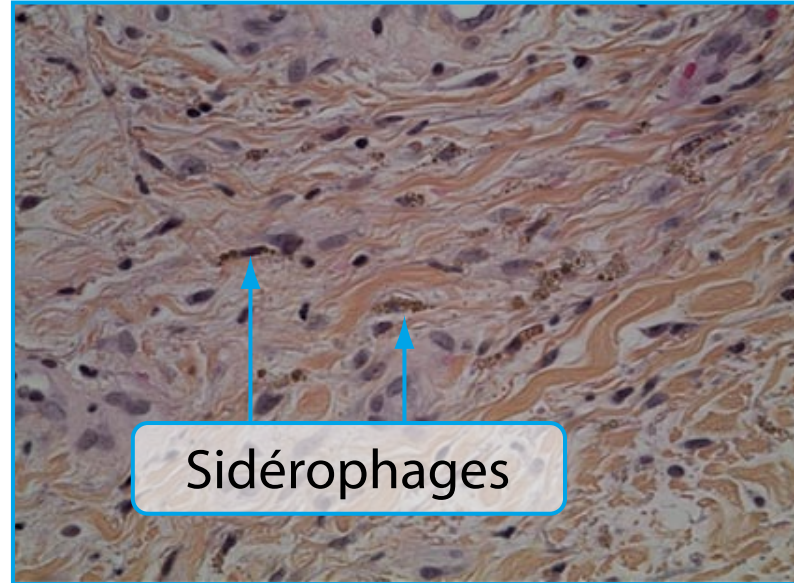
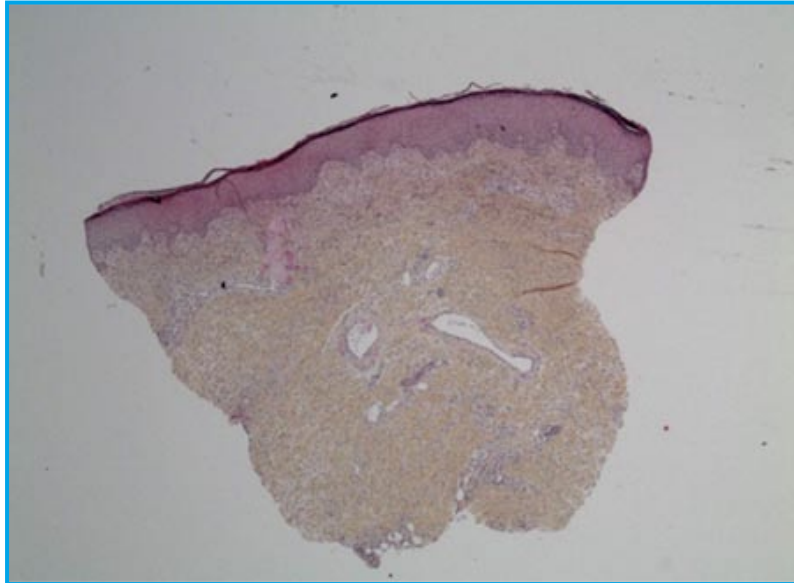
Macules pigmentées cutanées et muqueuses



**Macule
pigmentée
dépôts ferriques**

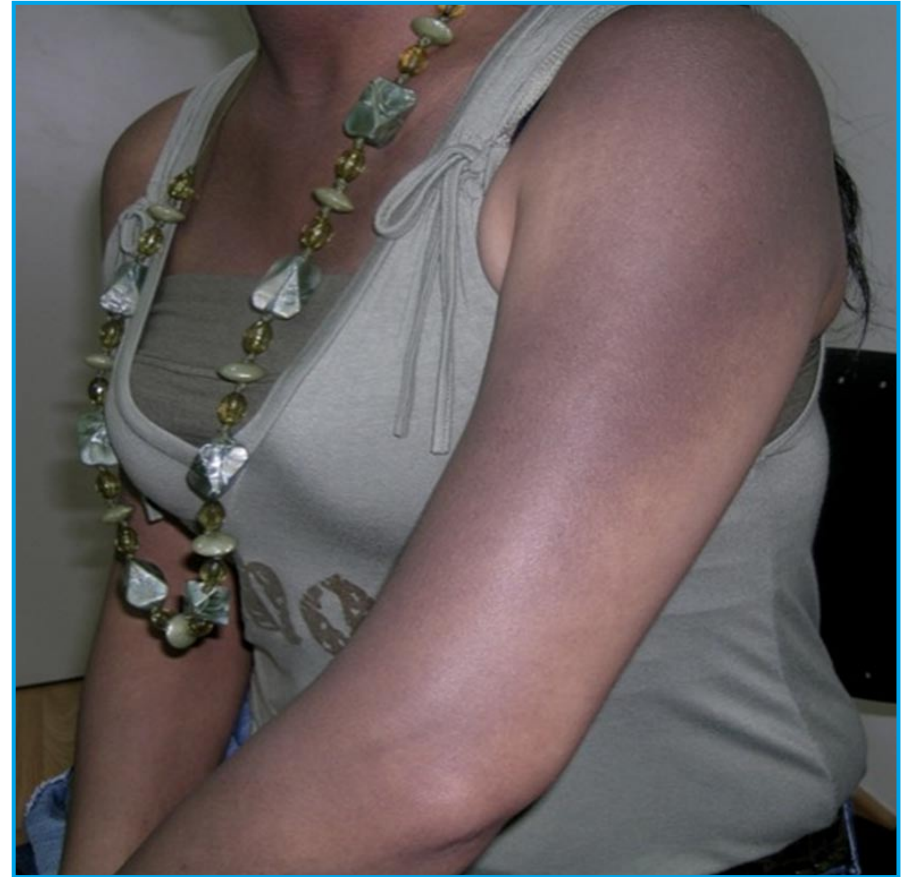
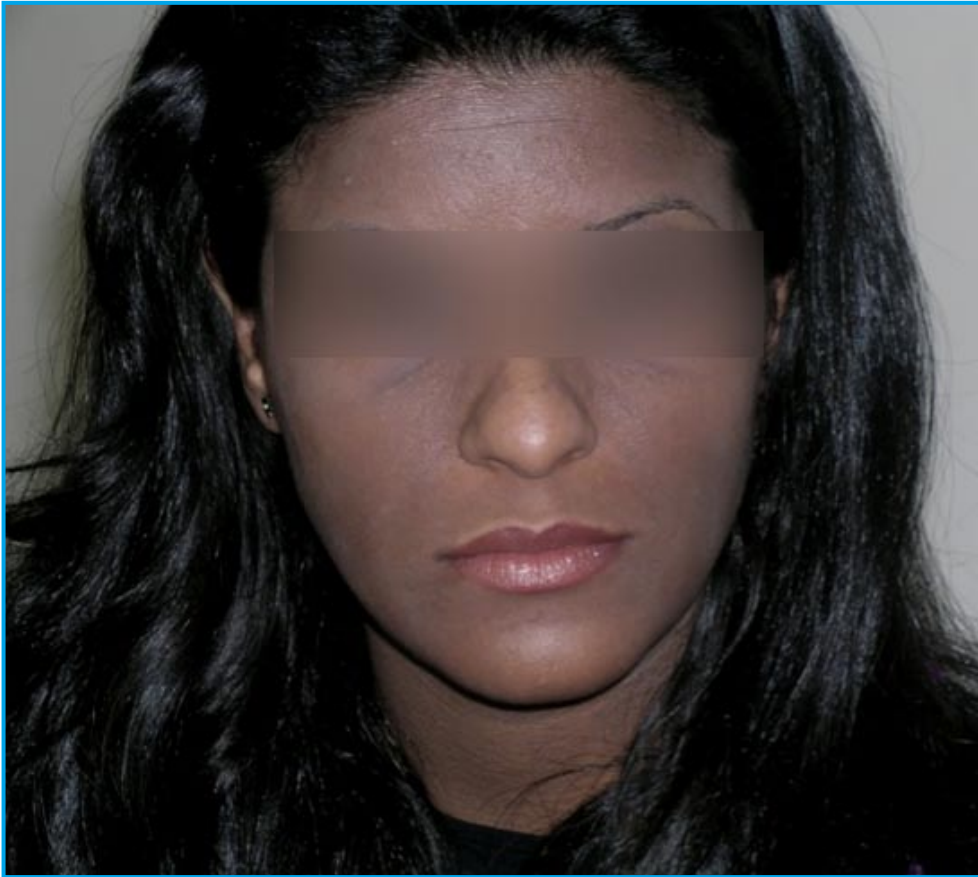
Macules pigmentées dépôts ferriques

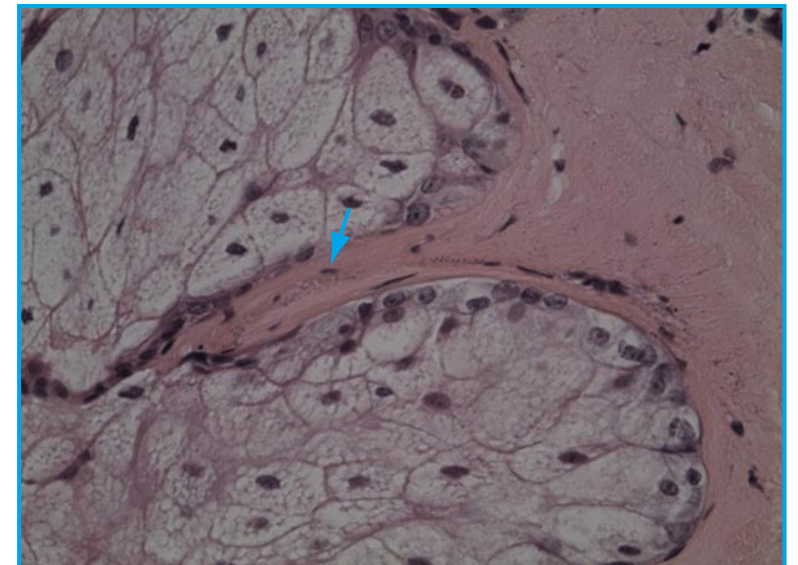
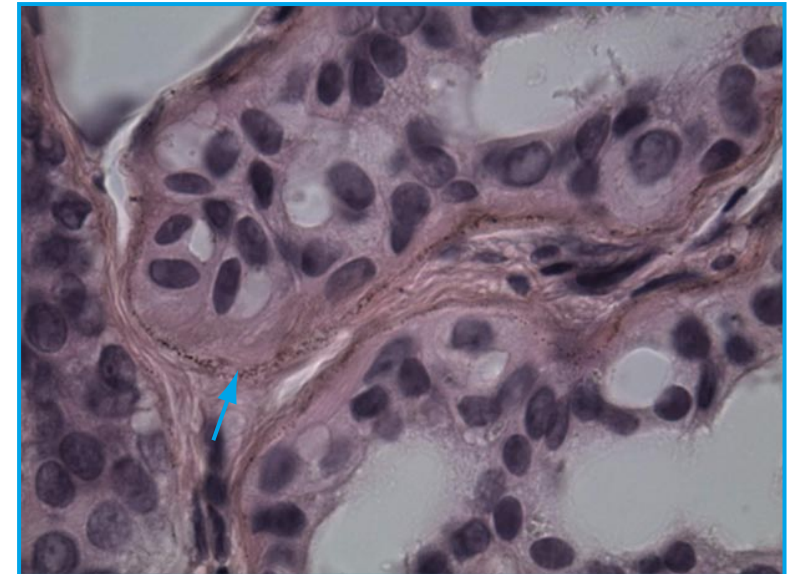
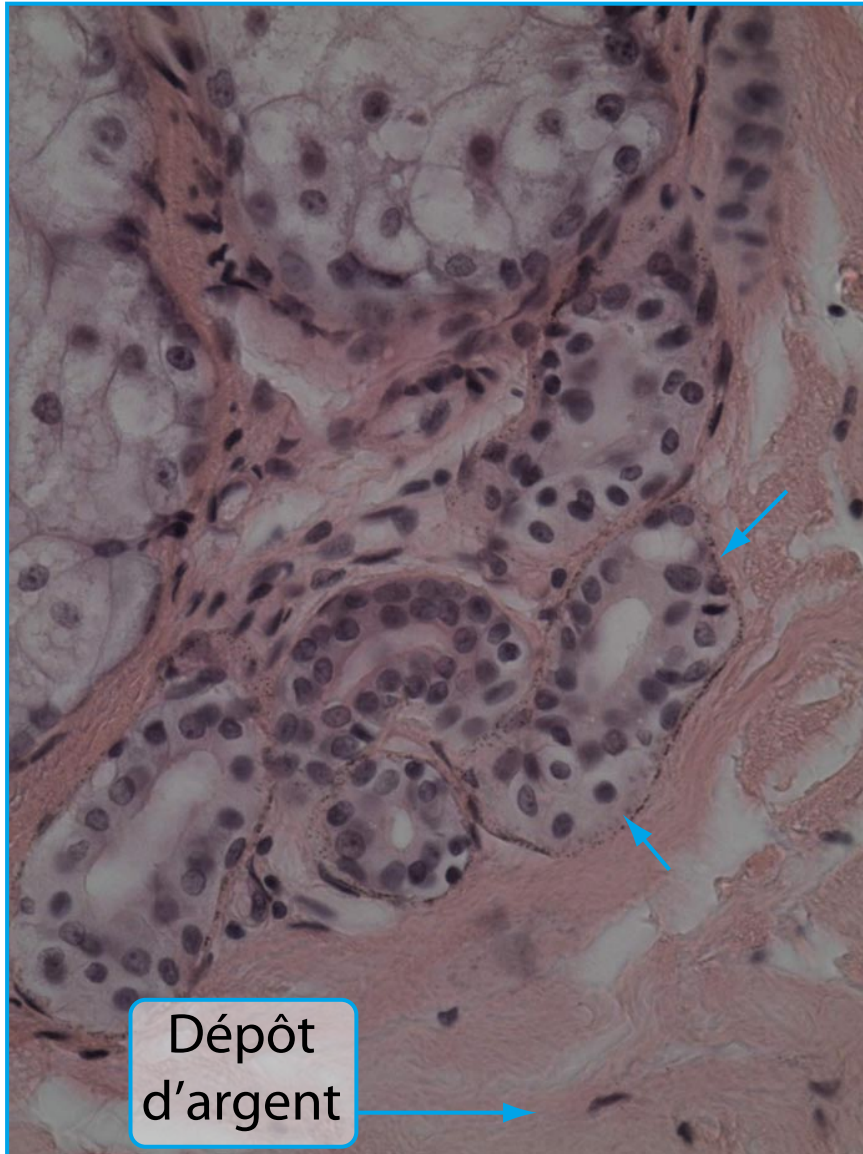


Mise en évidence des dépôts d'hemosidérine (fer) par la coloration de Perls

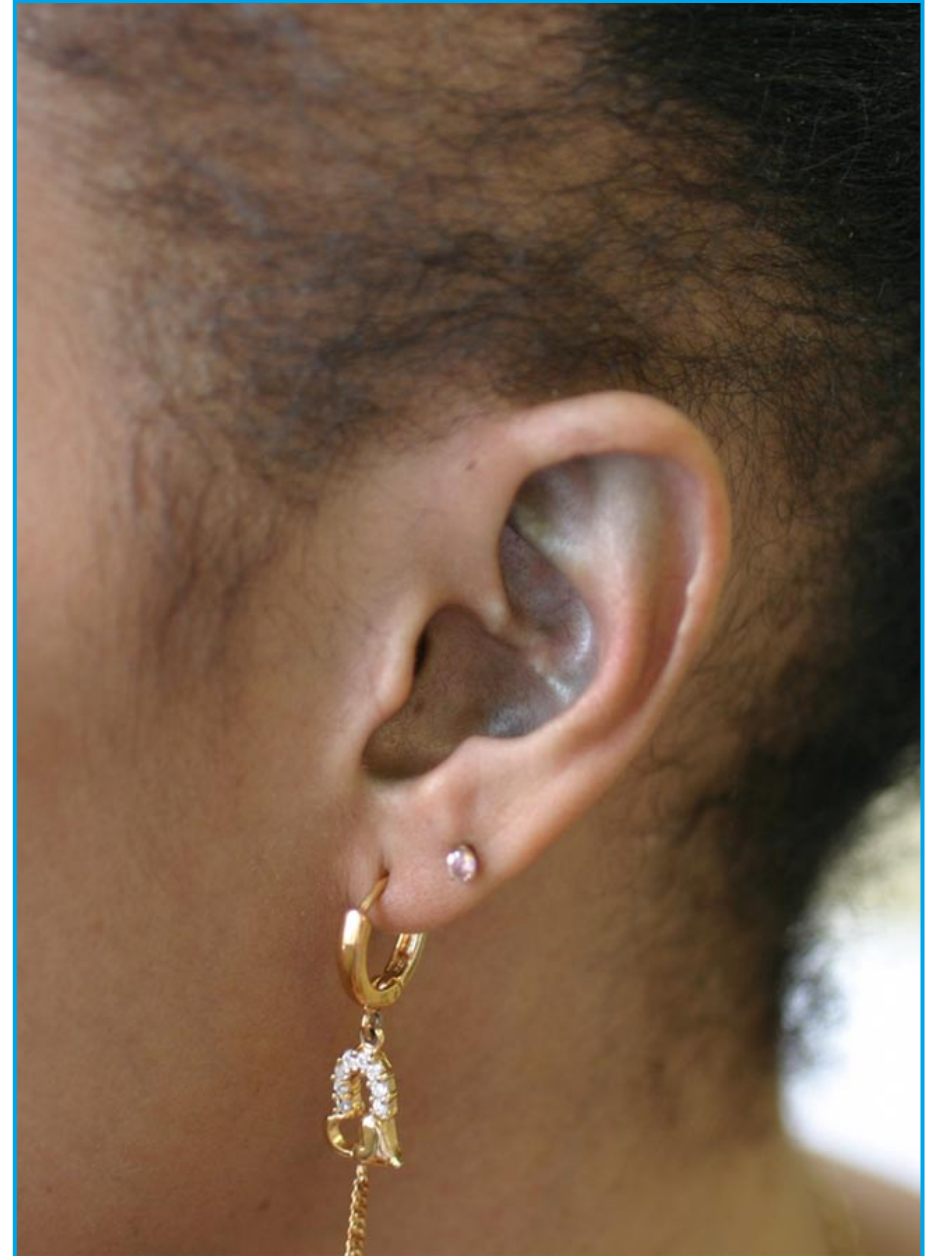
Macule pigmentée dépôts métalliques



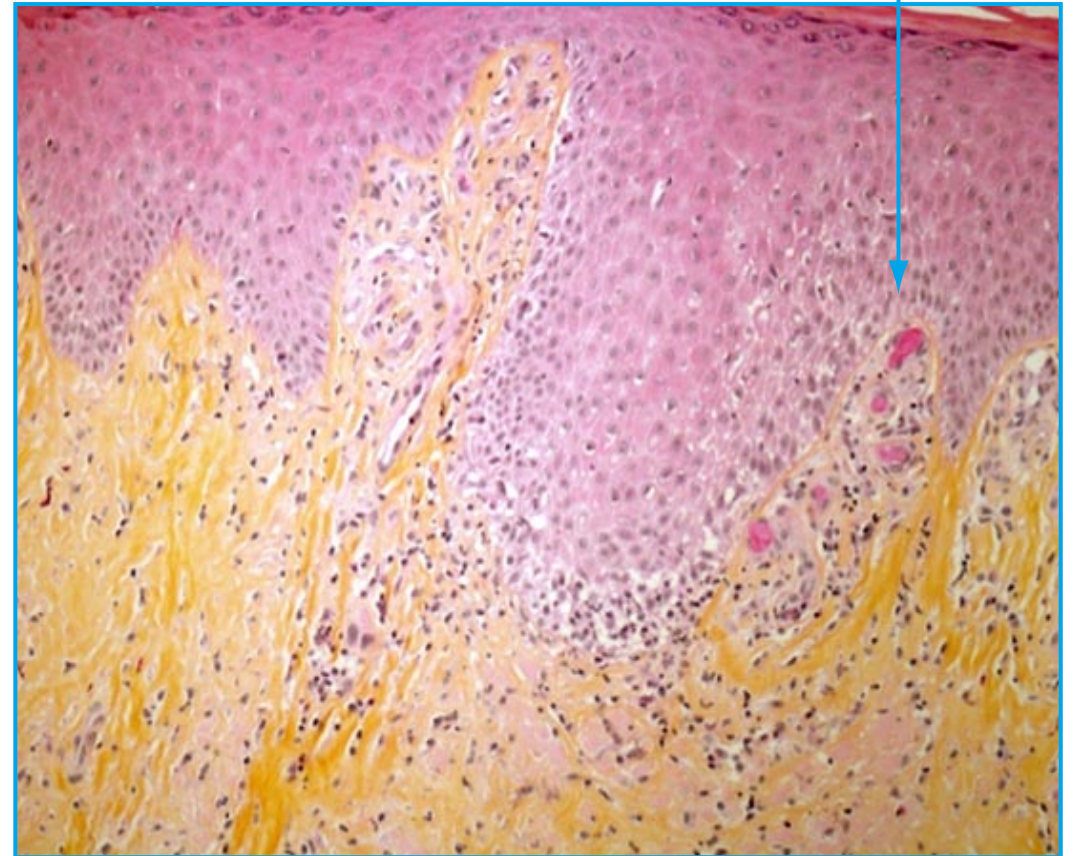
Argyrie



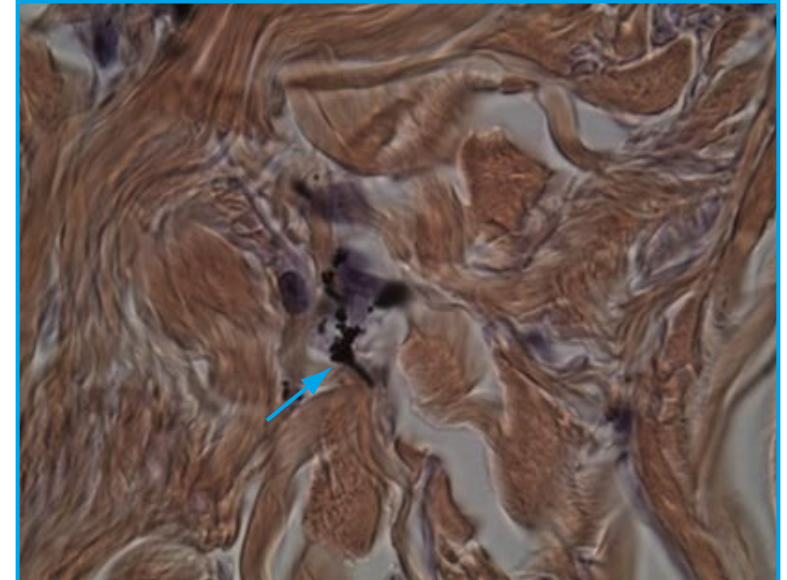
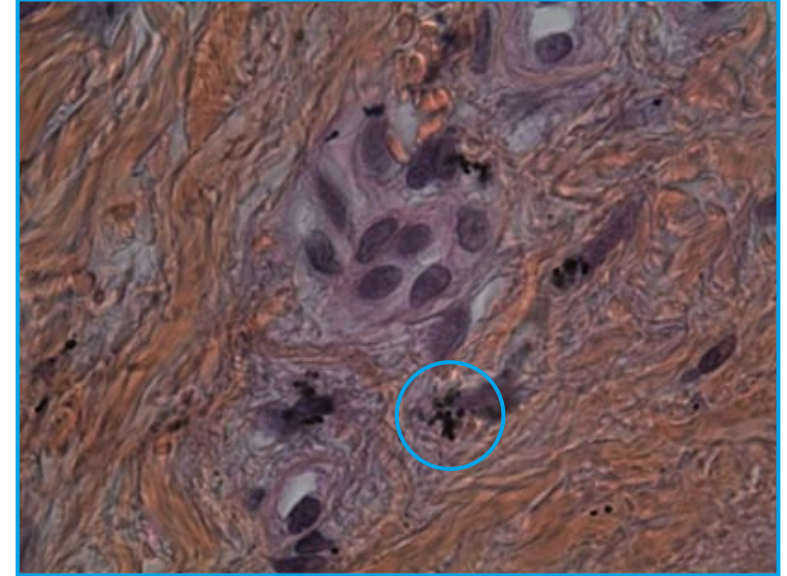
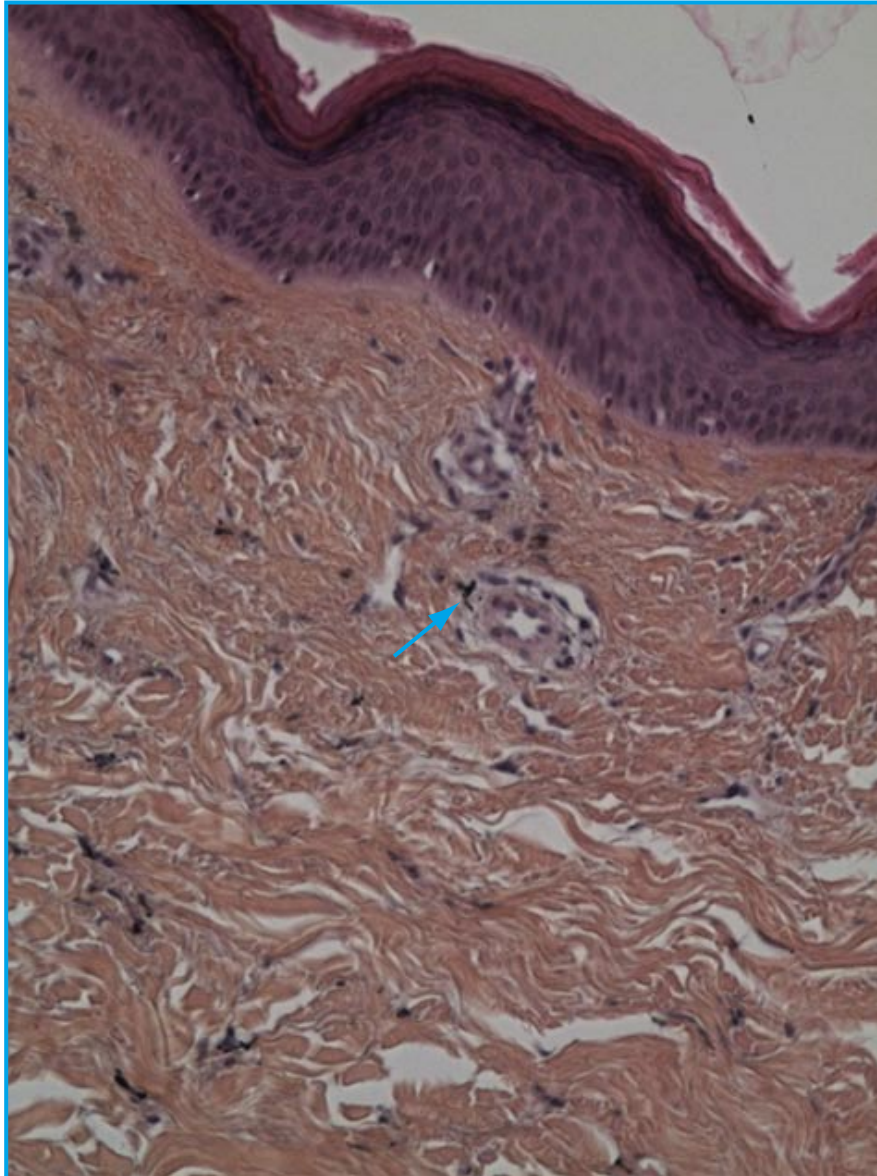
Macule pigmentée



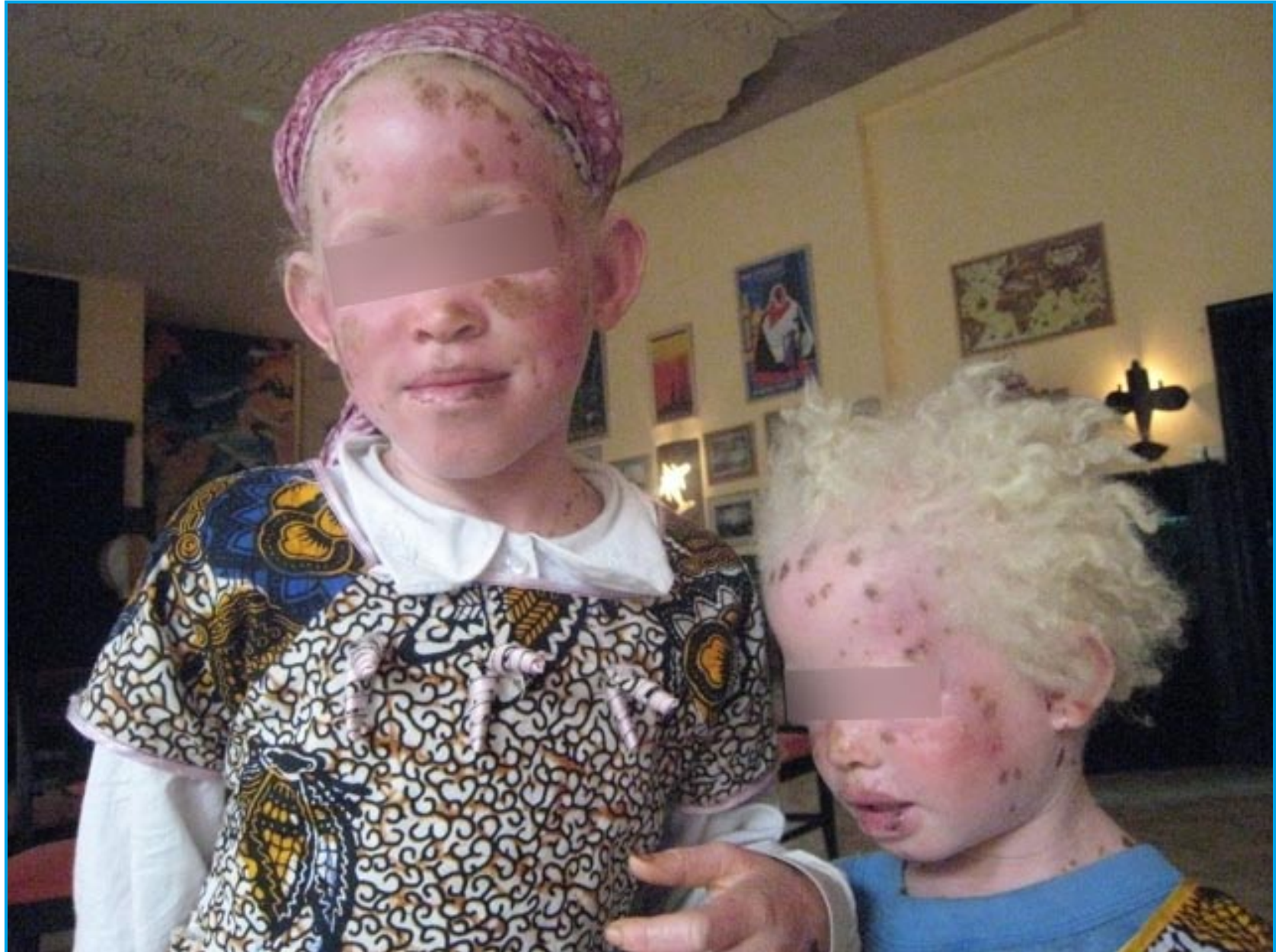Macule pigmentée dépôts exogènes



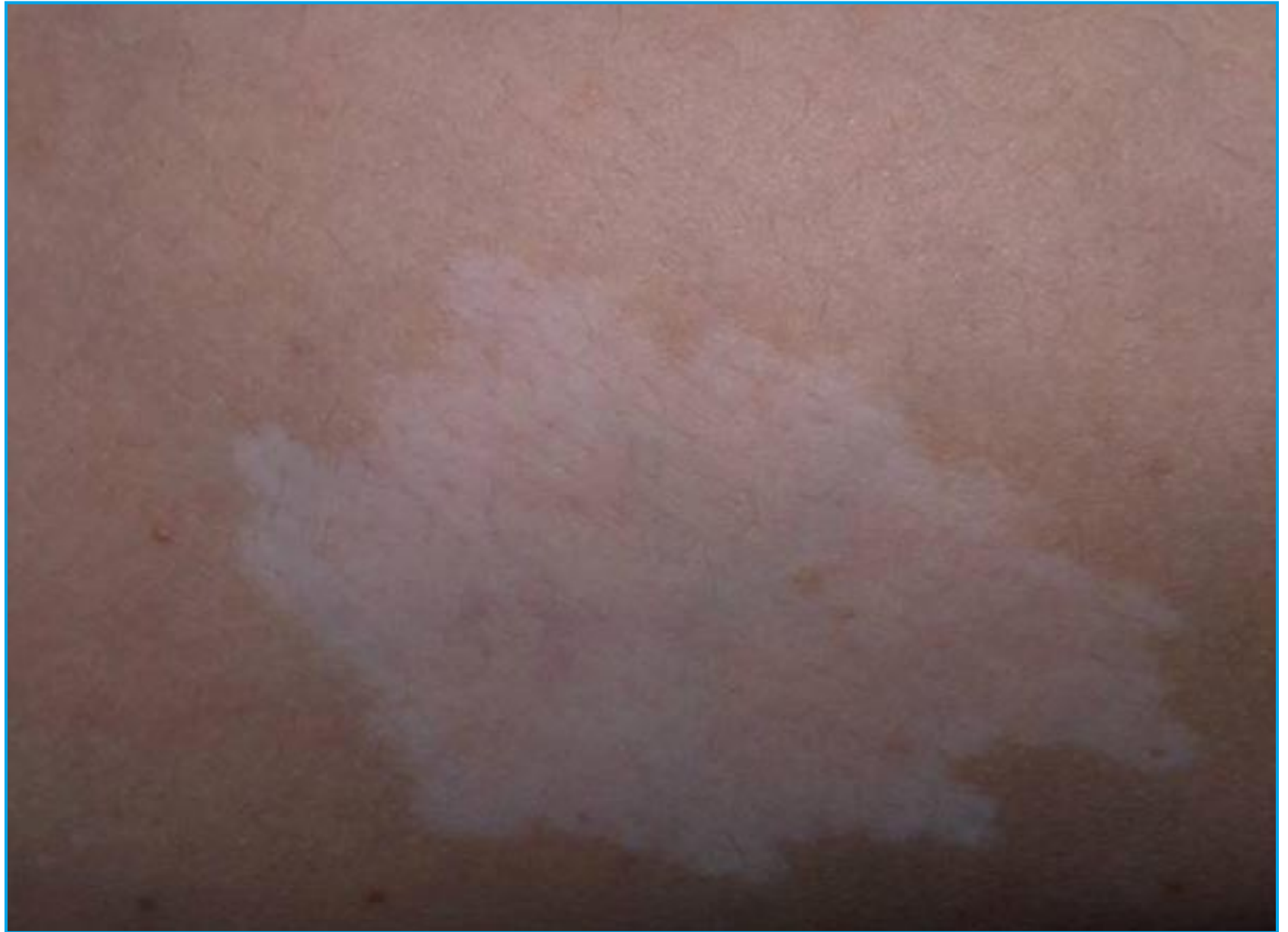Tatouage



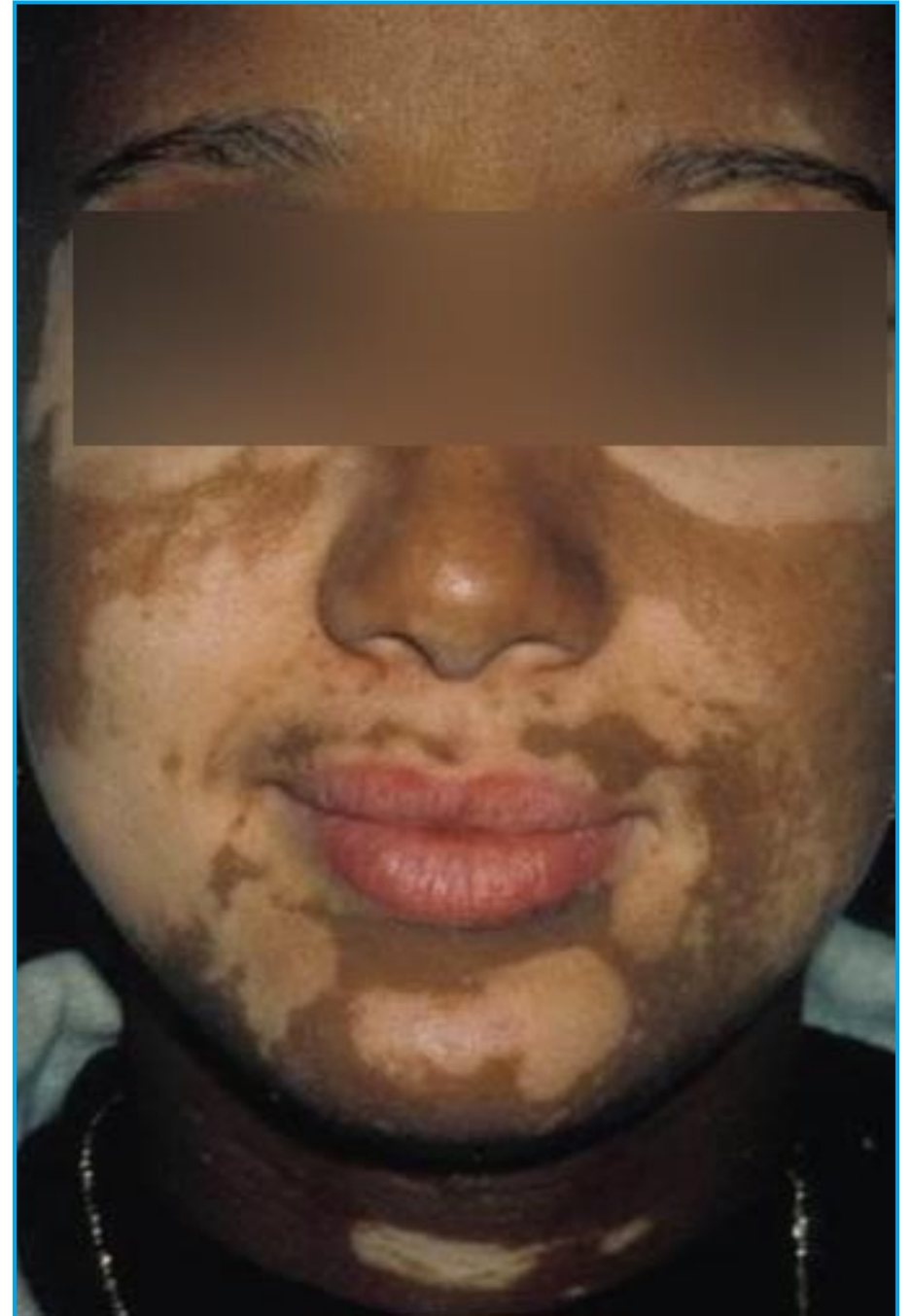Macule dépigmentée



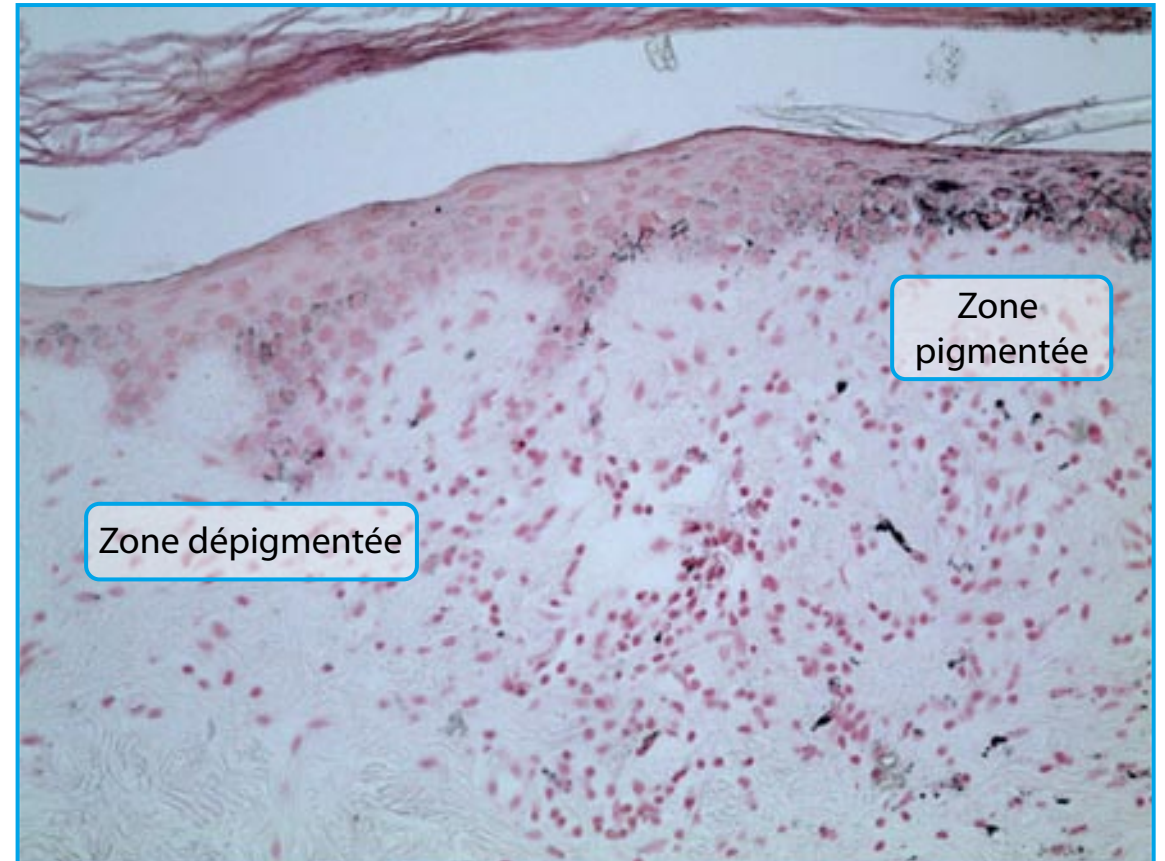
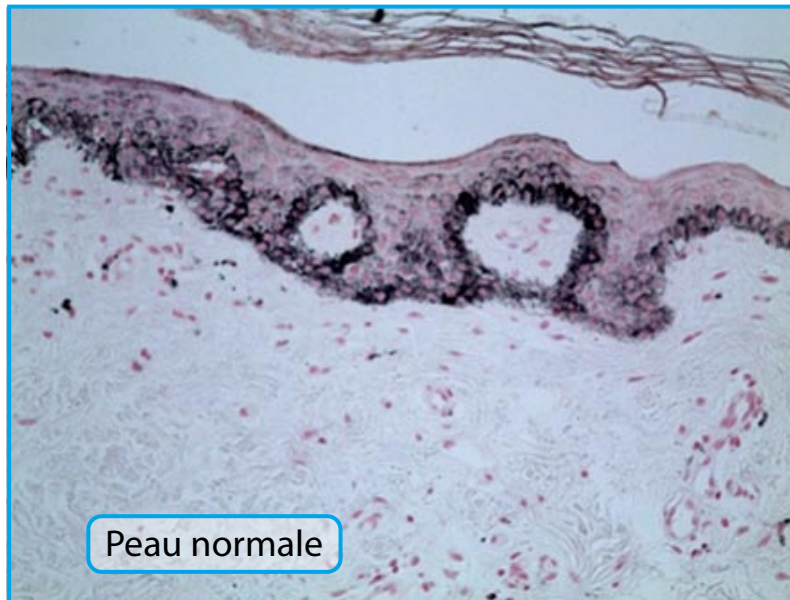
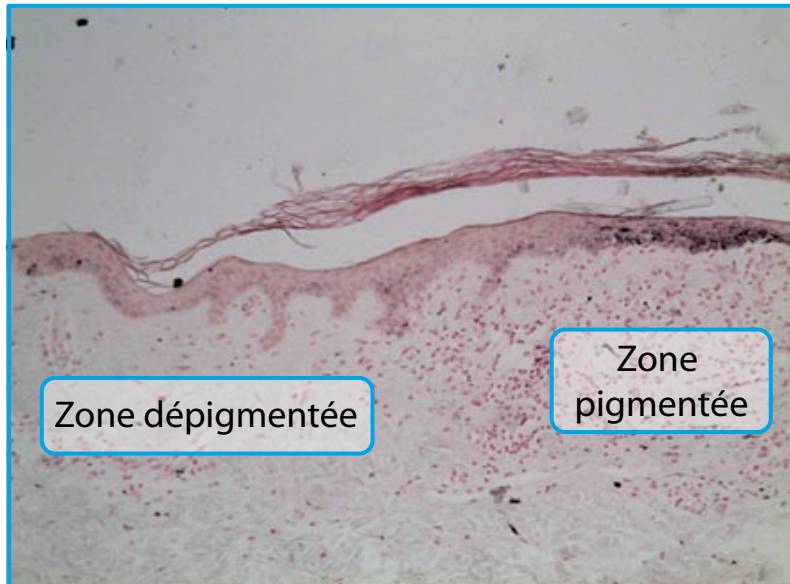
Macule dépigmentée



Macule dépigmentée

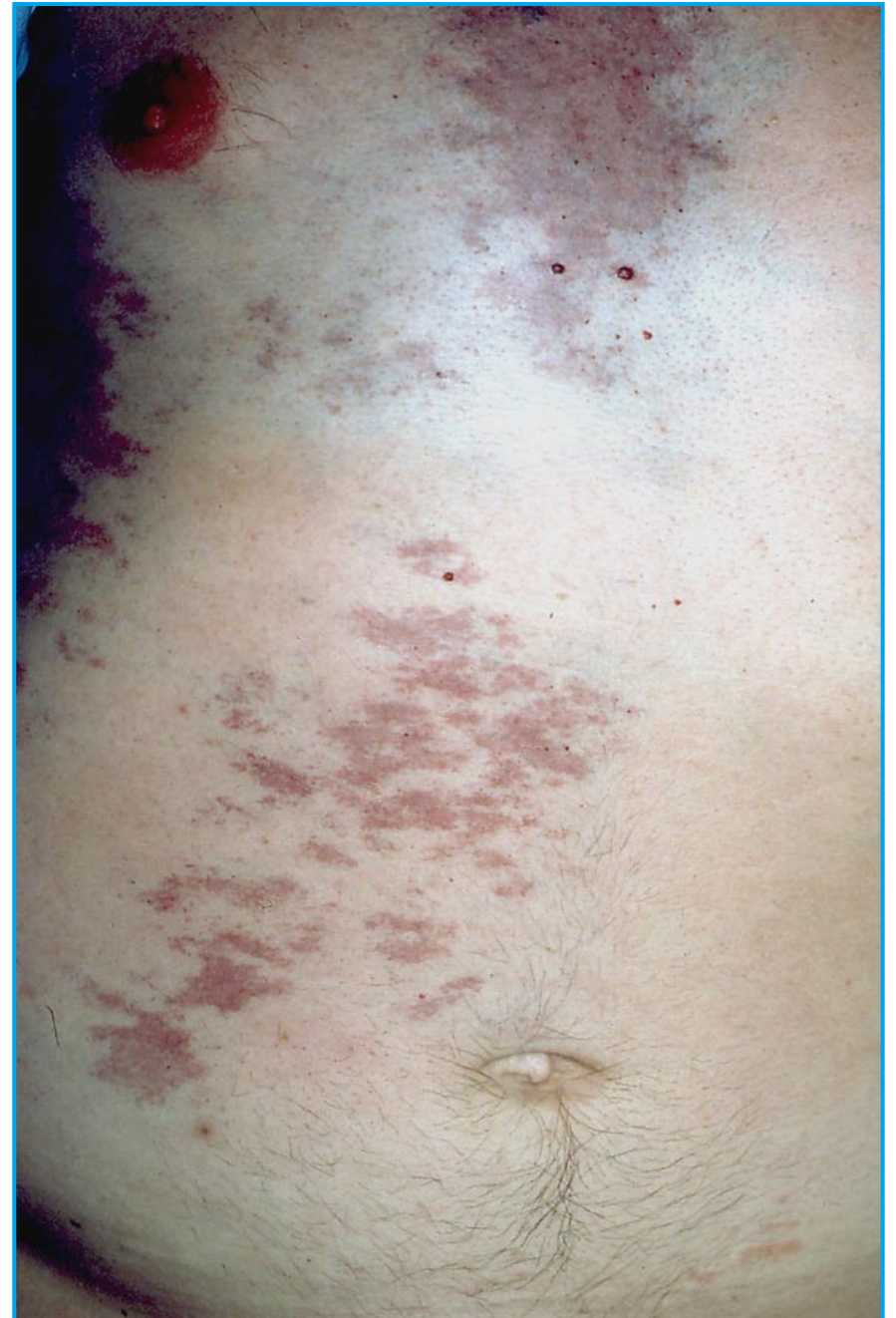

Coloration de la mélanine par le Fontana

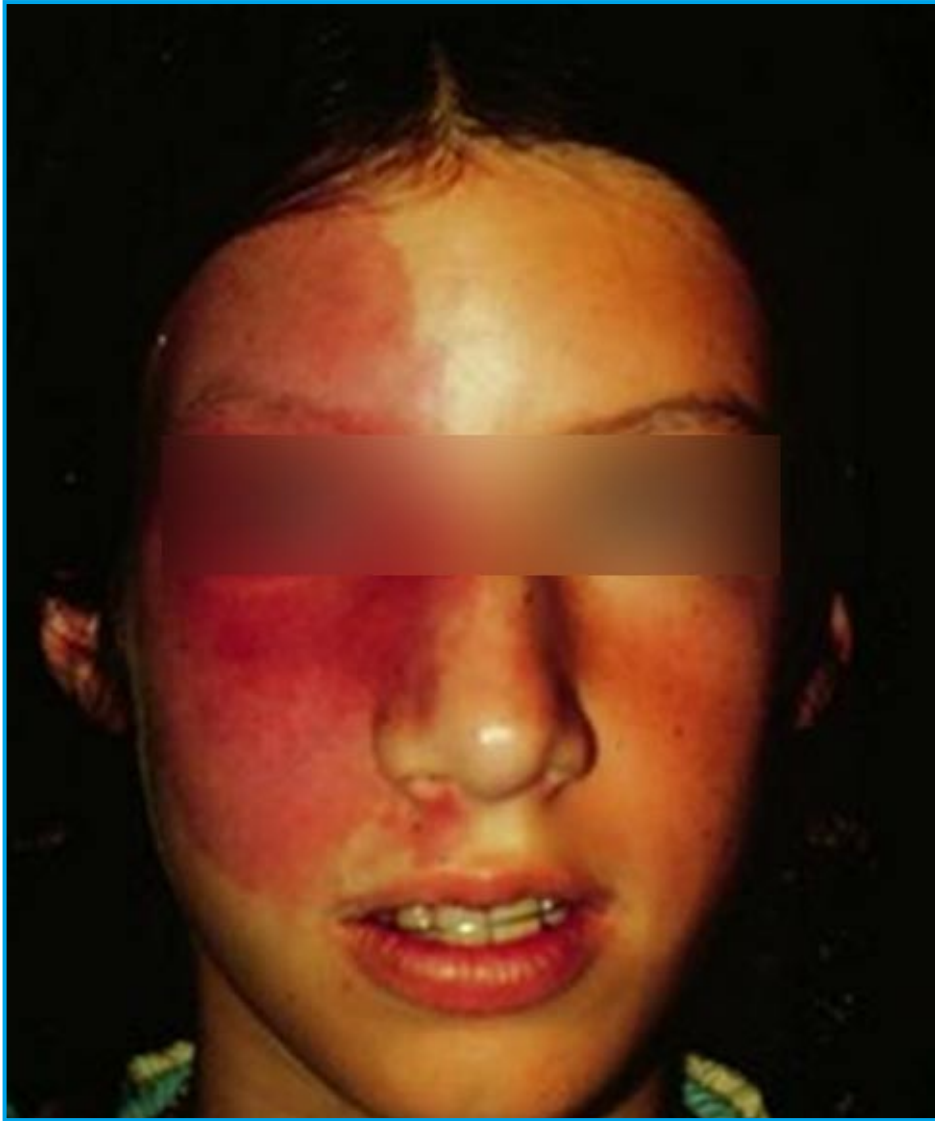

Macule vasculaire

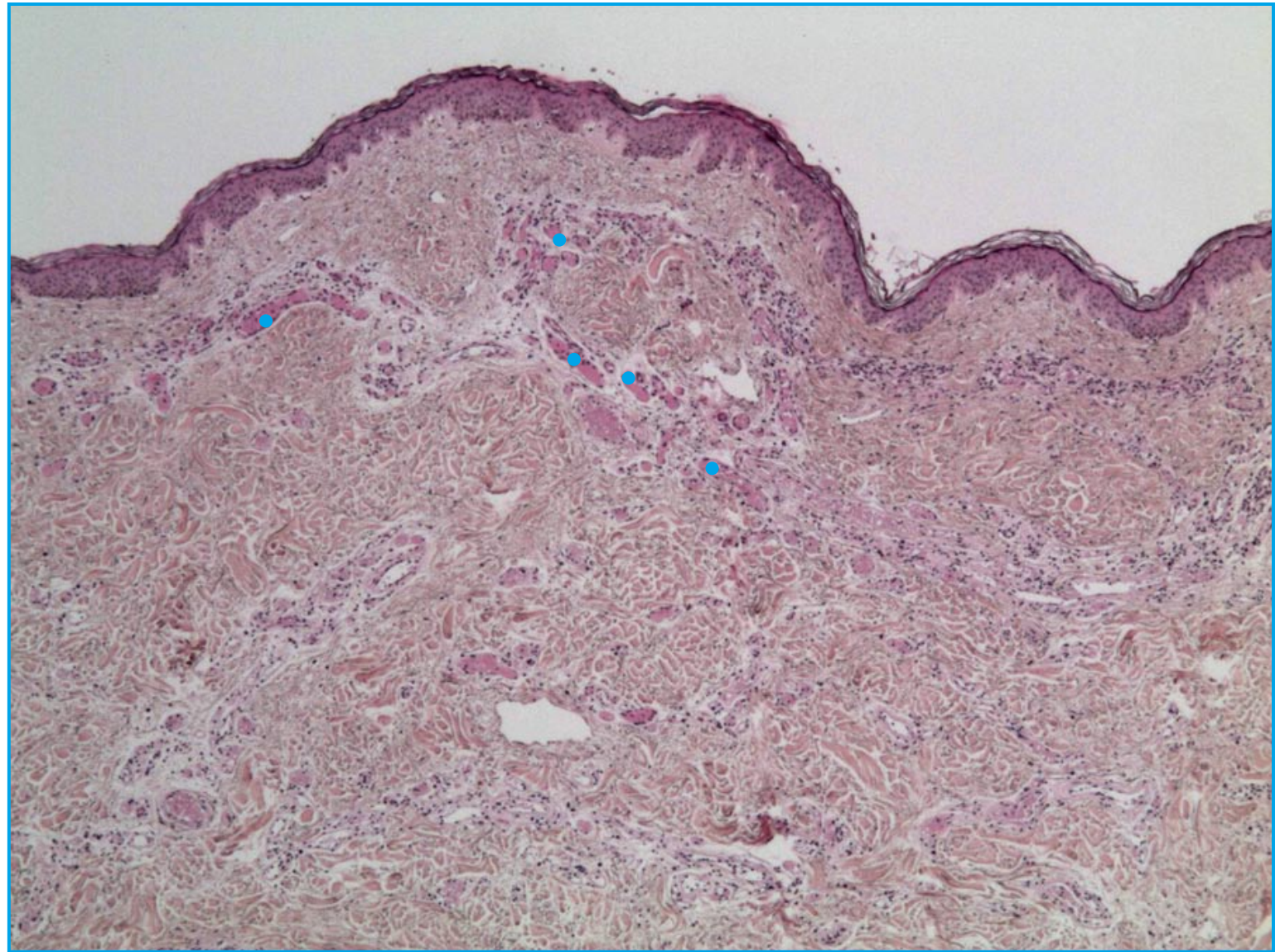
- ▶ Intérêt de l'examen dermoscopique



Macule vasculaire

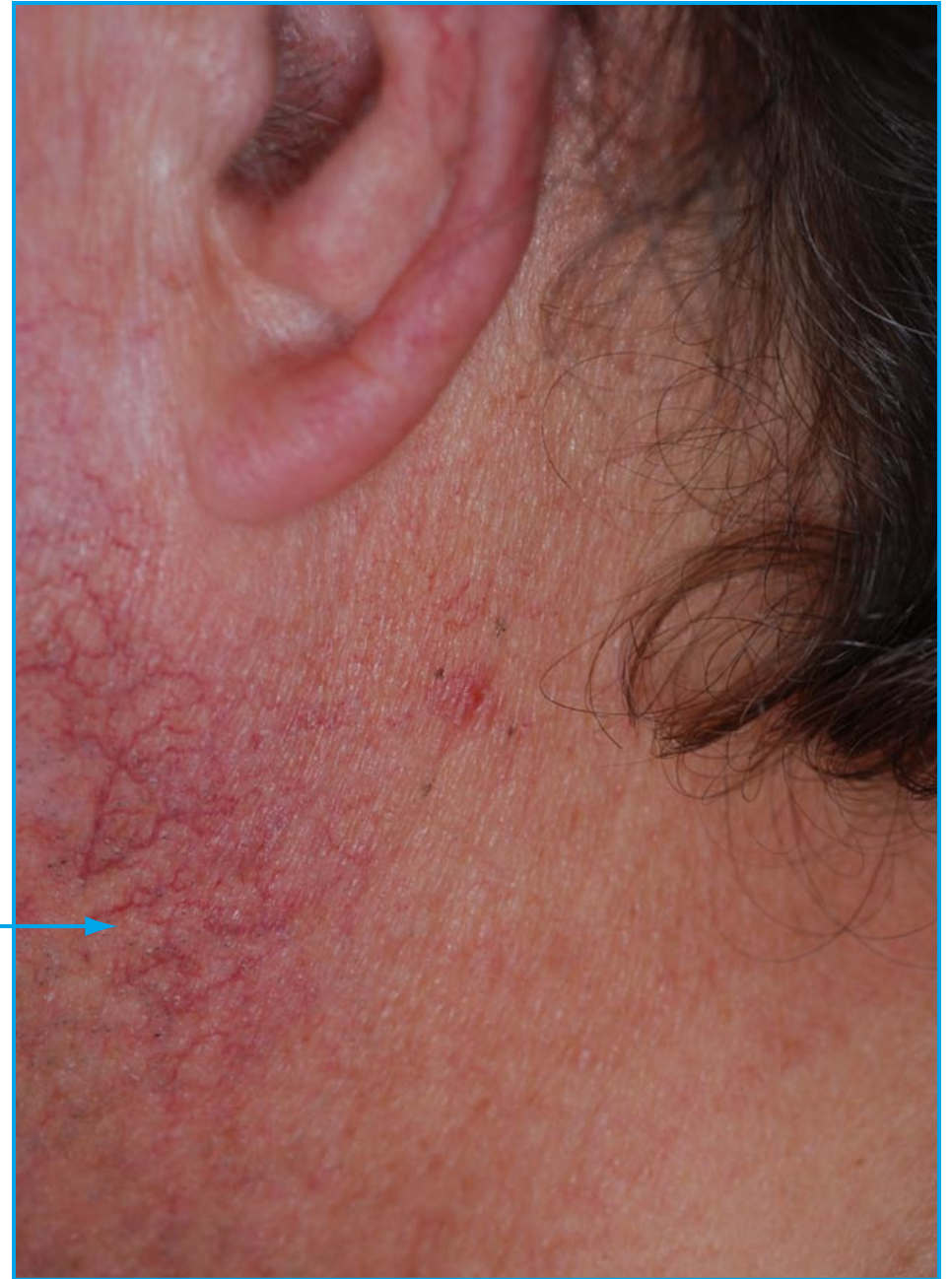

Nombreux vaisseaux capillaires dans le derme

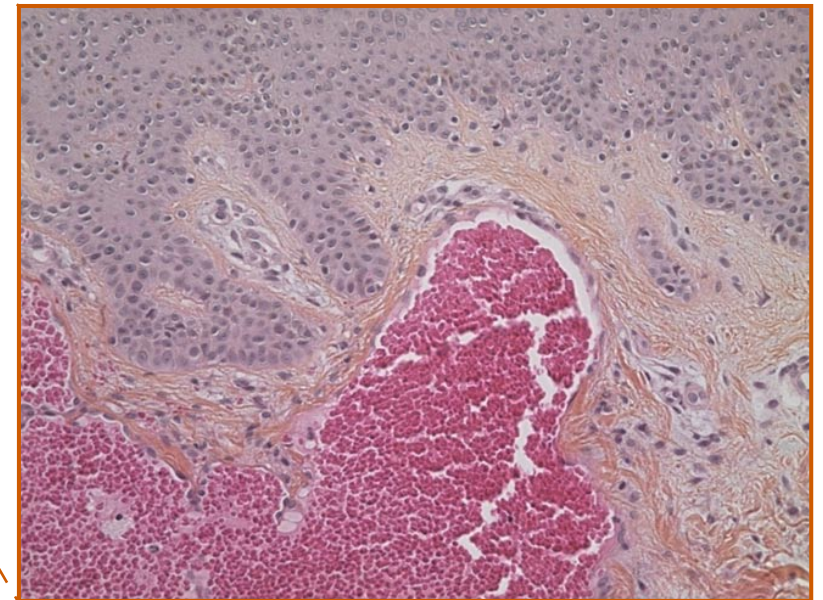
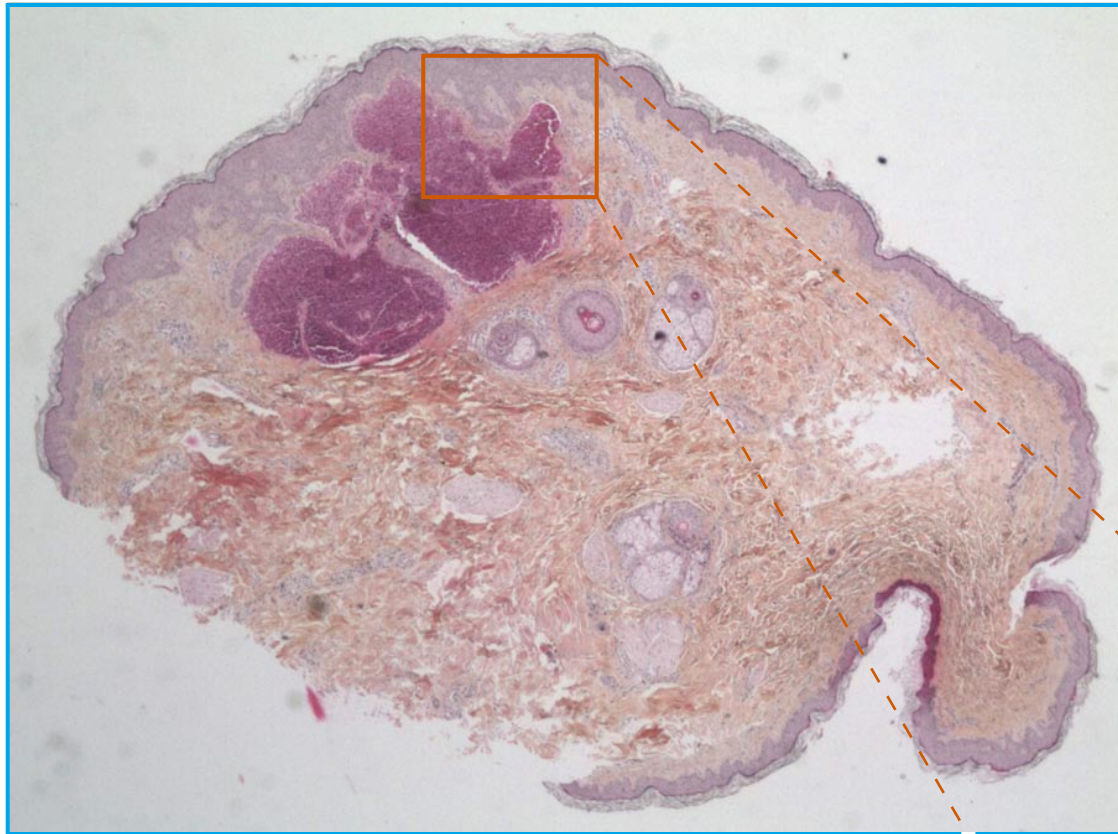


Télangiectasies

■ Télangiectasies




Vaisseau capillaire dilaté rempli de sang



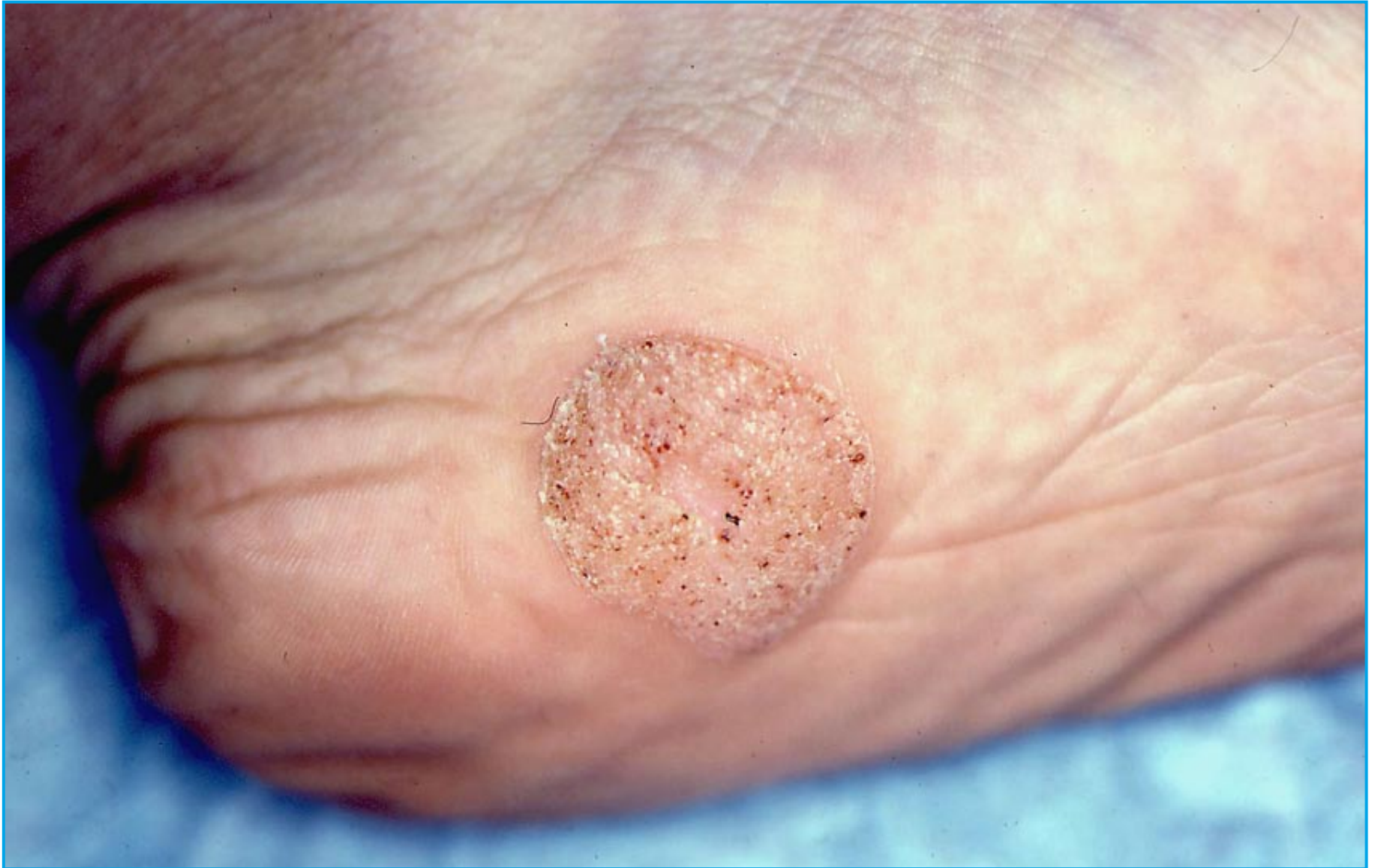Lésion tissulaire palpable

Papule (plaque, placard)

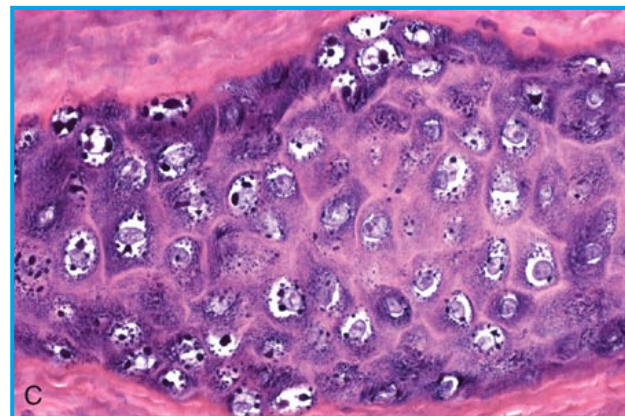
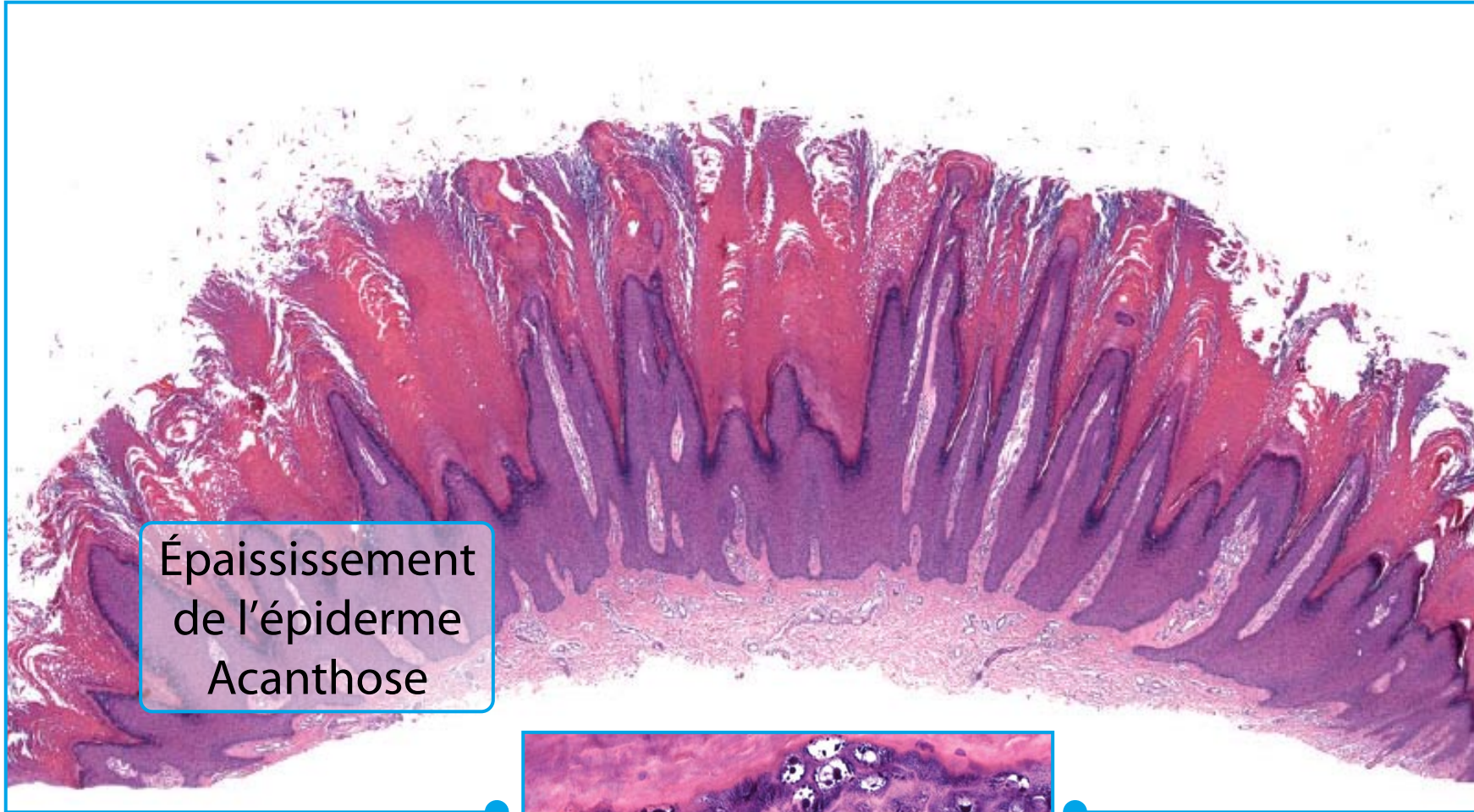
(origine épidermique ou dermique)



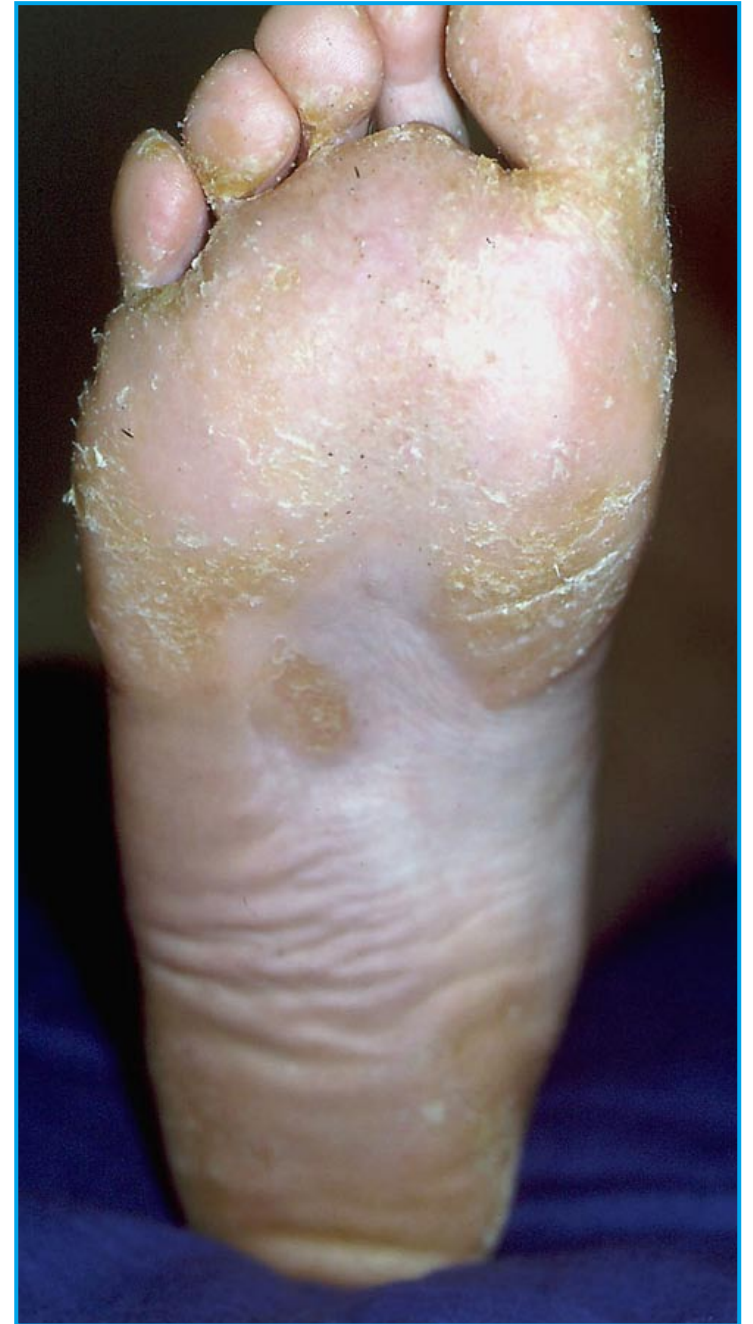Papule épidermique



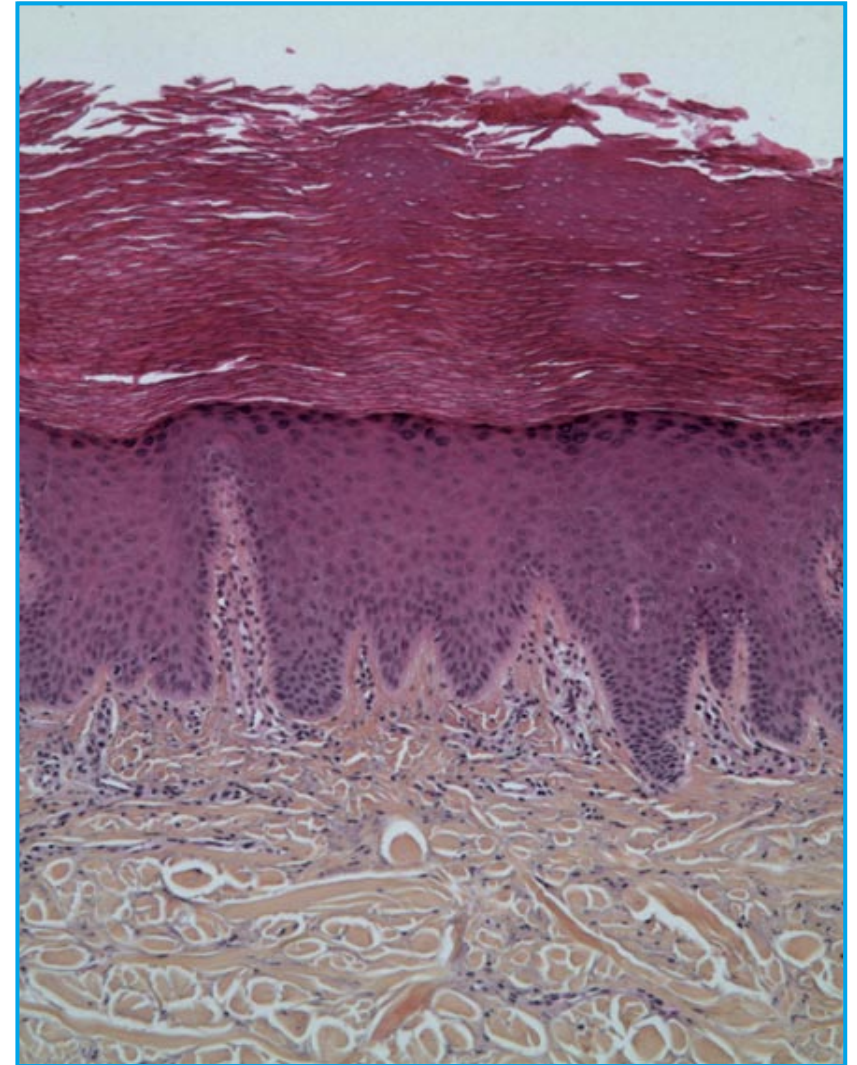
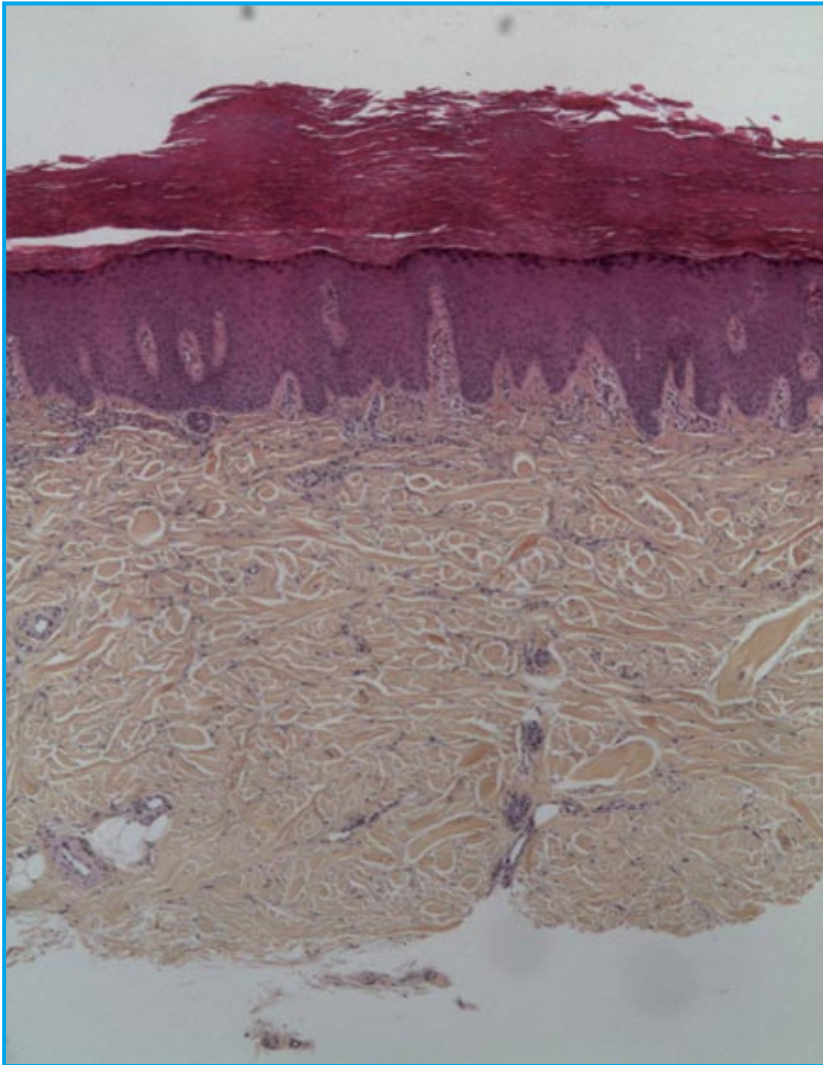
Épaississement de l'épiderme : acanthose



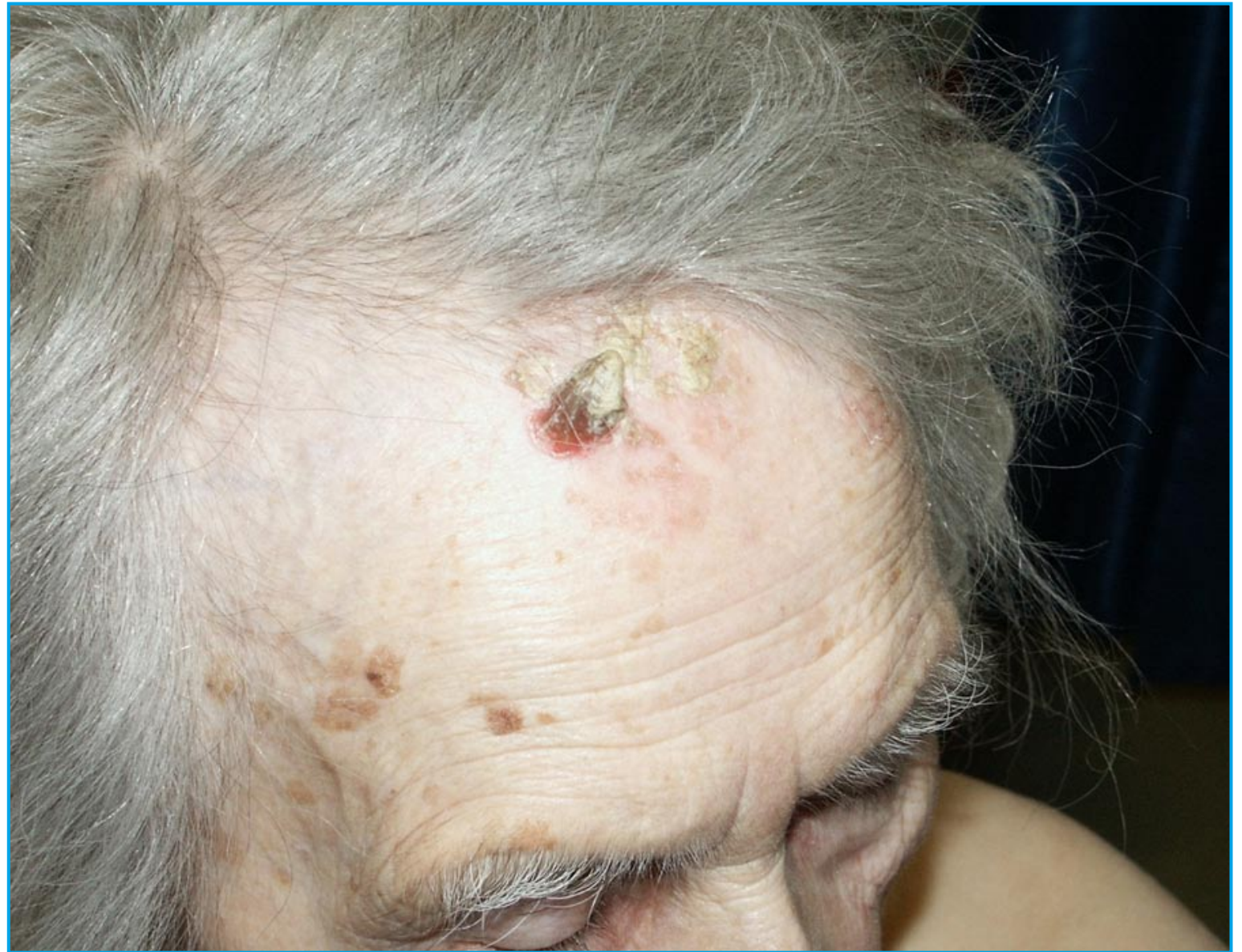Papule épidermique : kératose



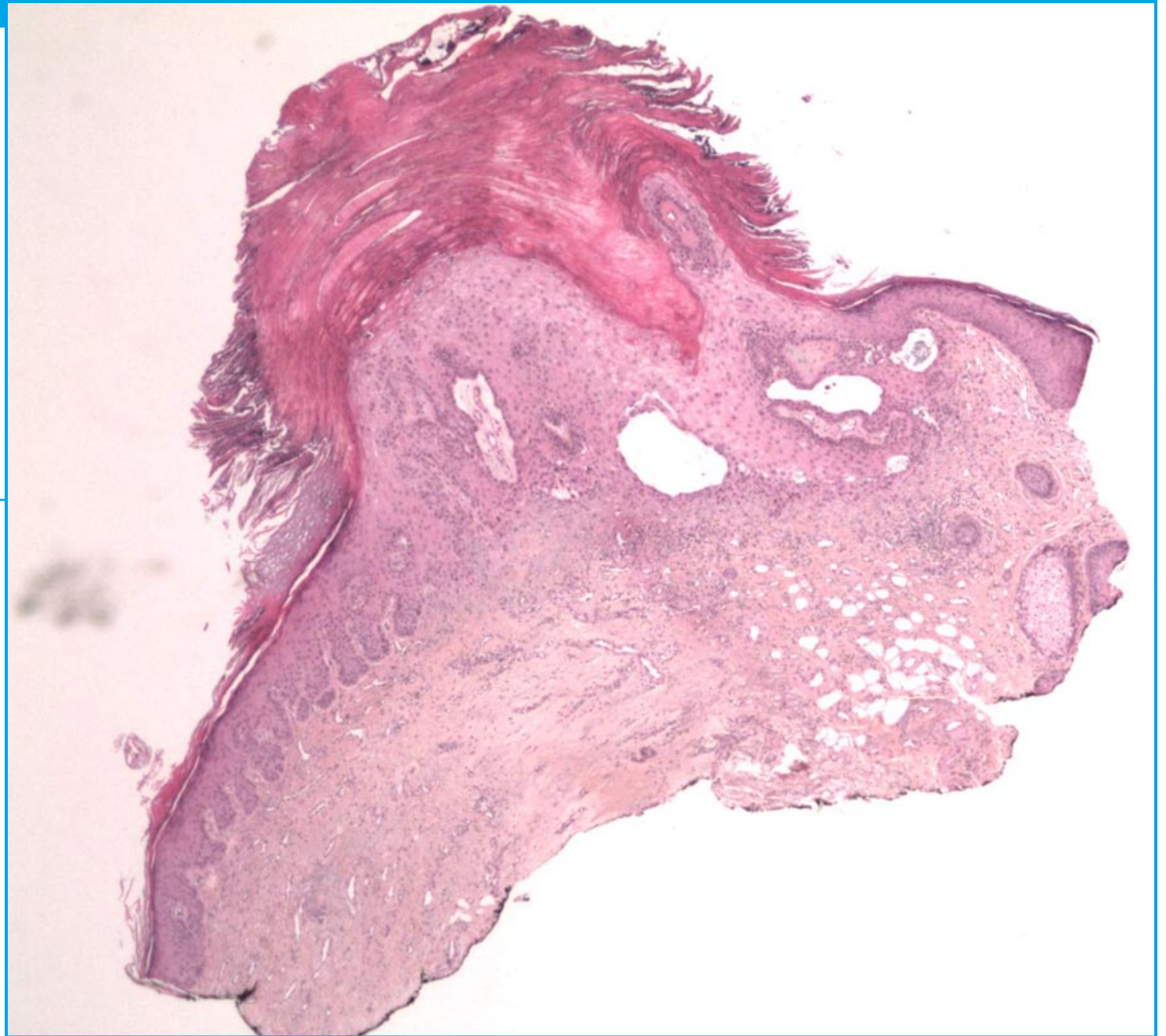
Épaississement de la couche cornée



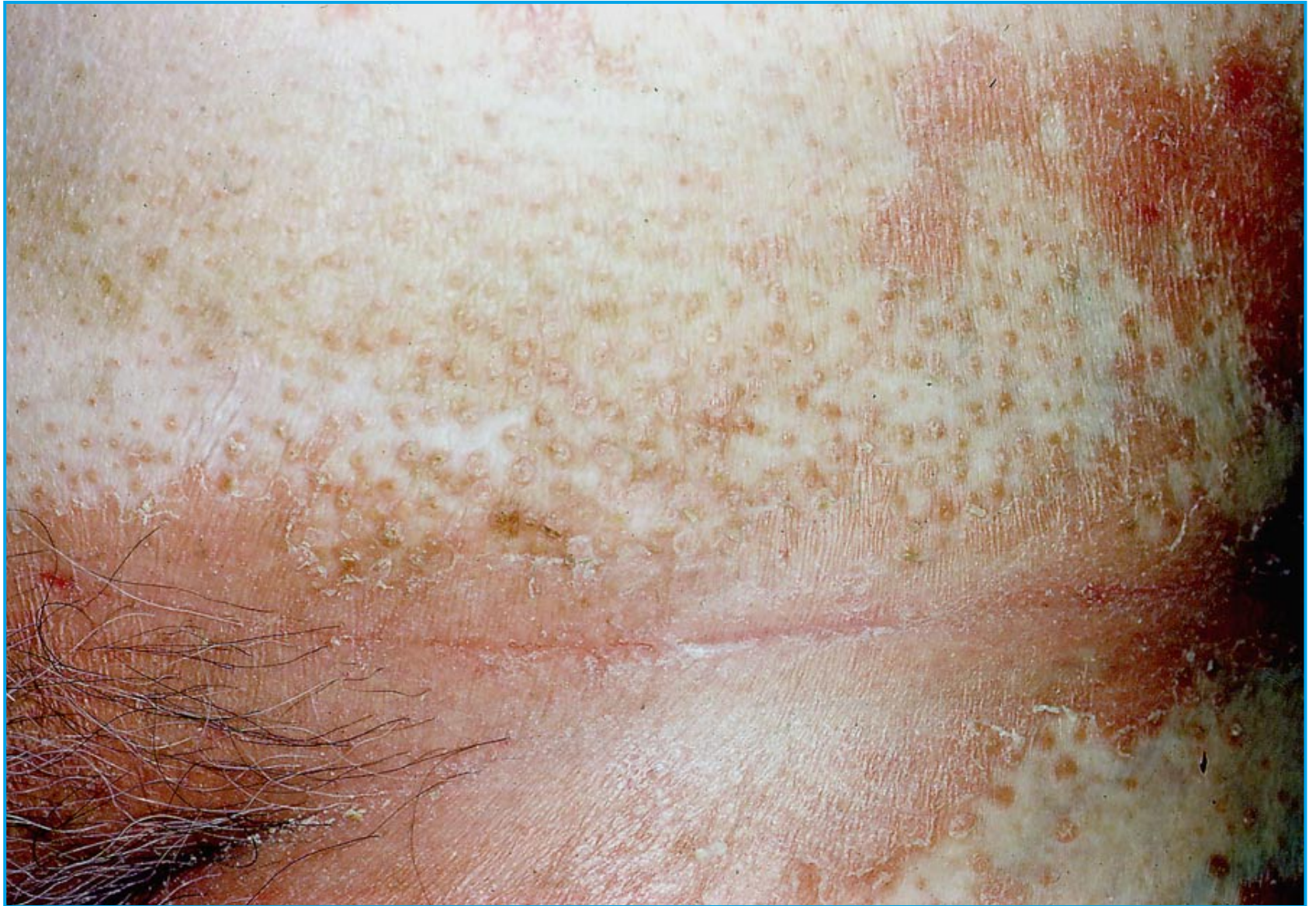Papule épidermique : corne



- Couche cornée
très épaisse



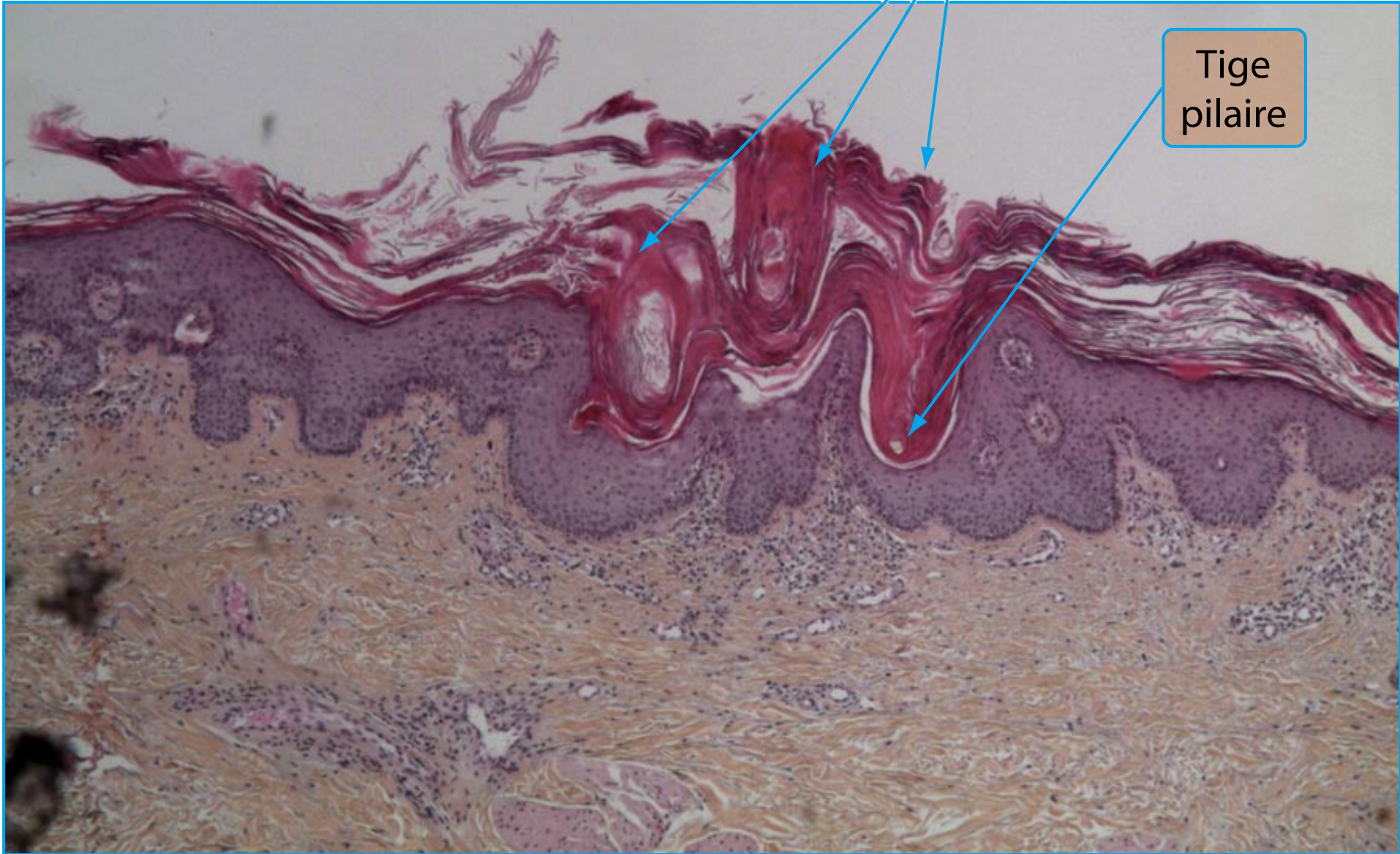
Papule épidermique folliculaire



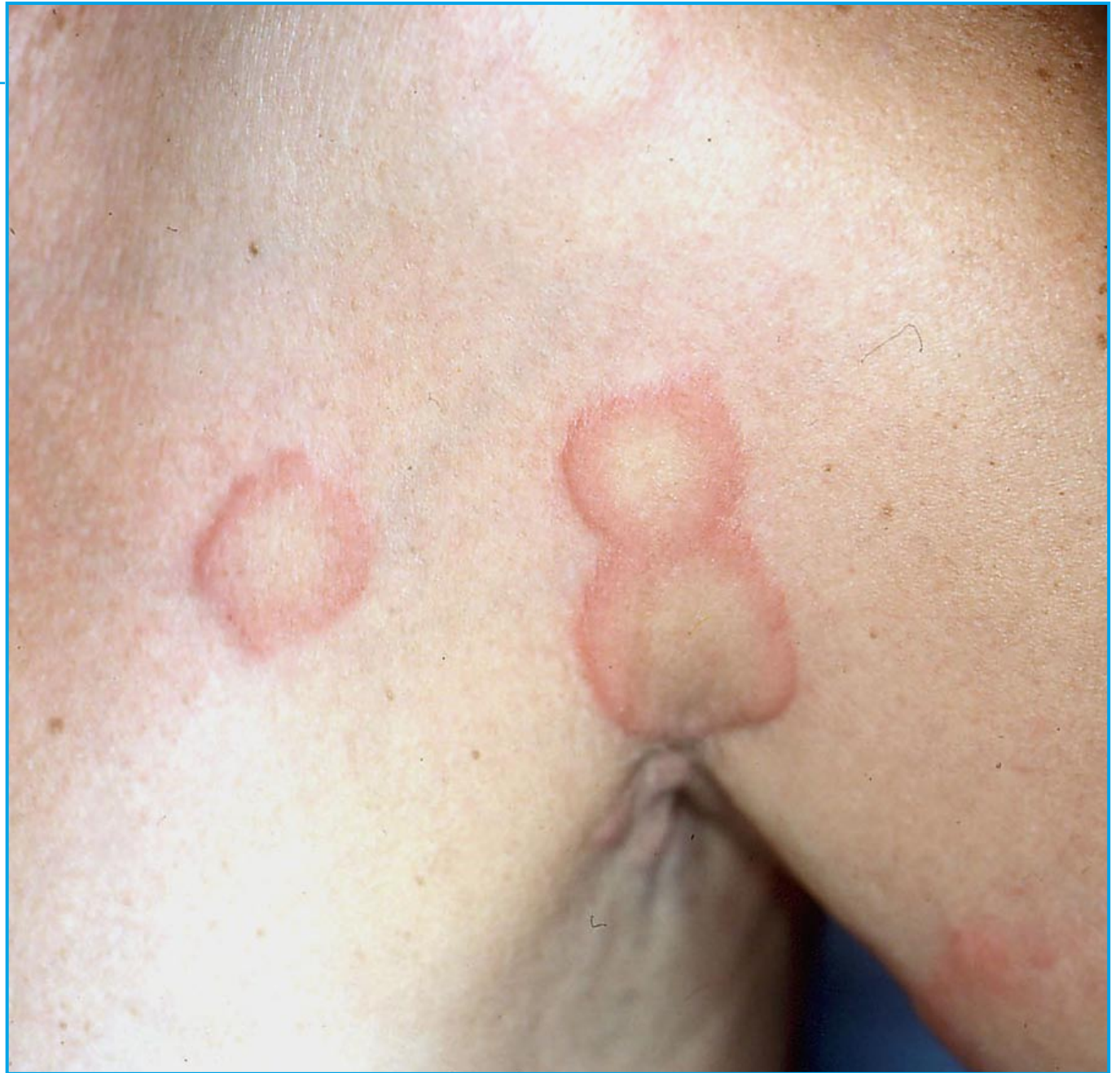Papules folliculaires

Hyperkératose
des ostiums folliculaires

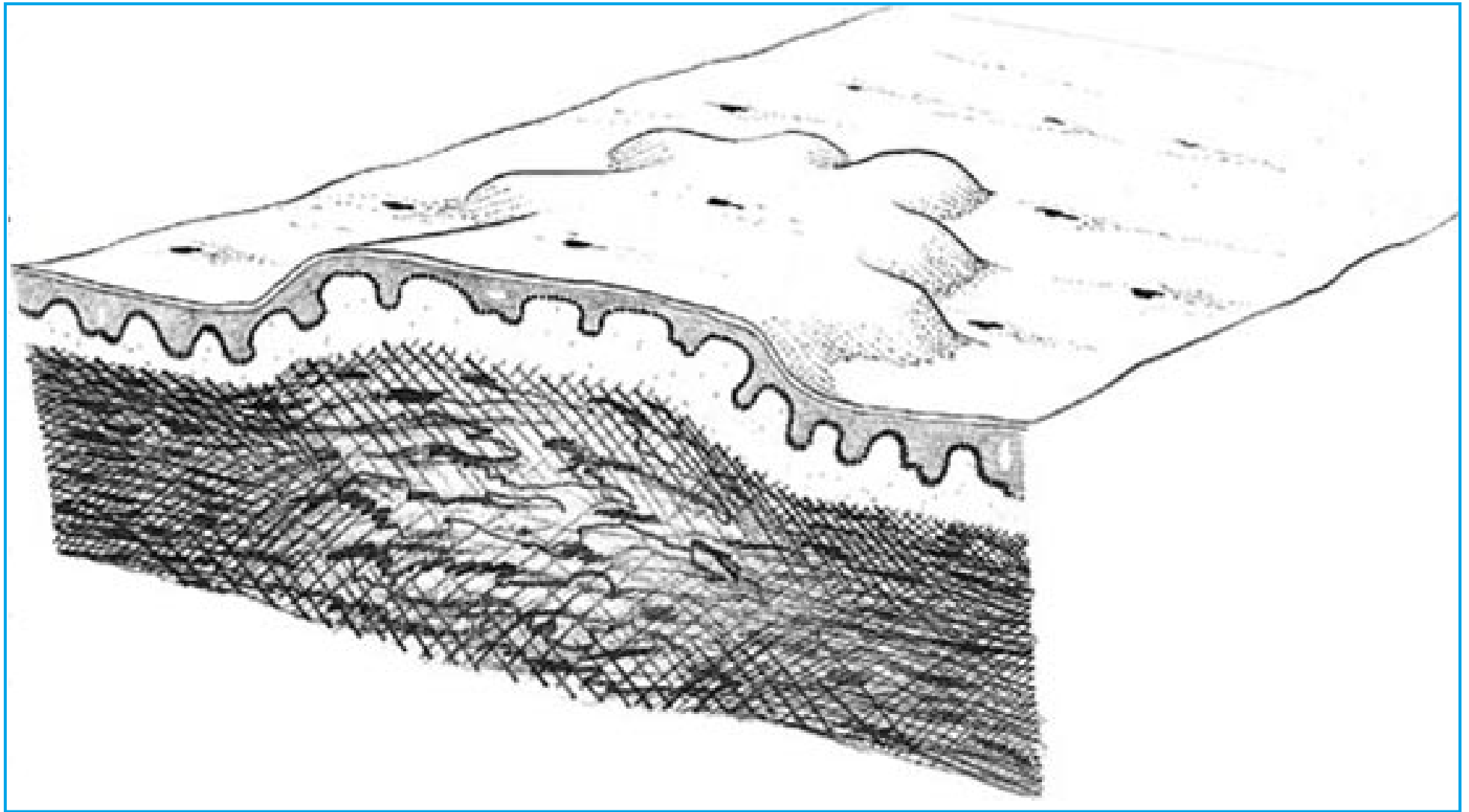
Tige
pilaire



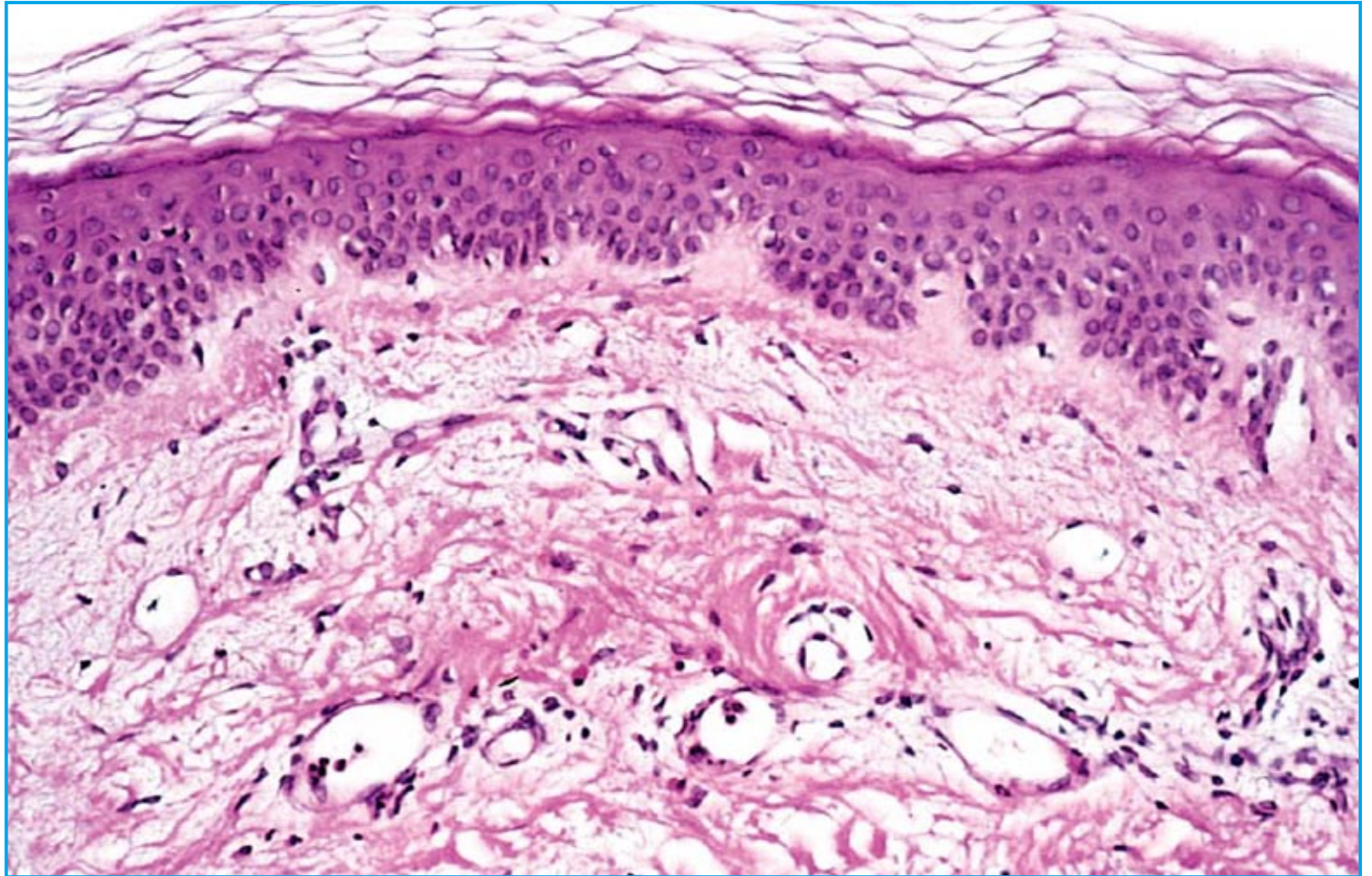
**Papule
dermique
oedémateuse**



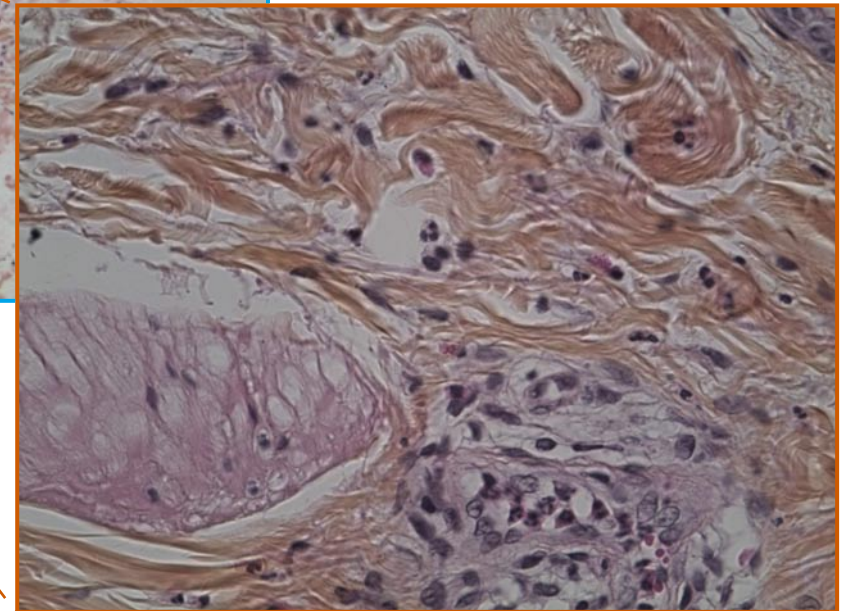
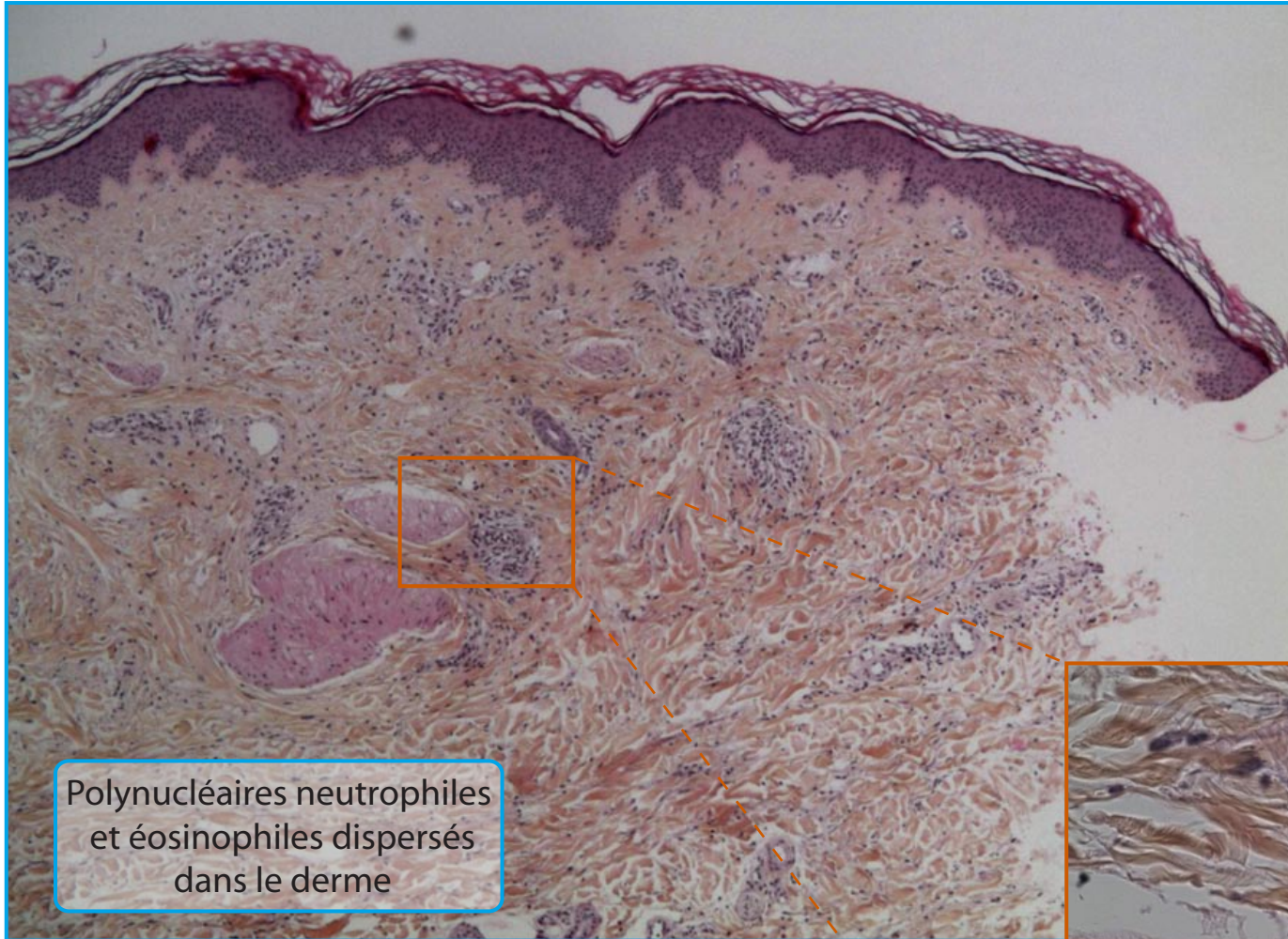
Papule dermique oedémateuse



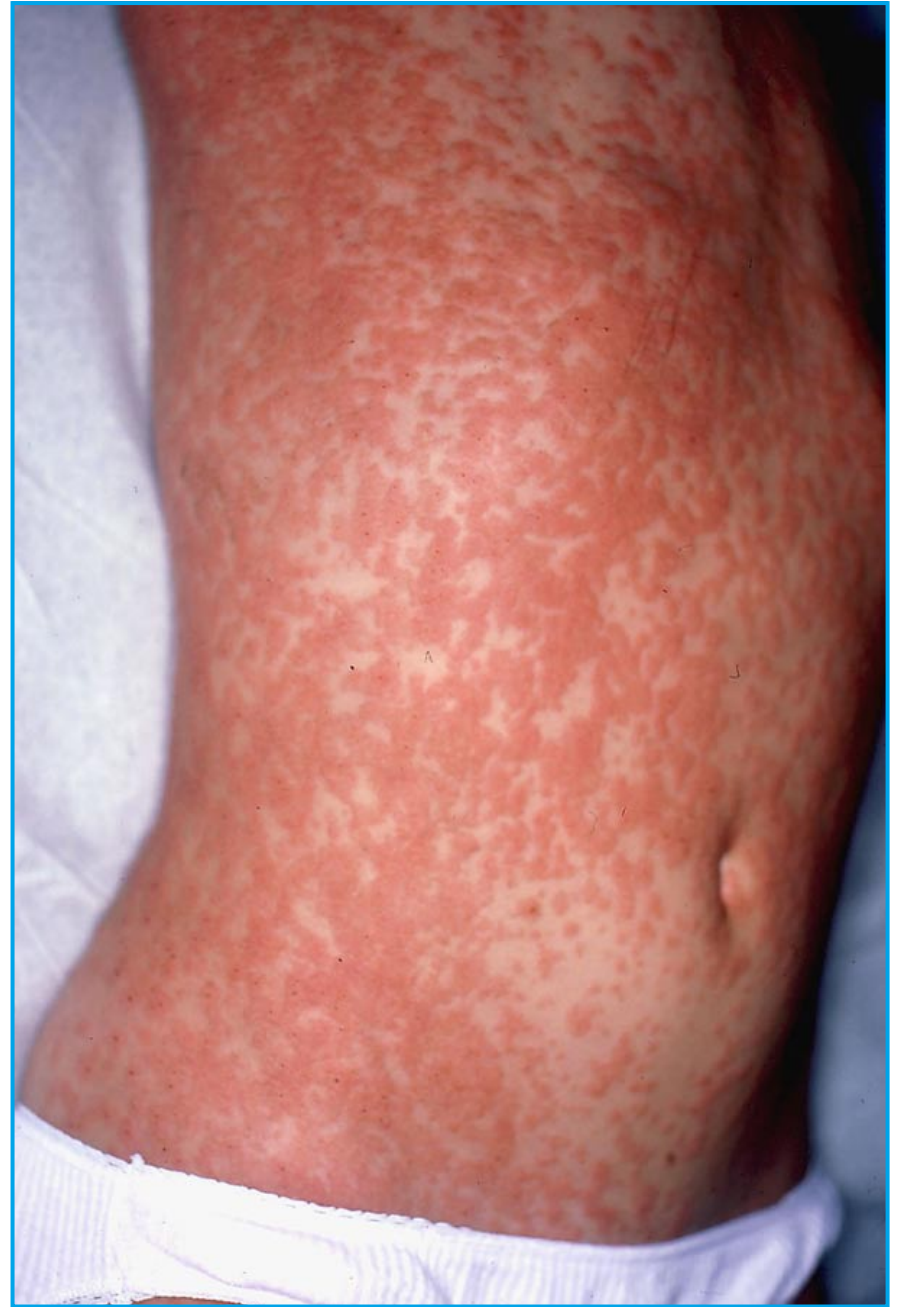Oedème



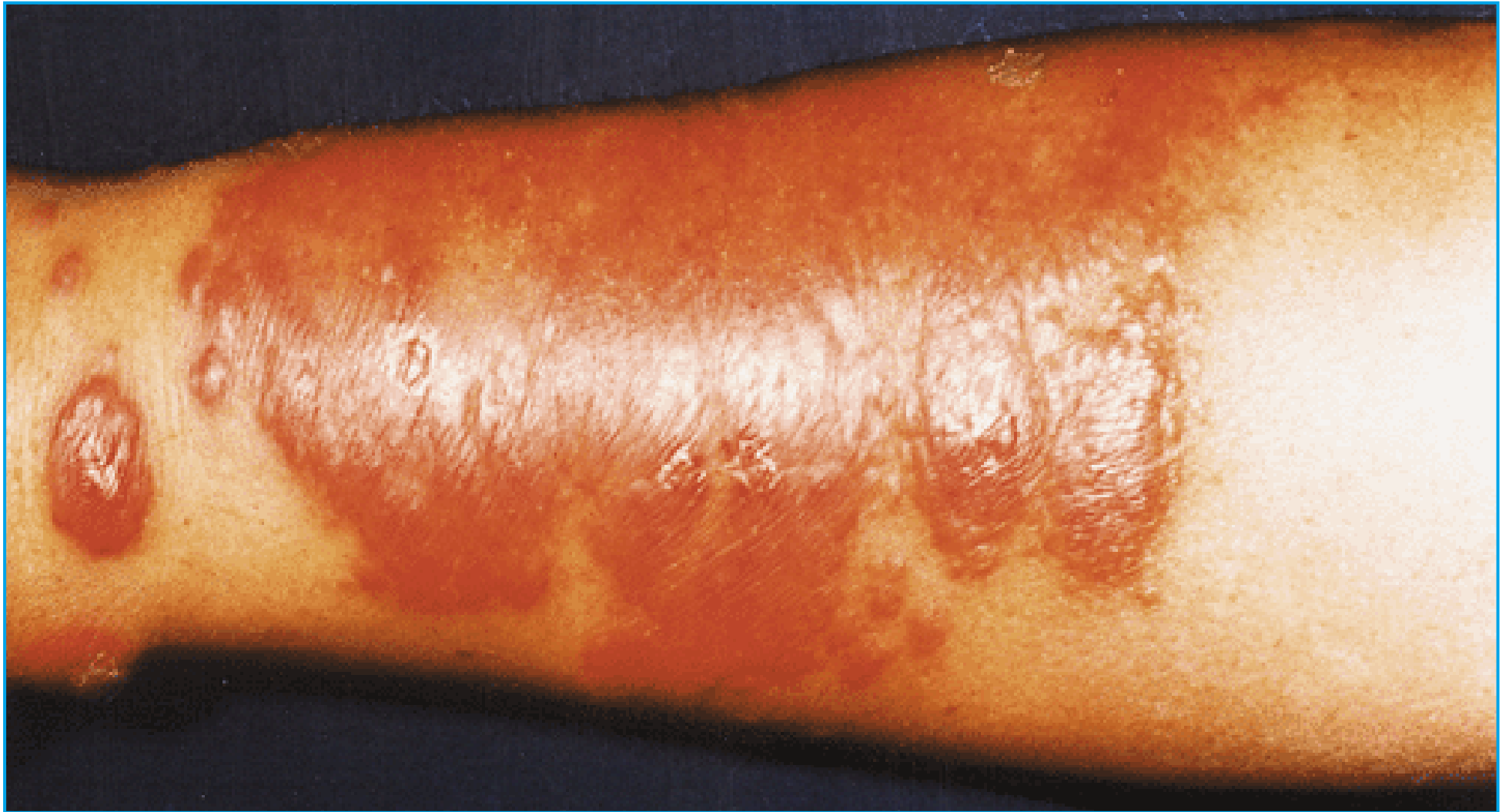Copyright © 2010 by Saunders, an imprint of Elsevier Inc



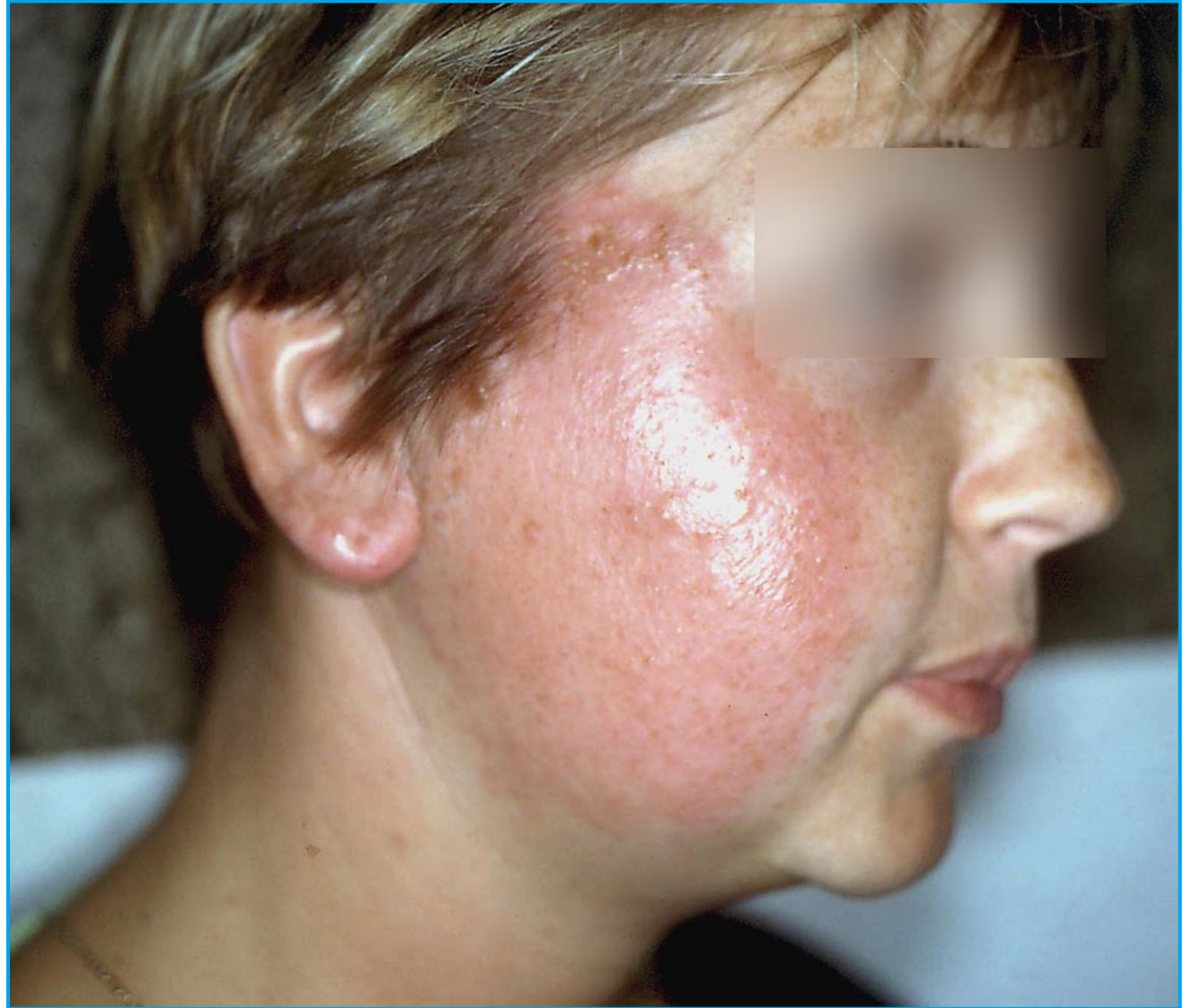Papule dermique oedémateuse



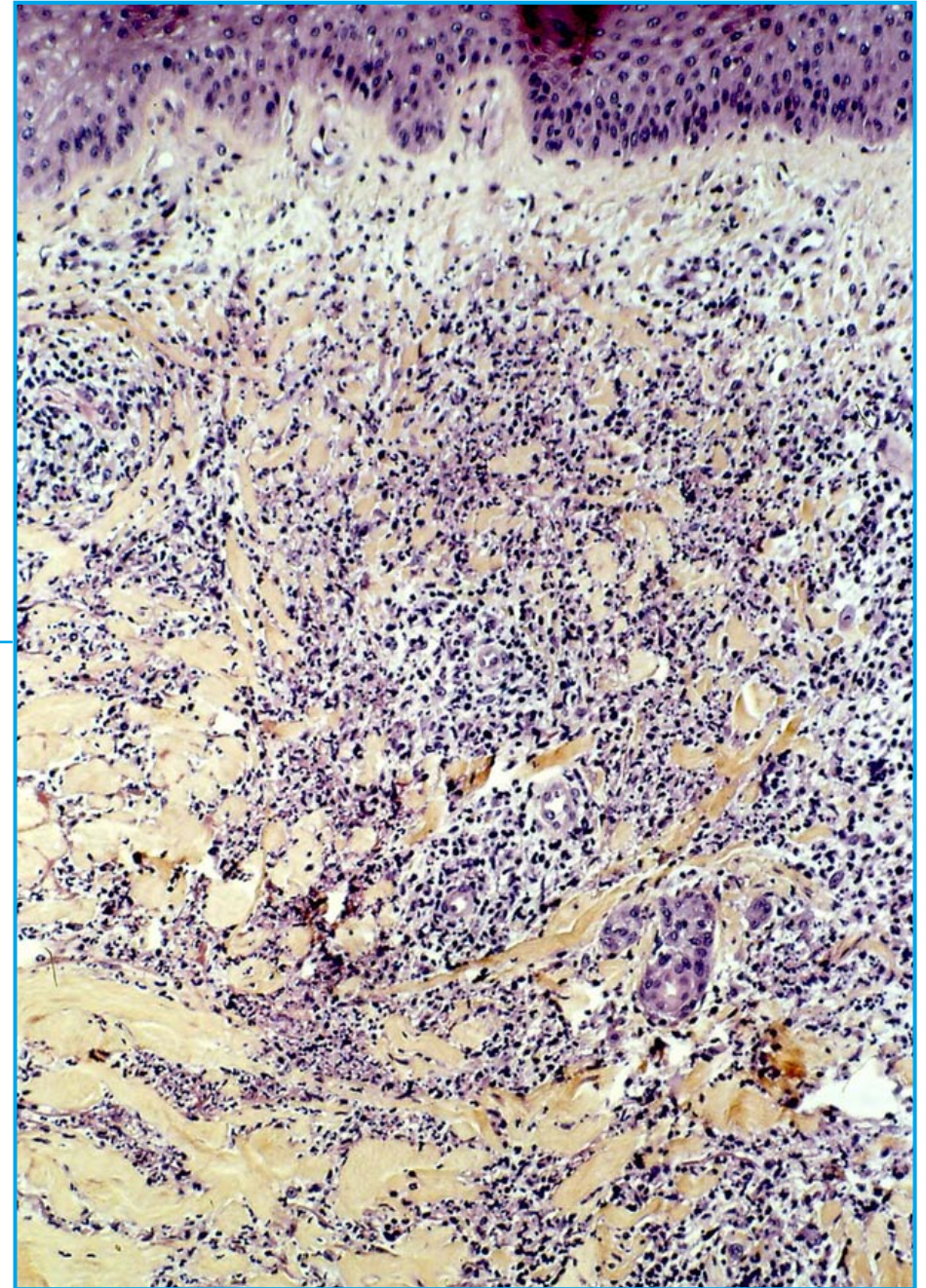
Placard érythémateux



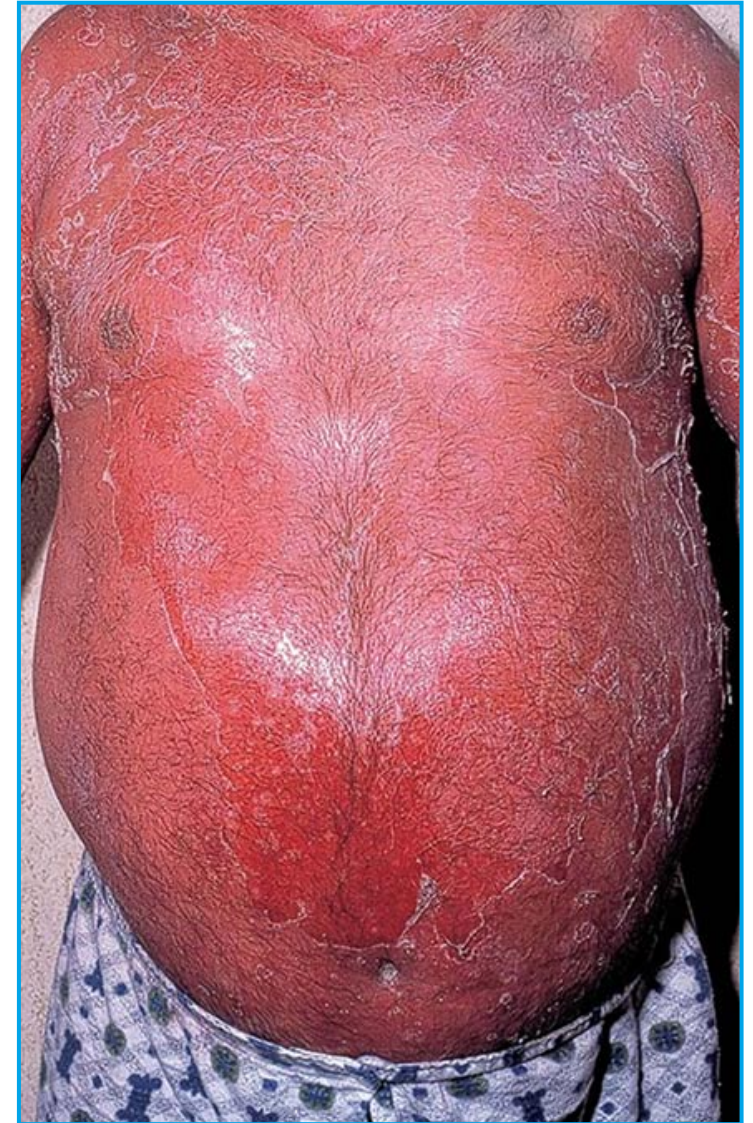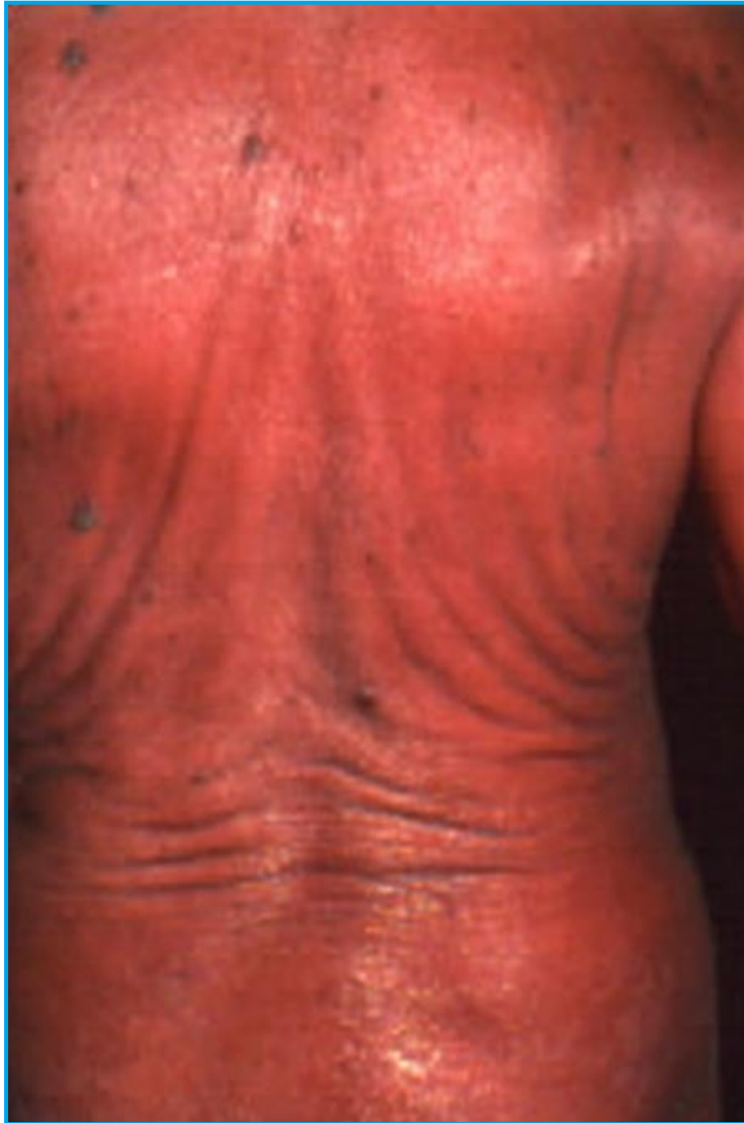Placard érythémateux



- Nombreux polynucléaires neutrophiles dans le derme



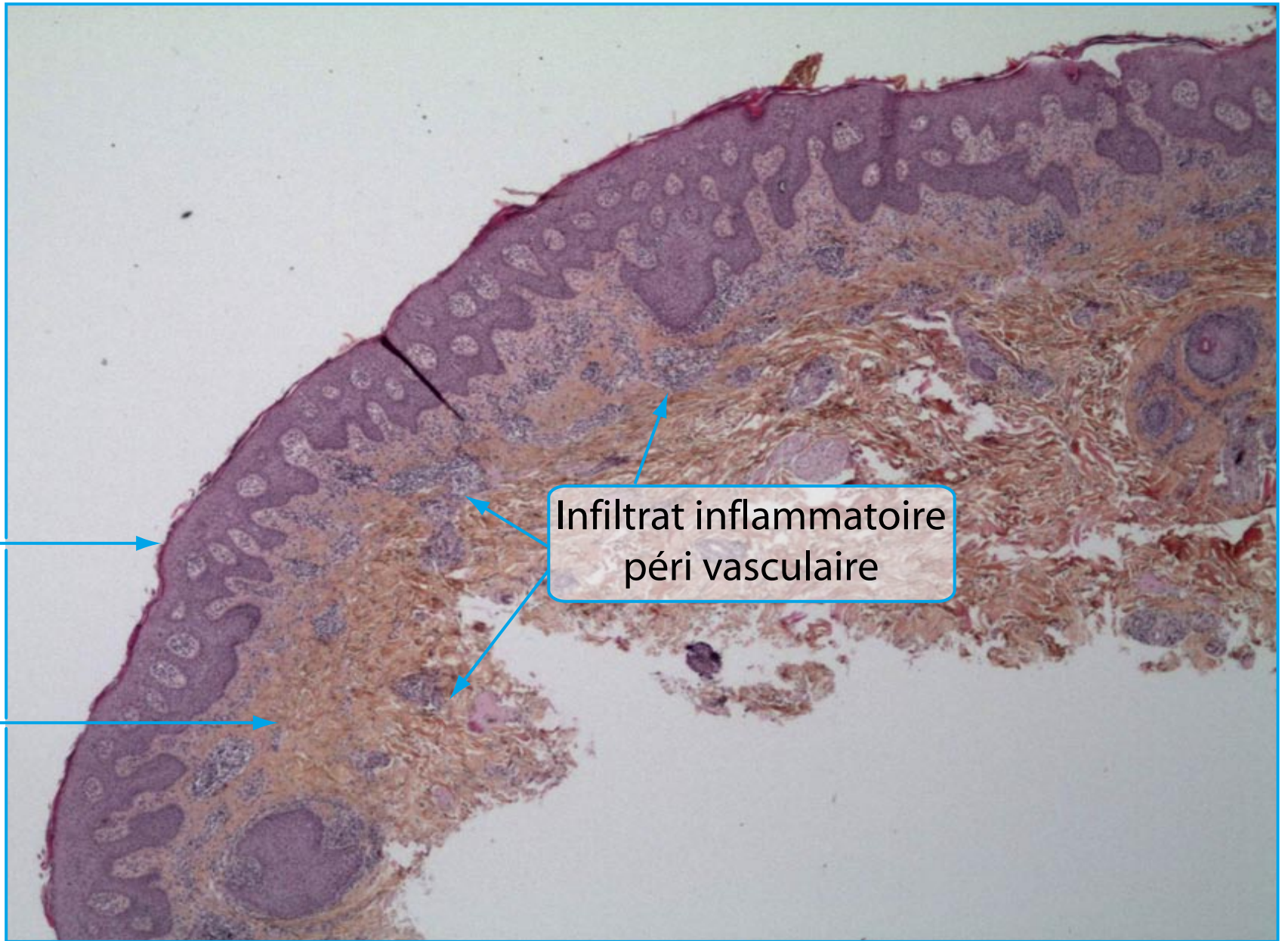
Érythrodermie

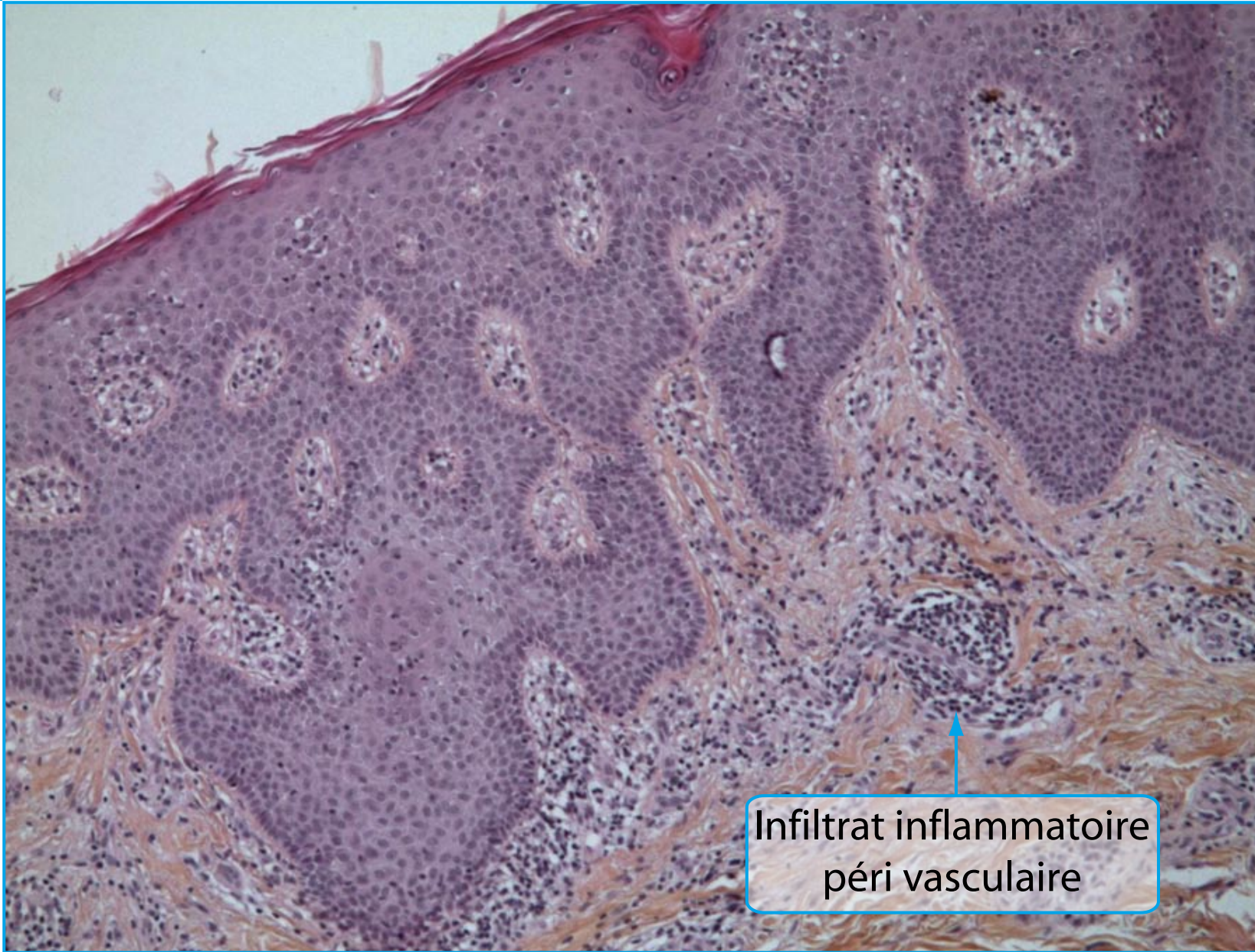

■ Épiderme

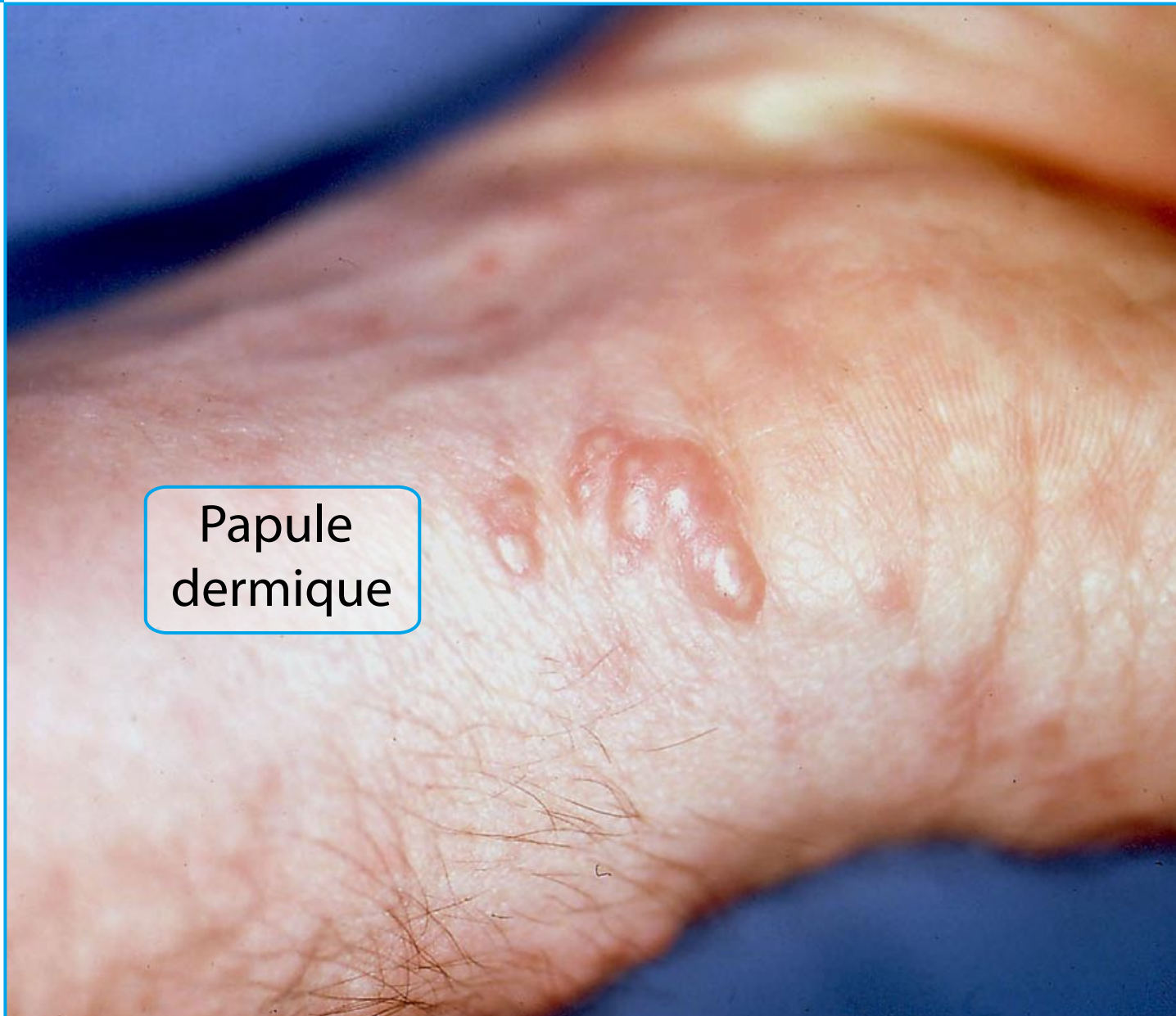■ Derme

Infiltrat inflammatoire
péri vasculaire

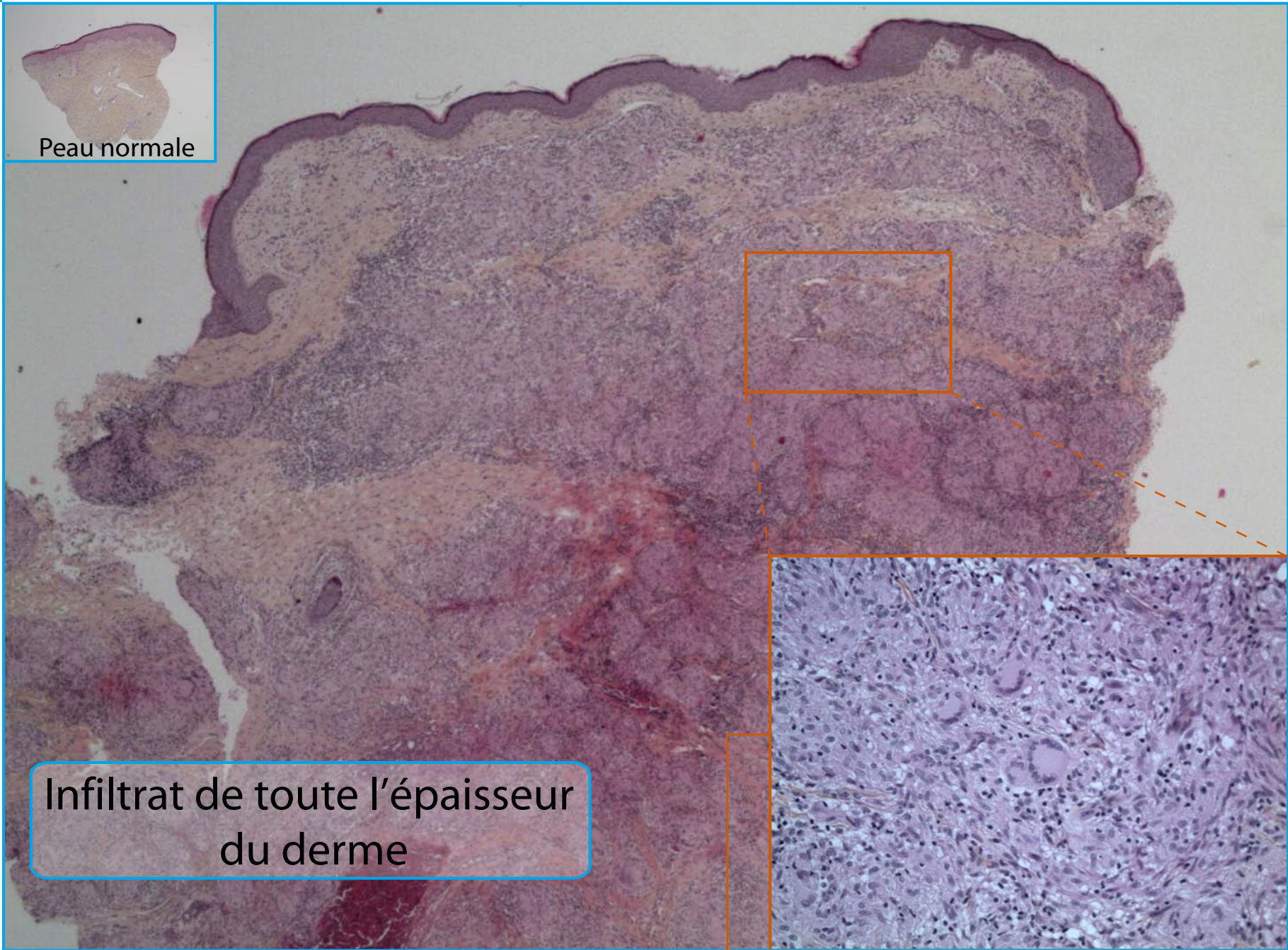




Infiltrat inflammatoire
péri vasculaire



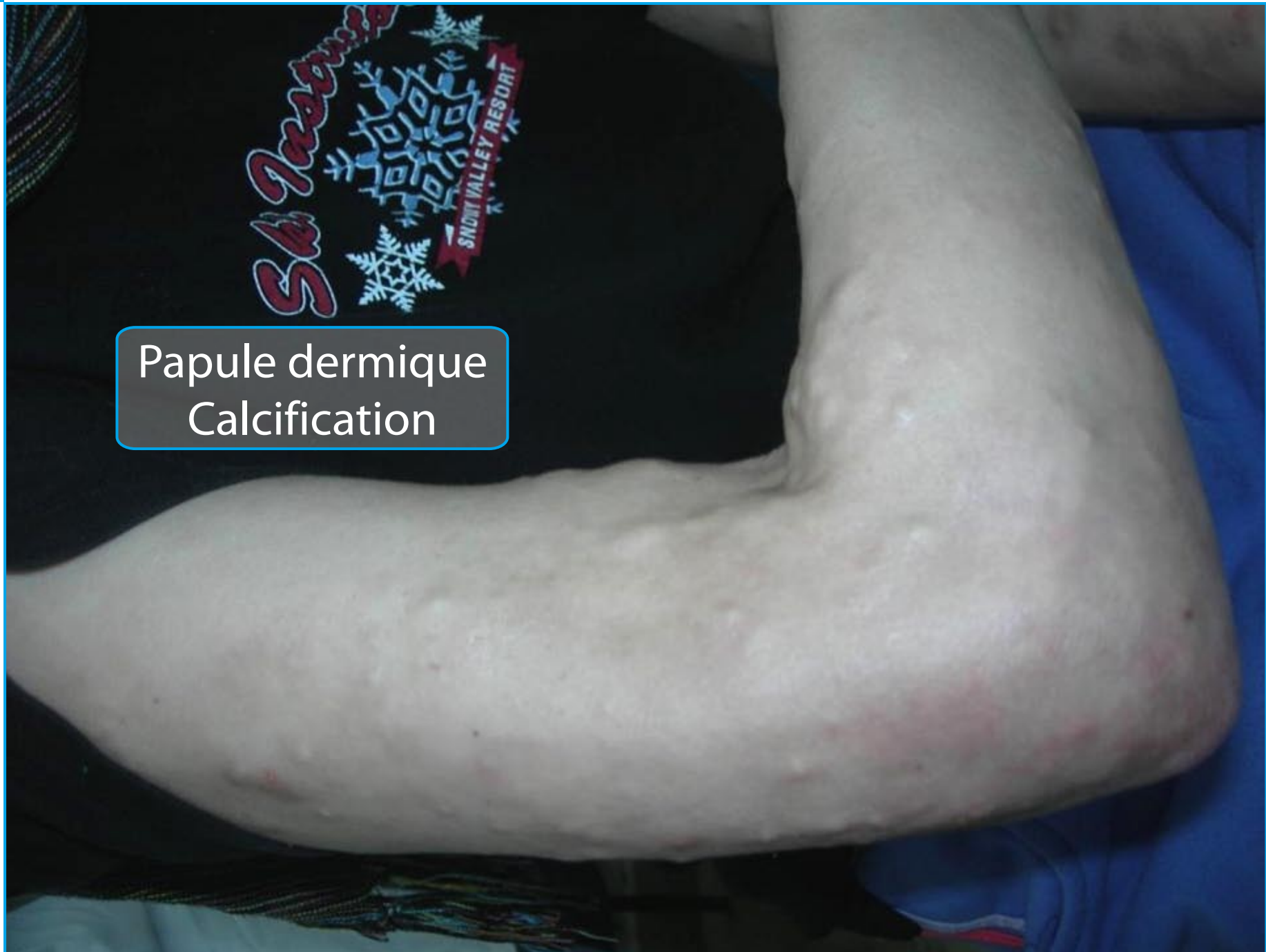Papule
dermique




Peau normale

Infiltrat de toute l'épaisseur
du derme

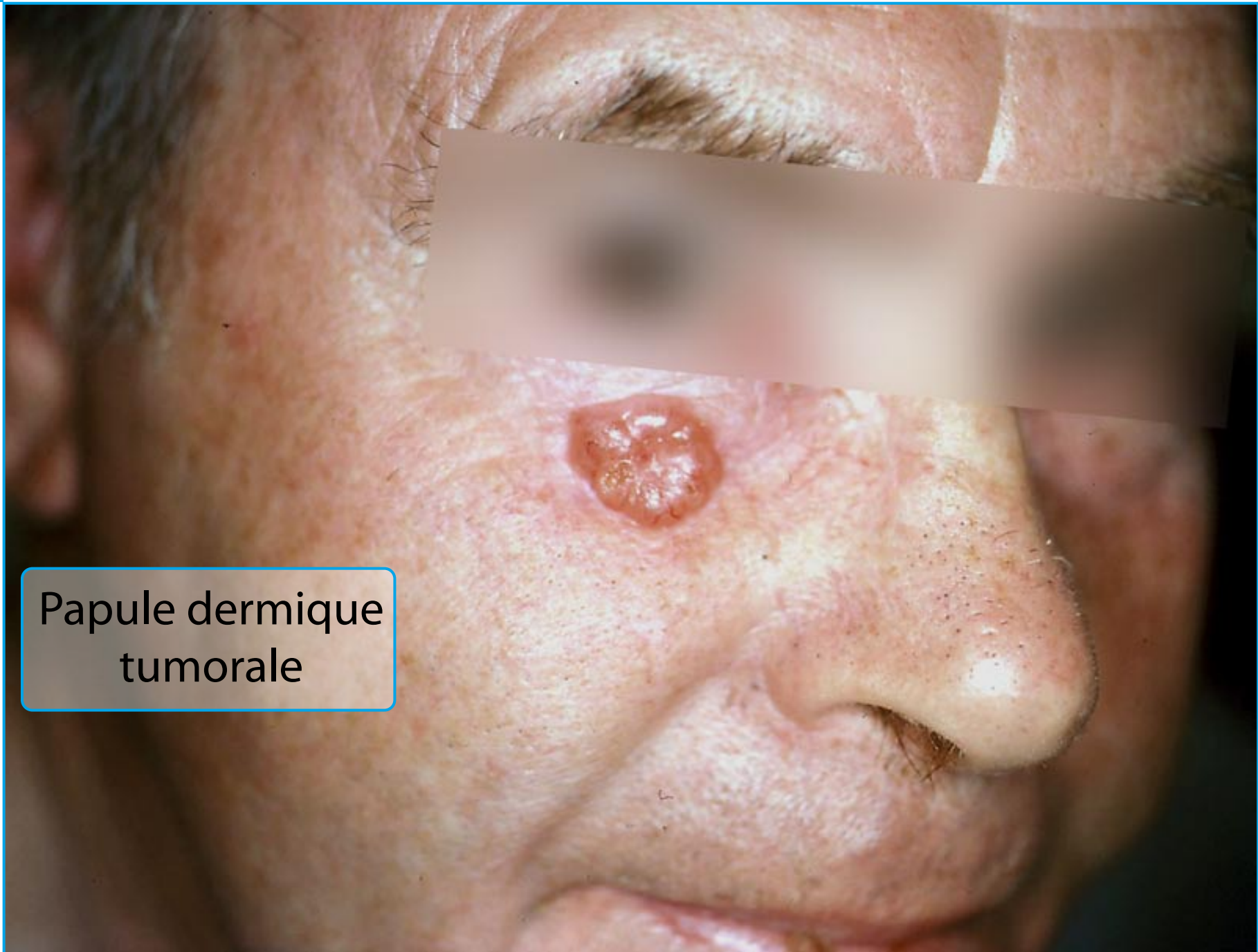Cellules épithéloïdes
et giganto cellulaires,
lymphocytes



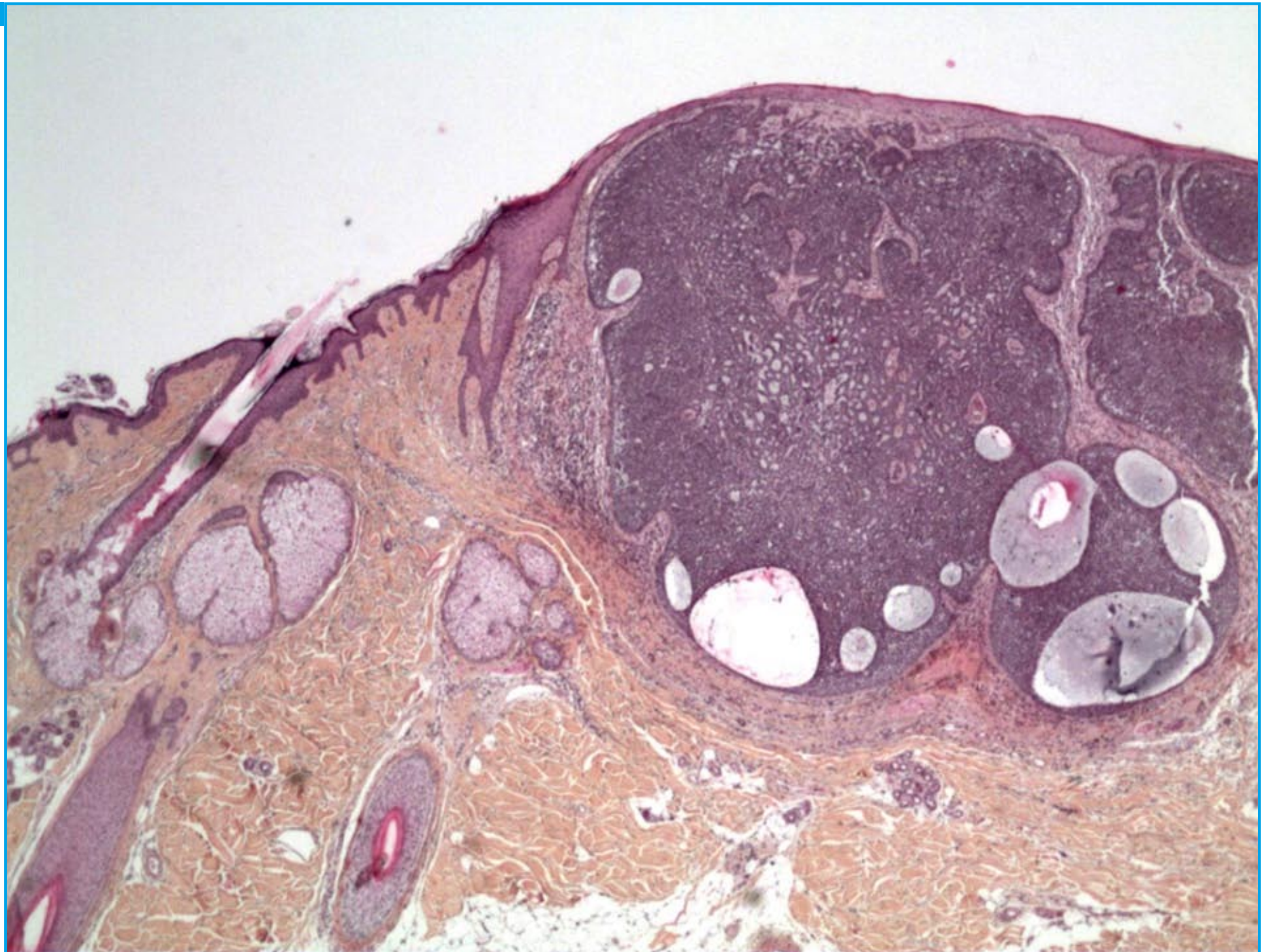
Papule dermique
Calcification

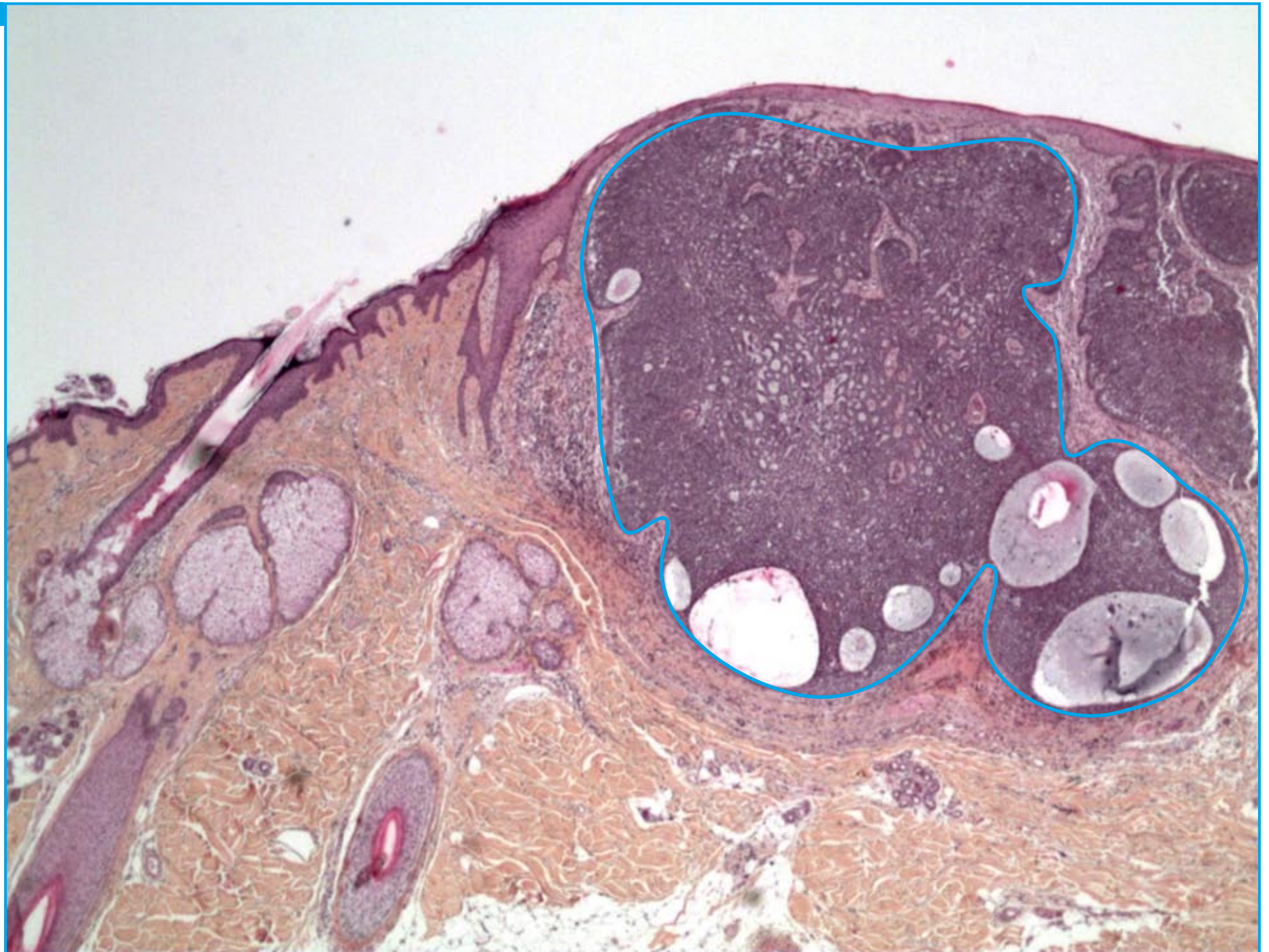


Calcifications

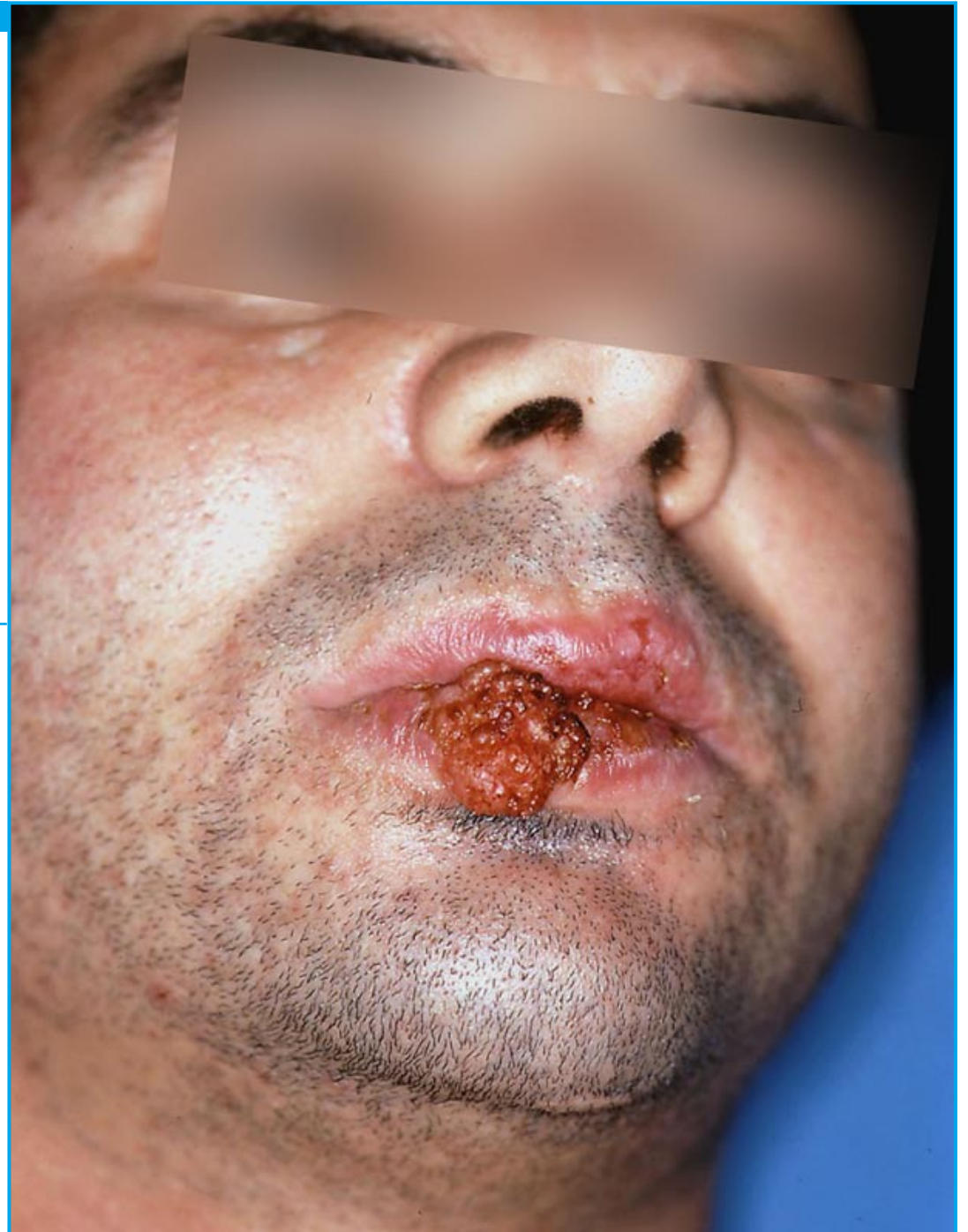

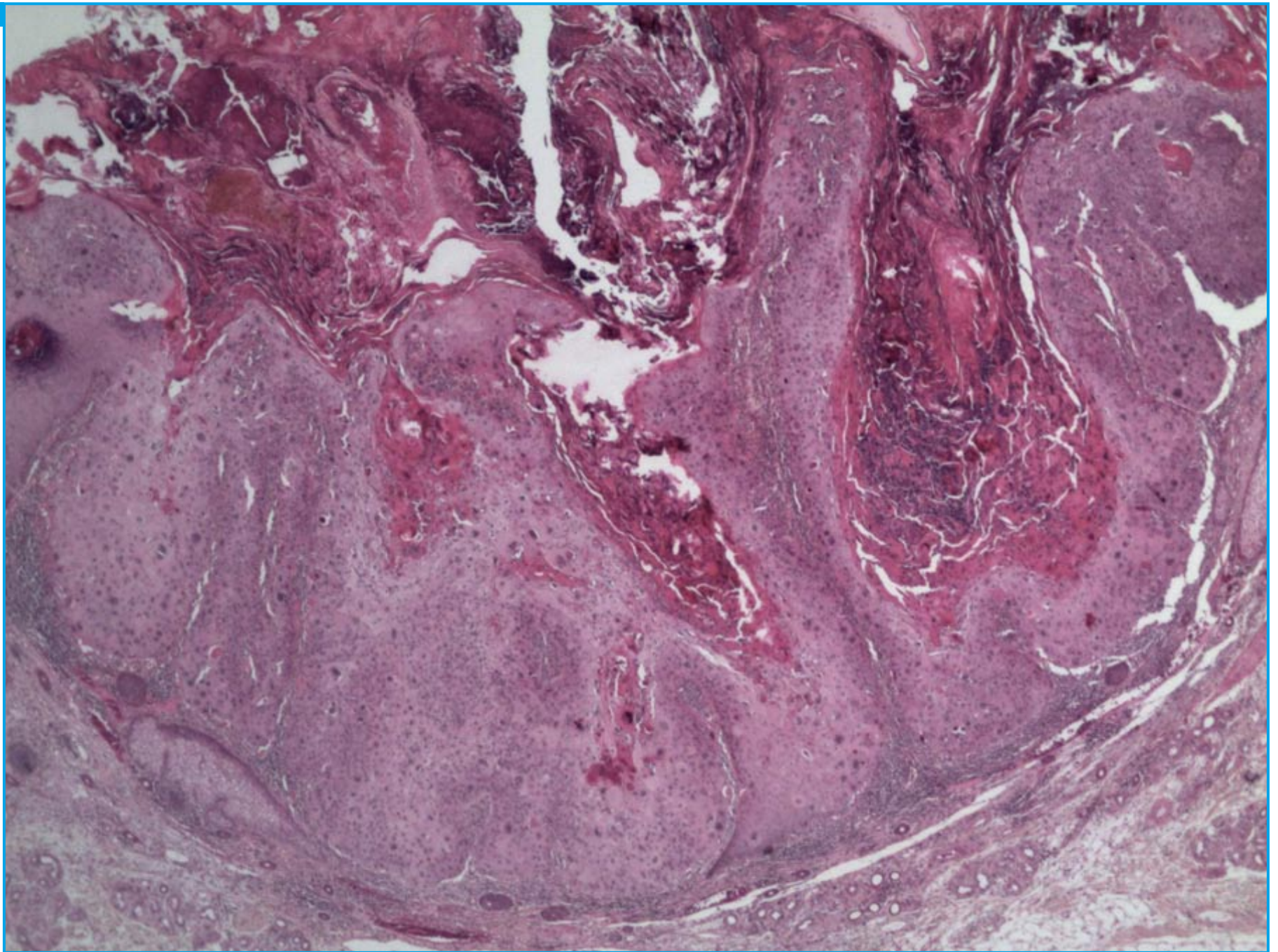
Papule dermique tumorale

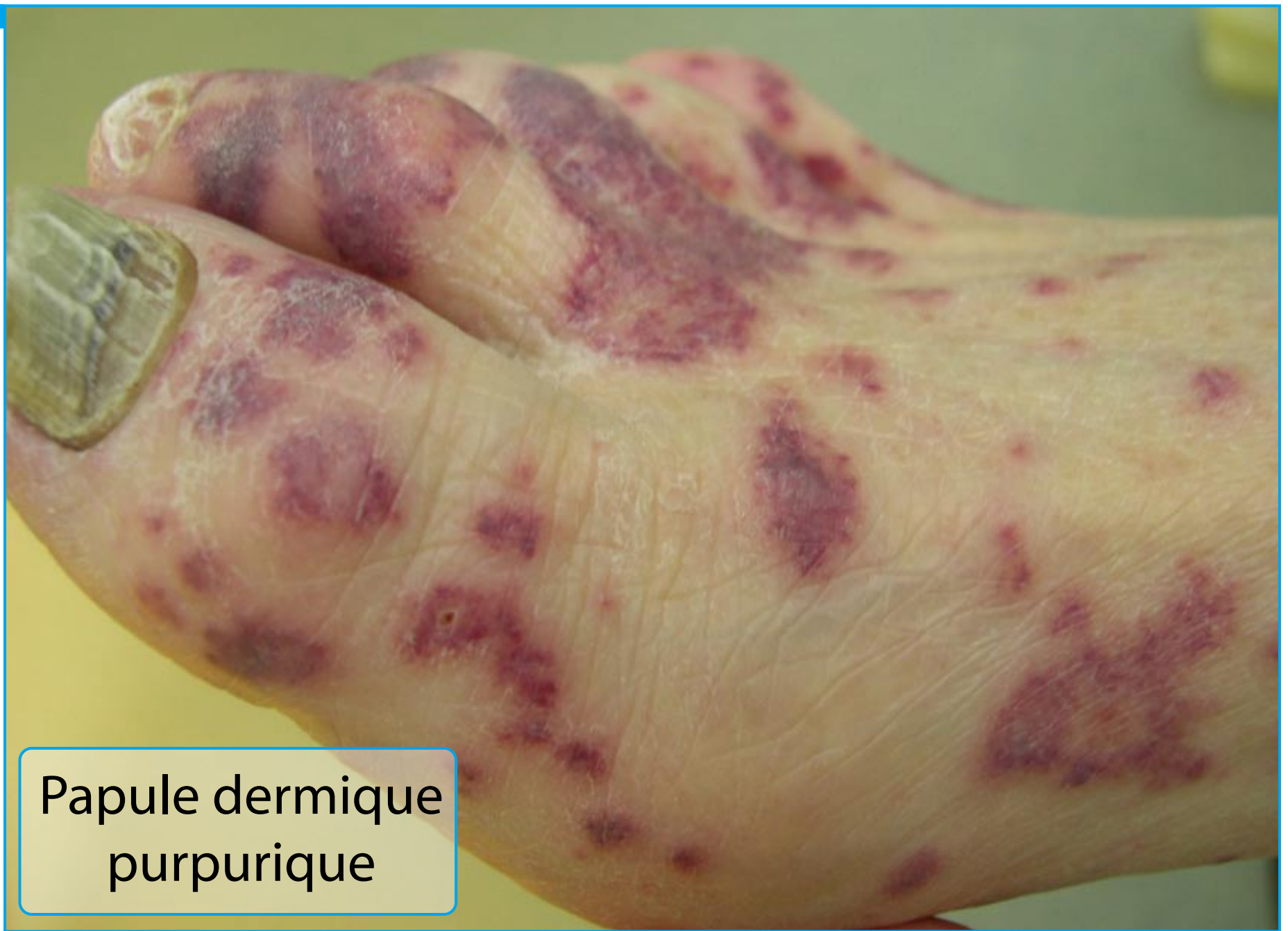




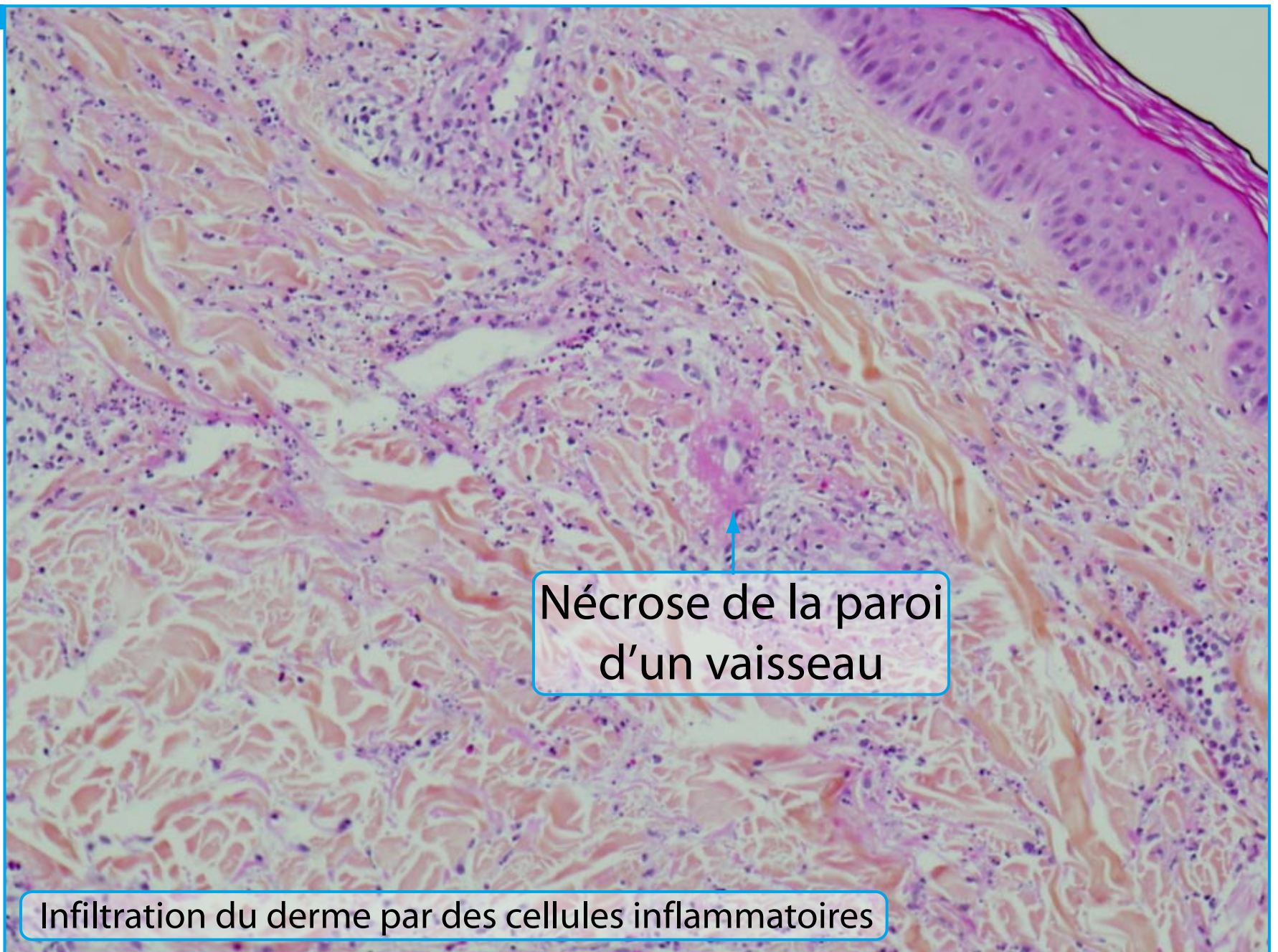
■ Papule tumorale







Papule dermique
purpurique

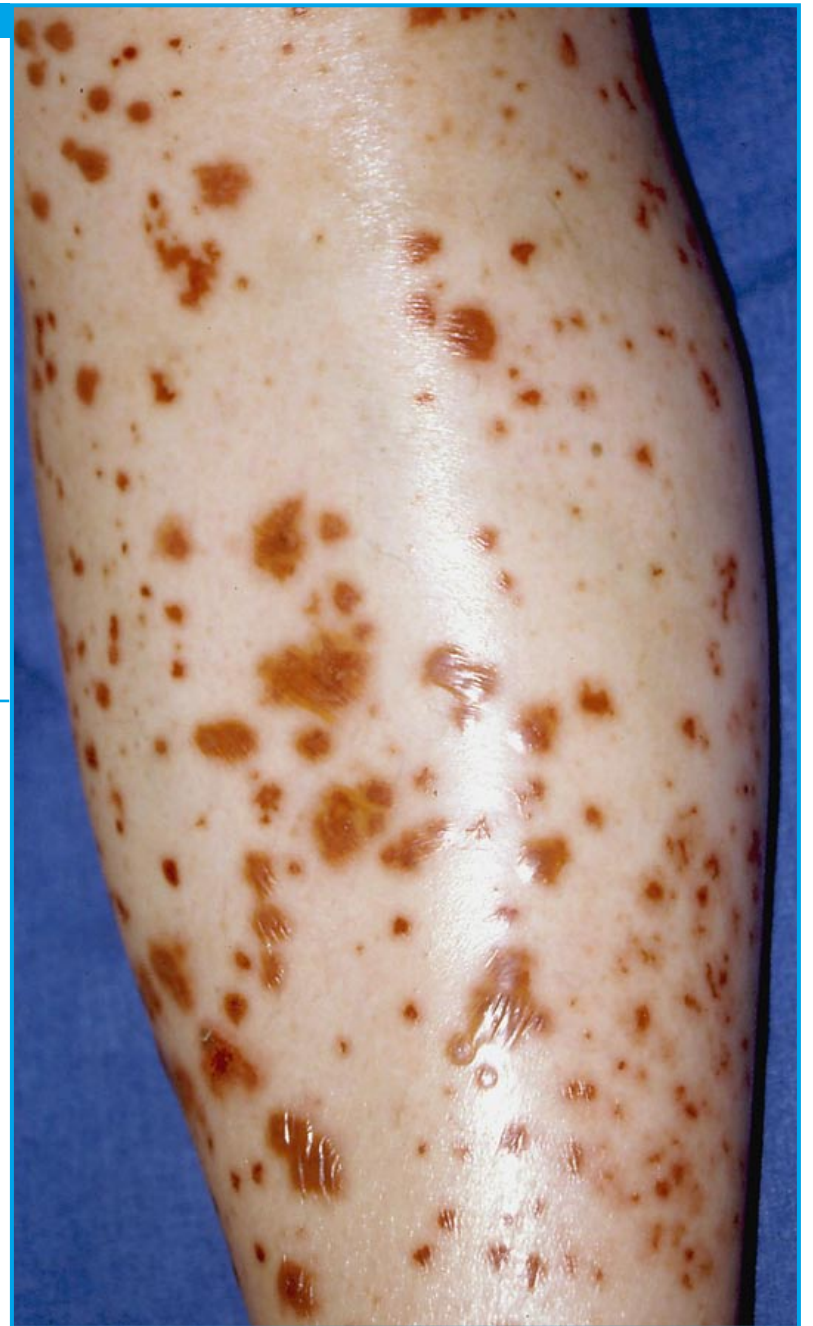

Nécrose de la paroi
d'un vaisseau

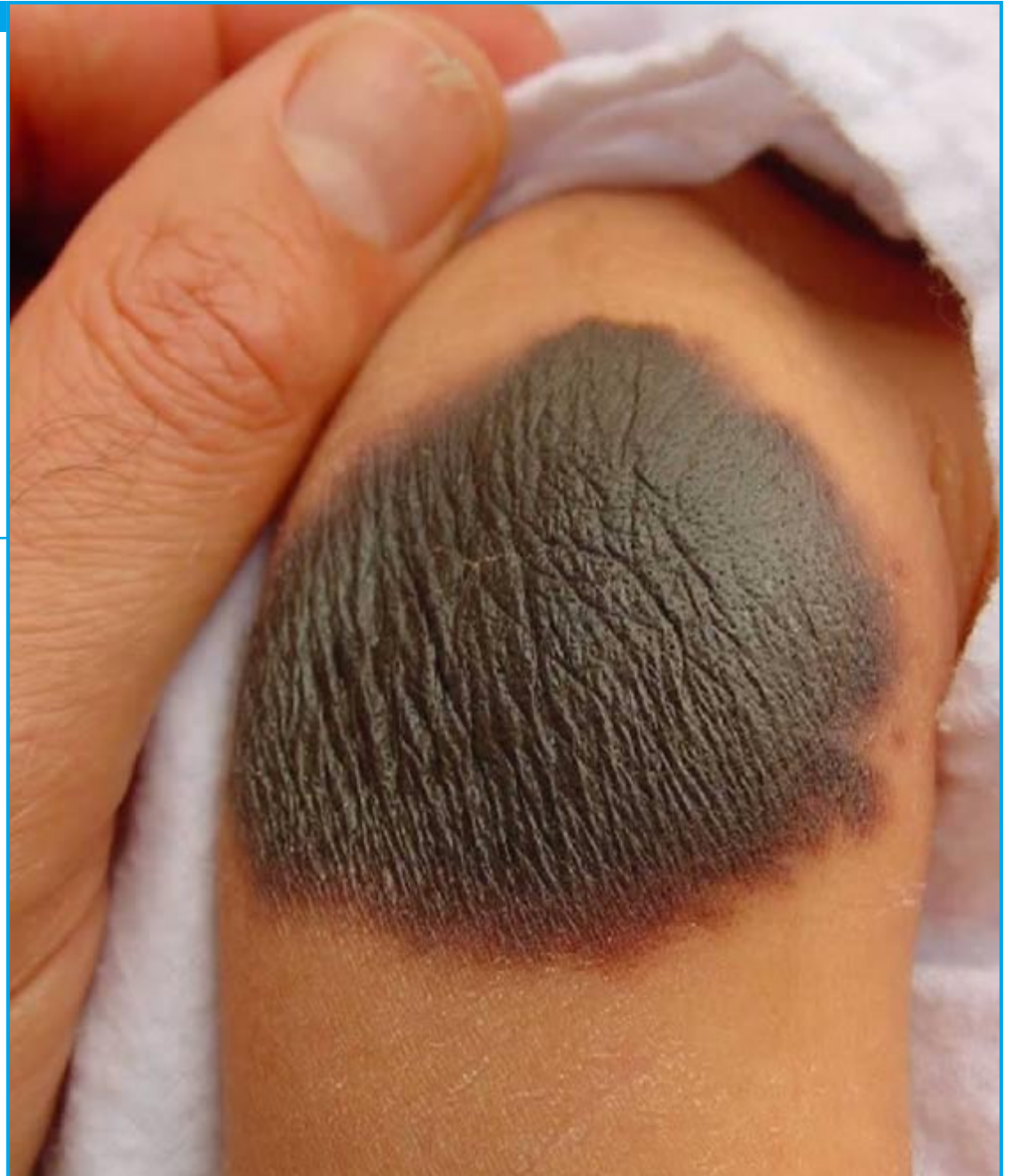Infiltration du derme par des cellules inflammatoires

■ Papule dermique
purpurique

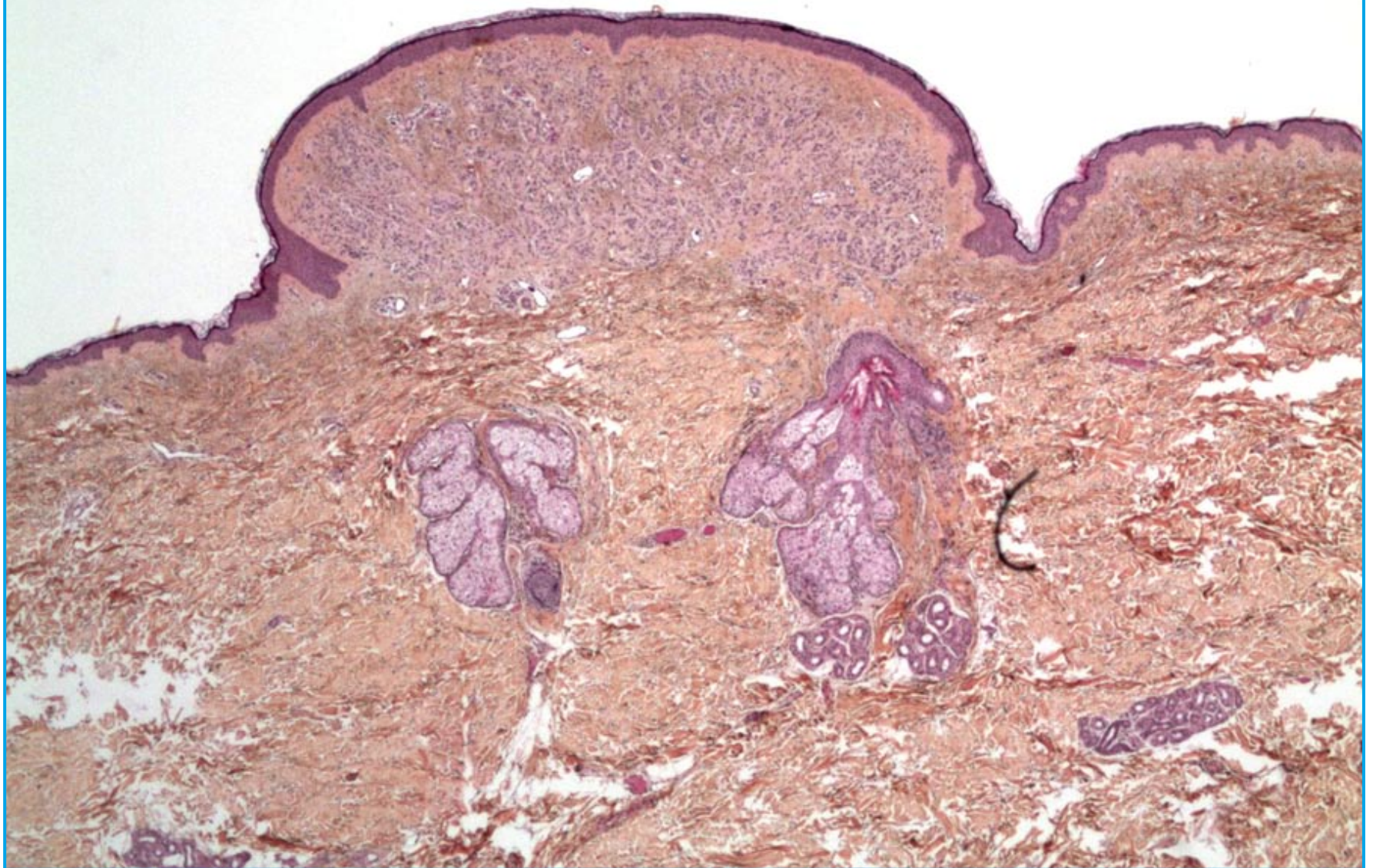
Couleur
de la biligénie

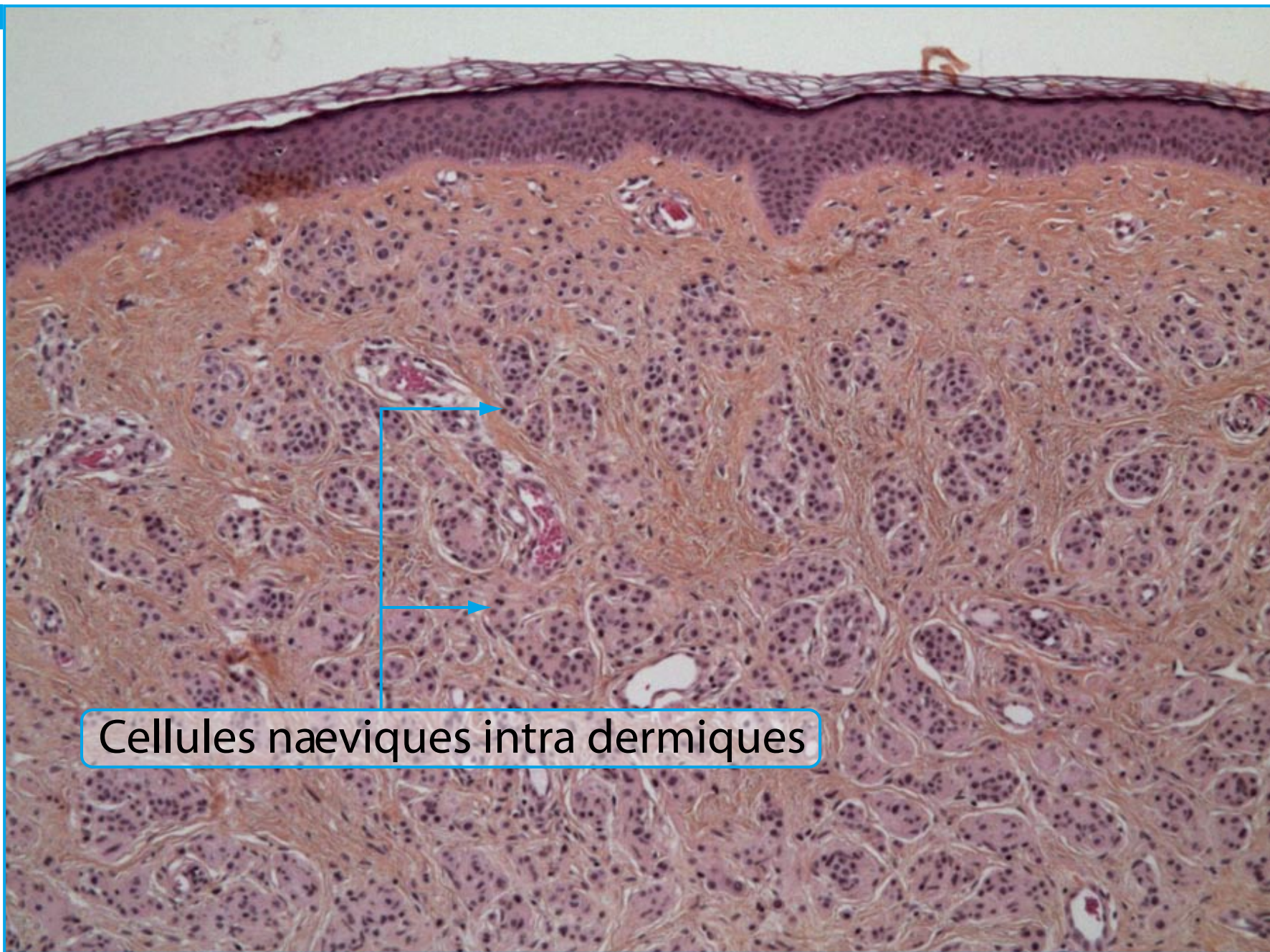


■ Papule dermique pigmentée

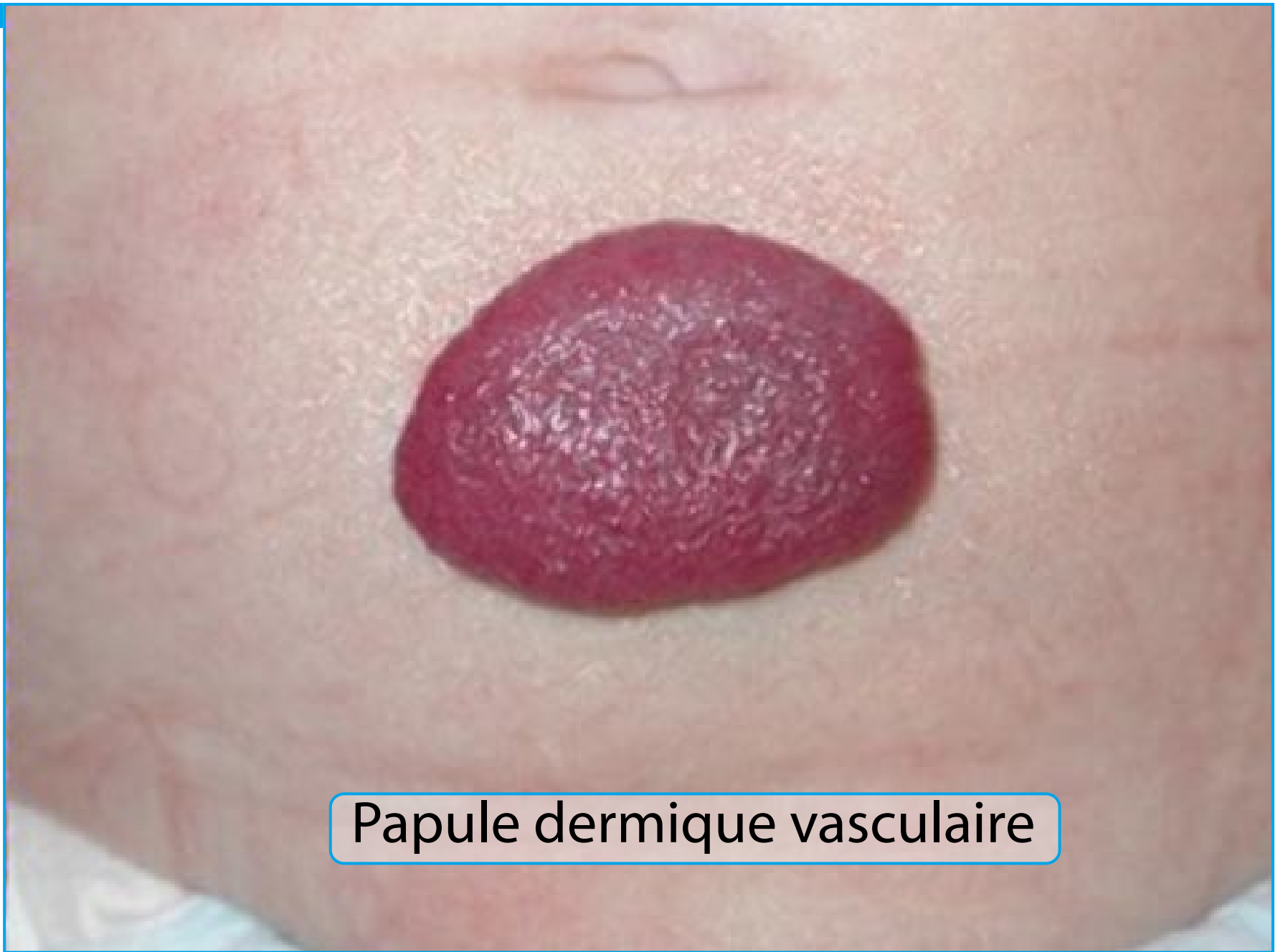

Cellules naeviques intra dermiques

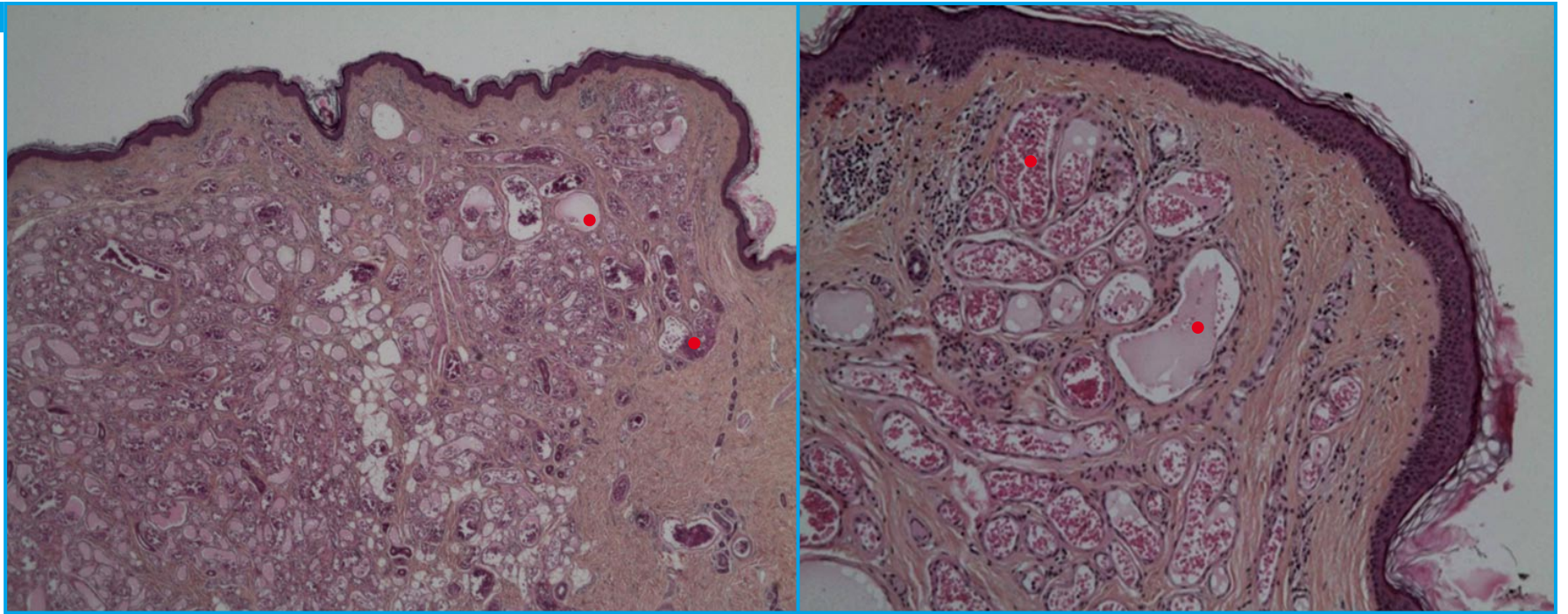




Cellules naeviques intra dermiques

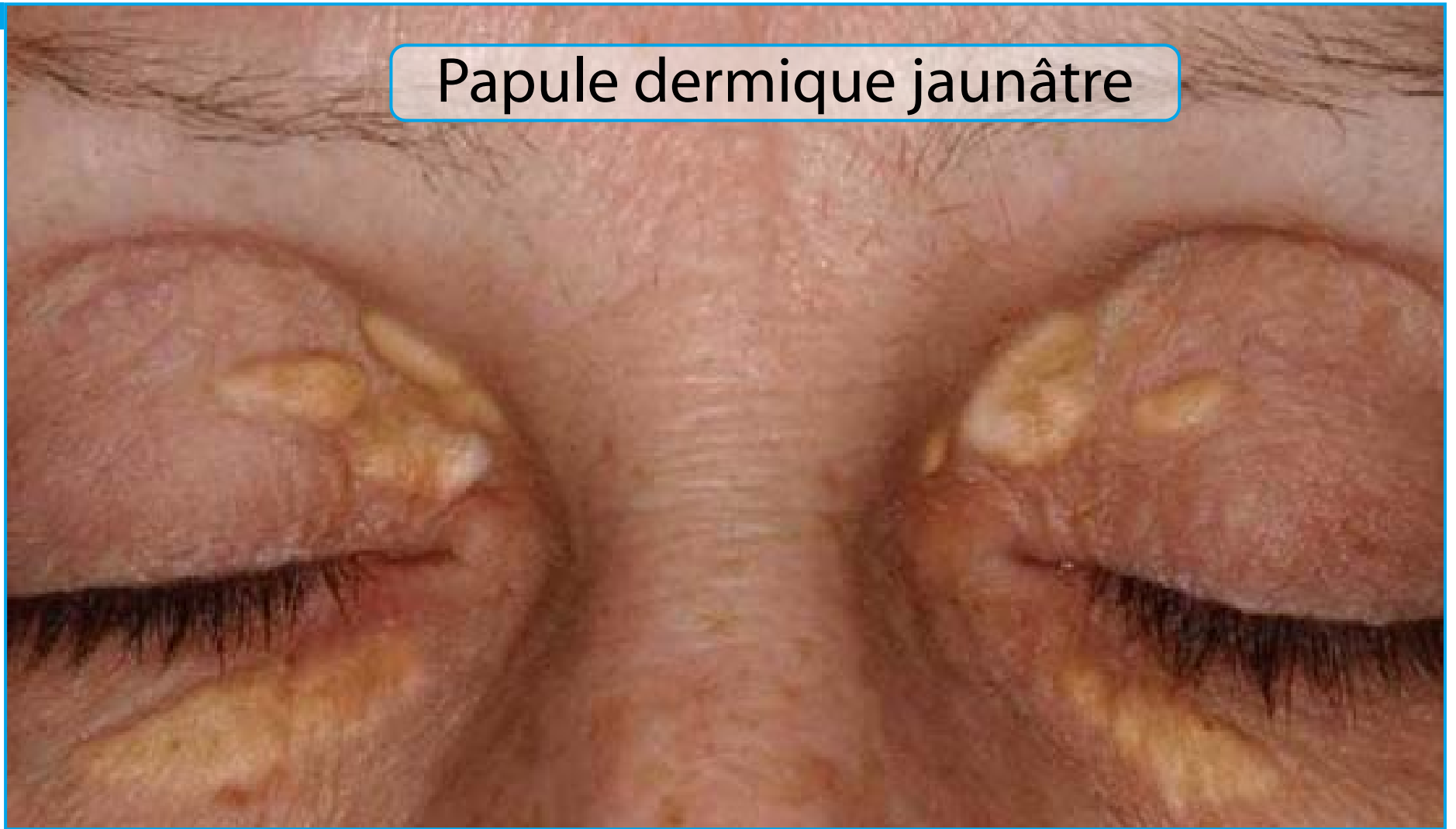


Papule dermique vasculaire

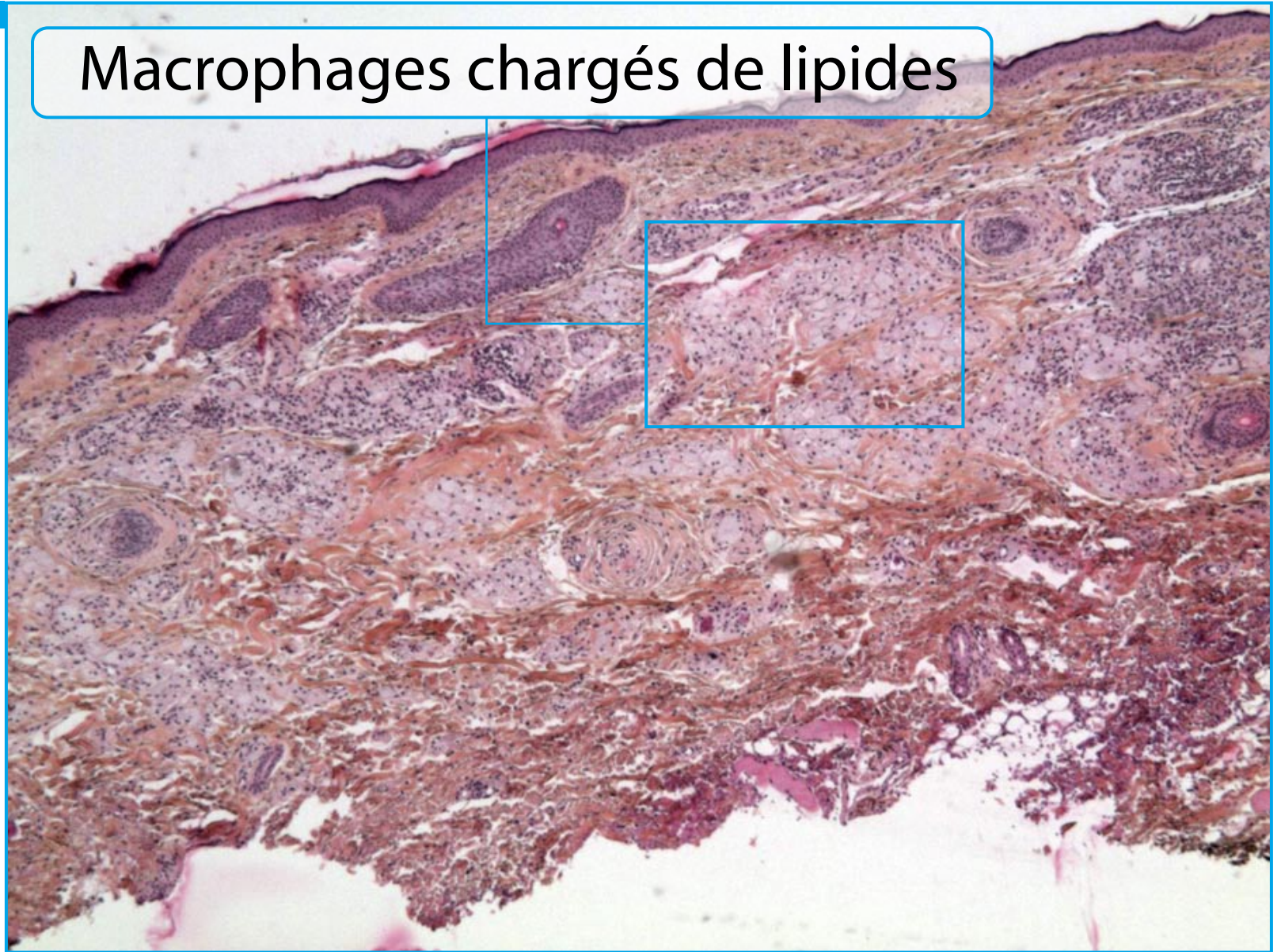


- ▶ Très nombreuses cavités vasculaires dans le derme •

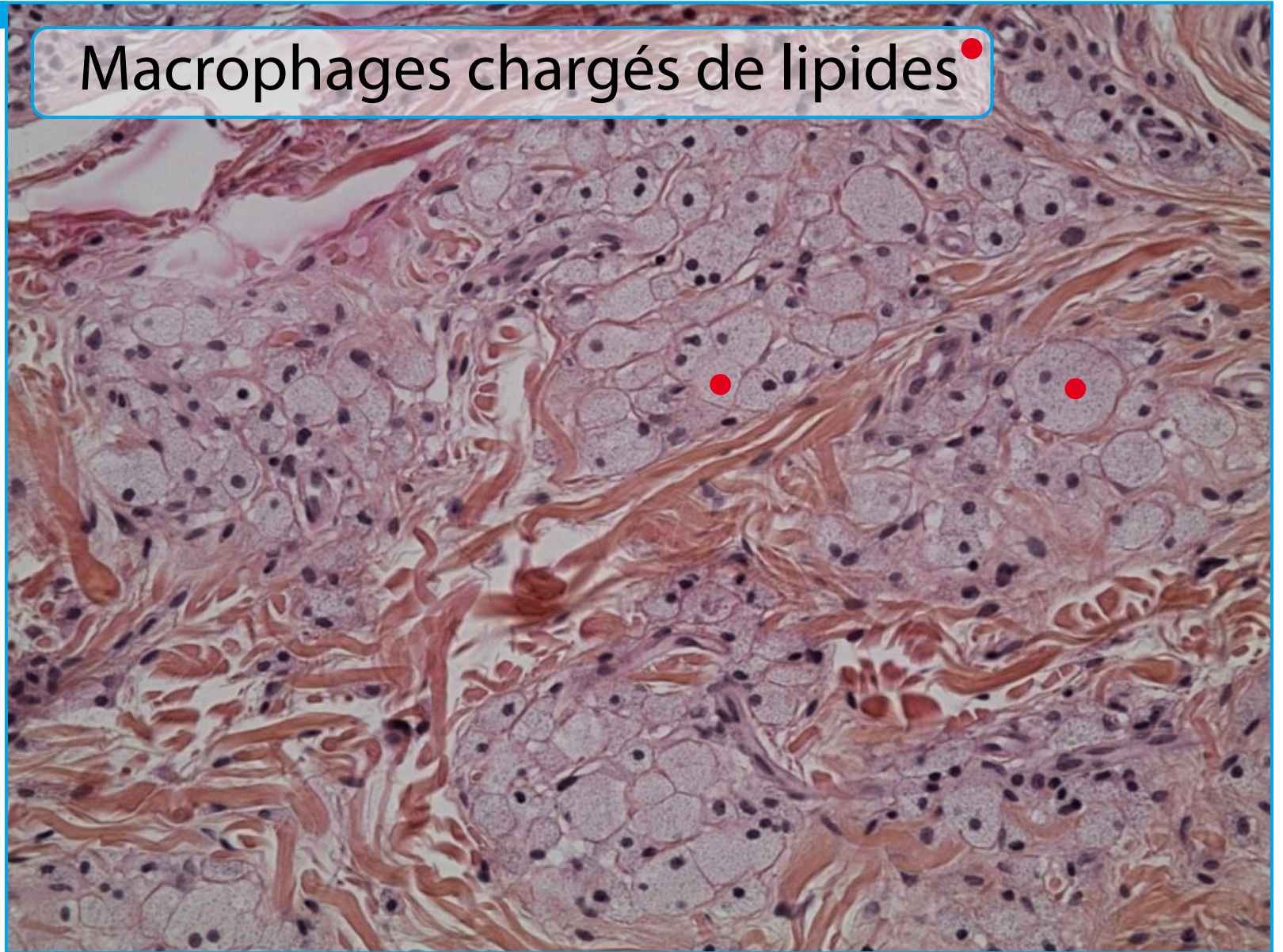
Papule dermique jaunâtre



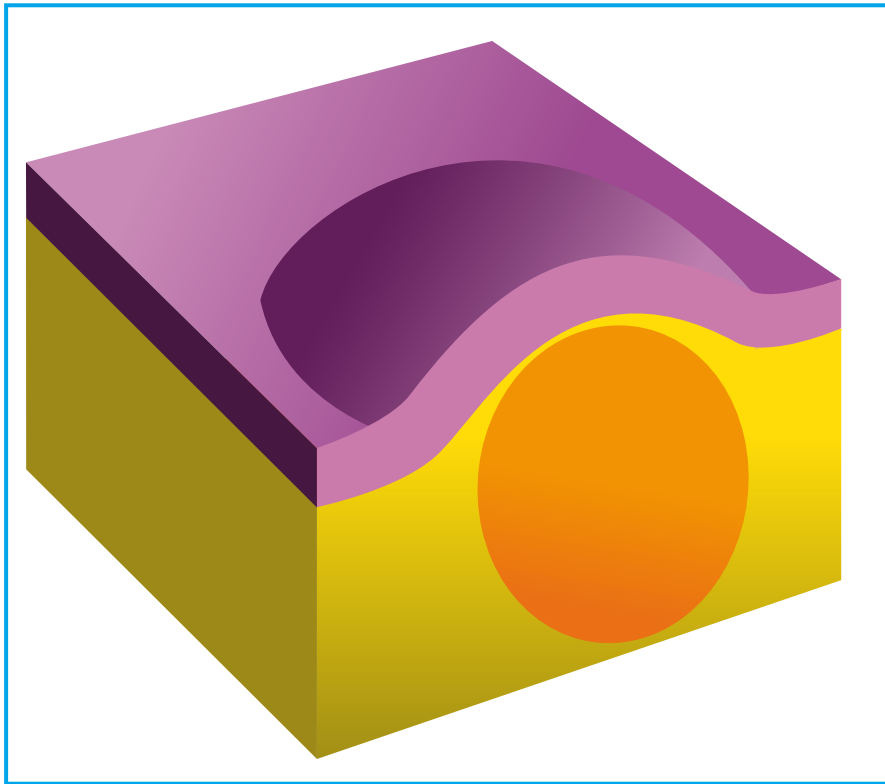
Macrophages chargés de lipides




Macrophages chargés de lipides



Lésion palpable tissulaire vs liquidienne

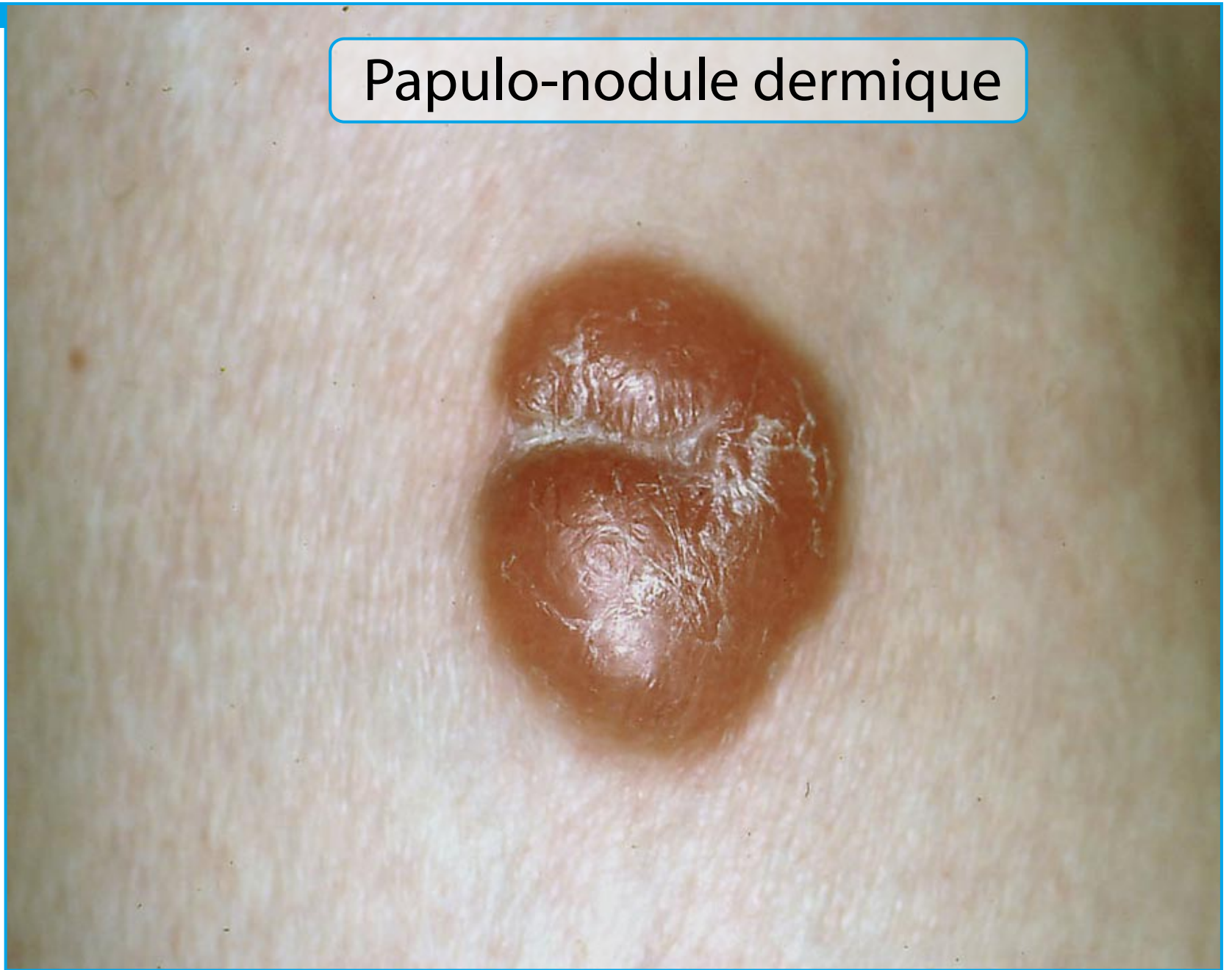

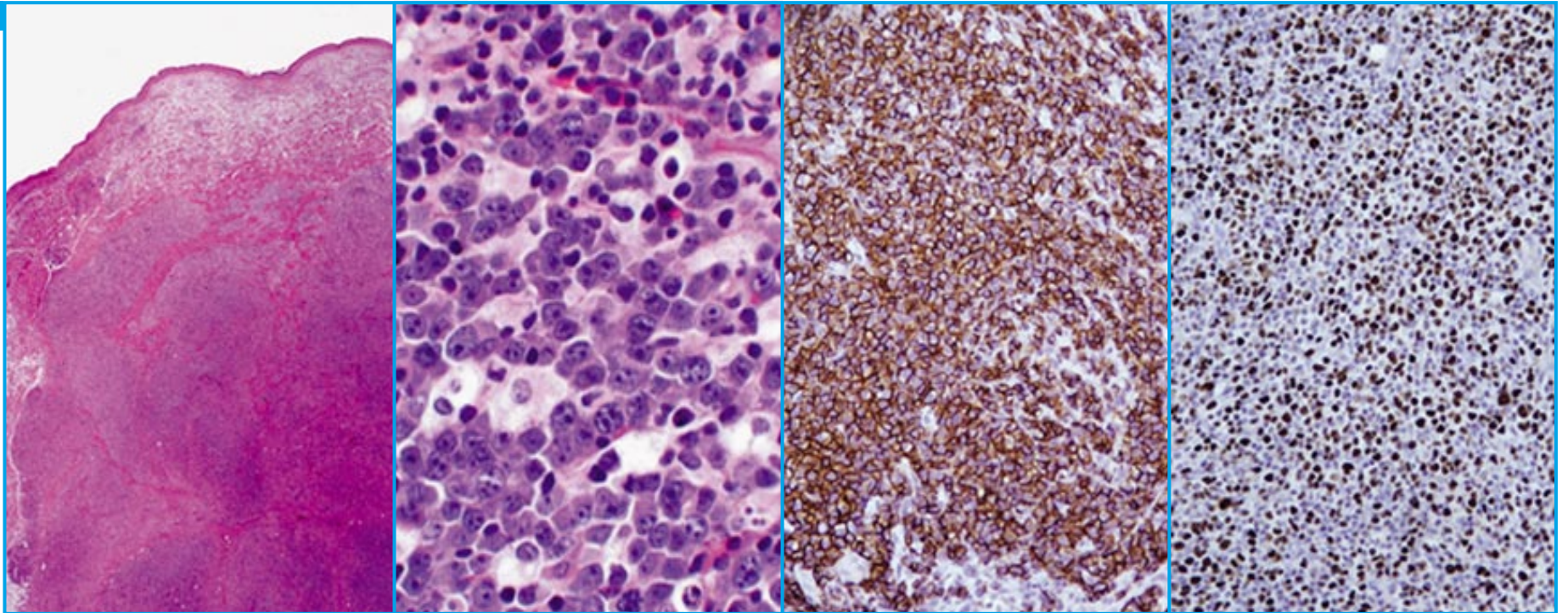
Nodule



Kyste

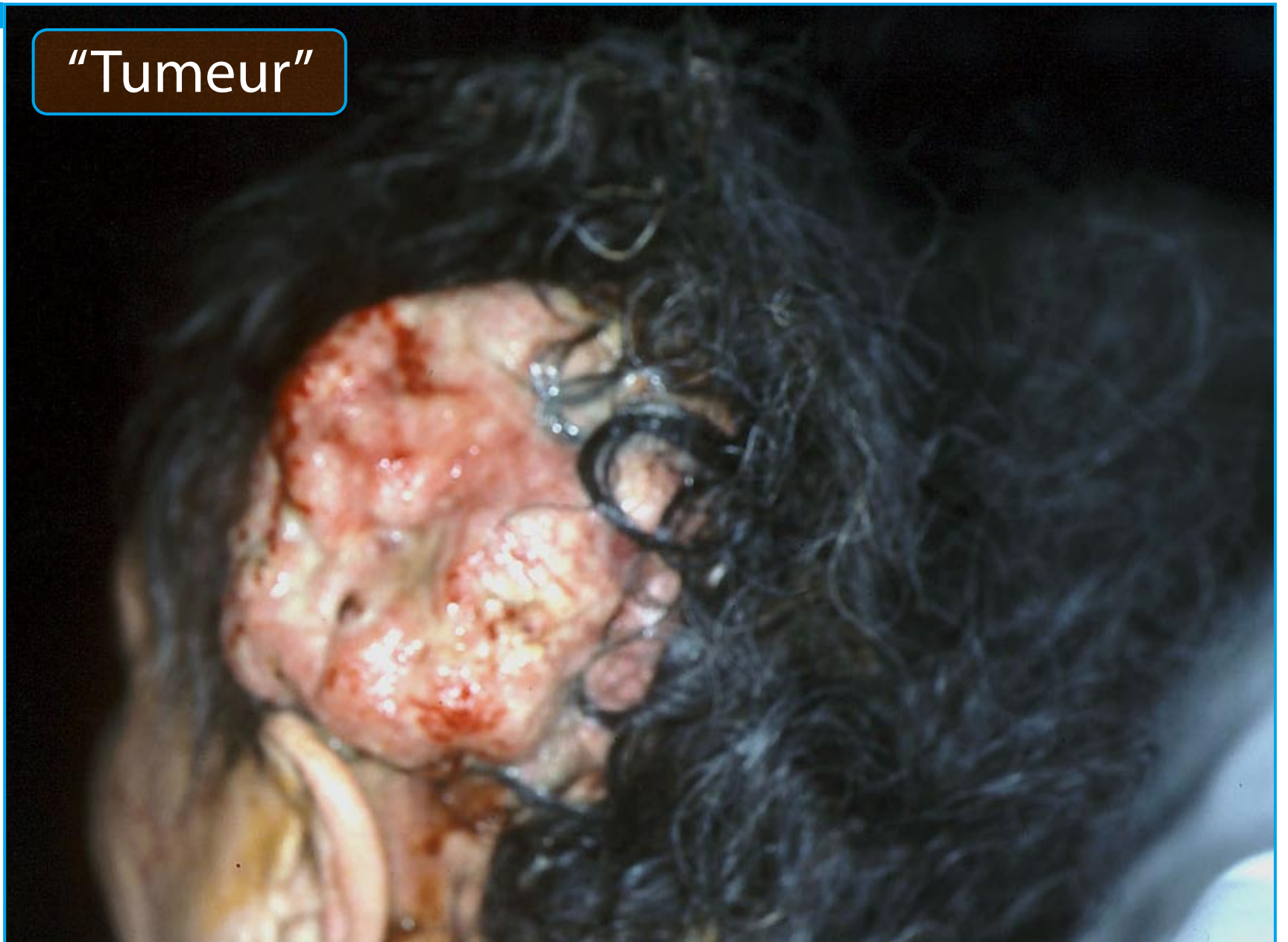Papulo-nodule dermique



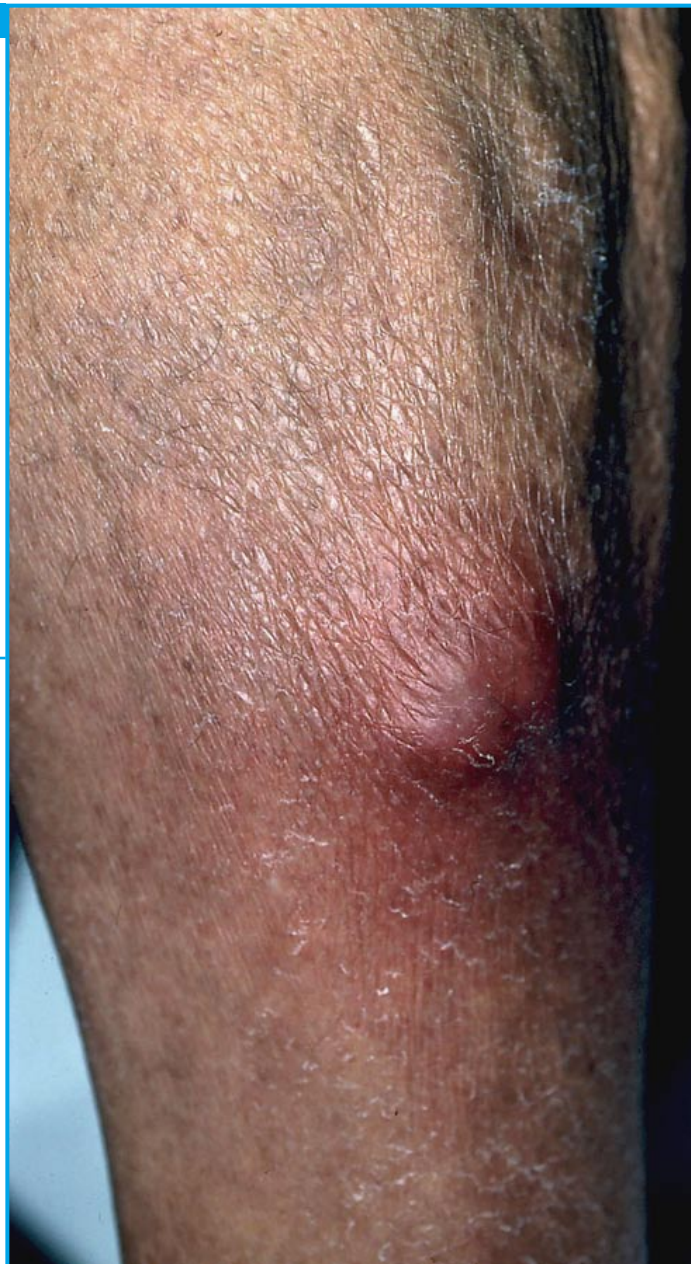

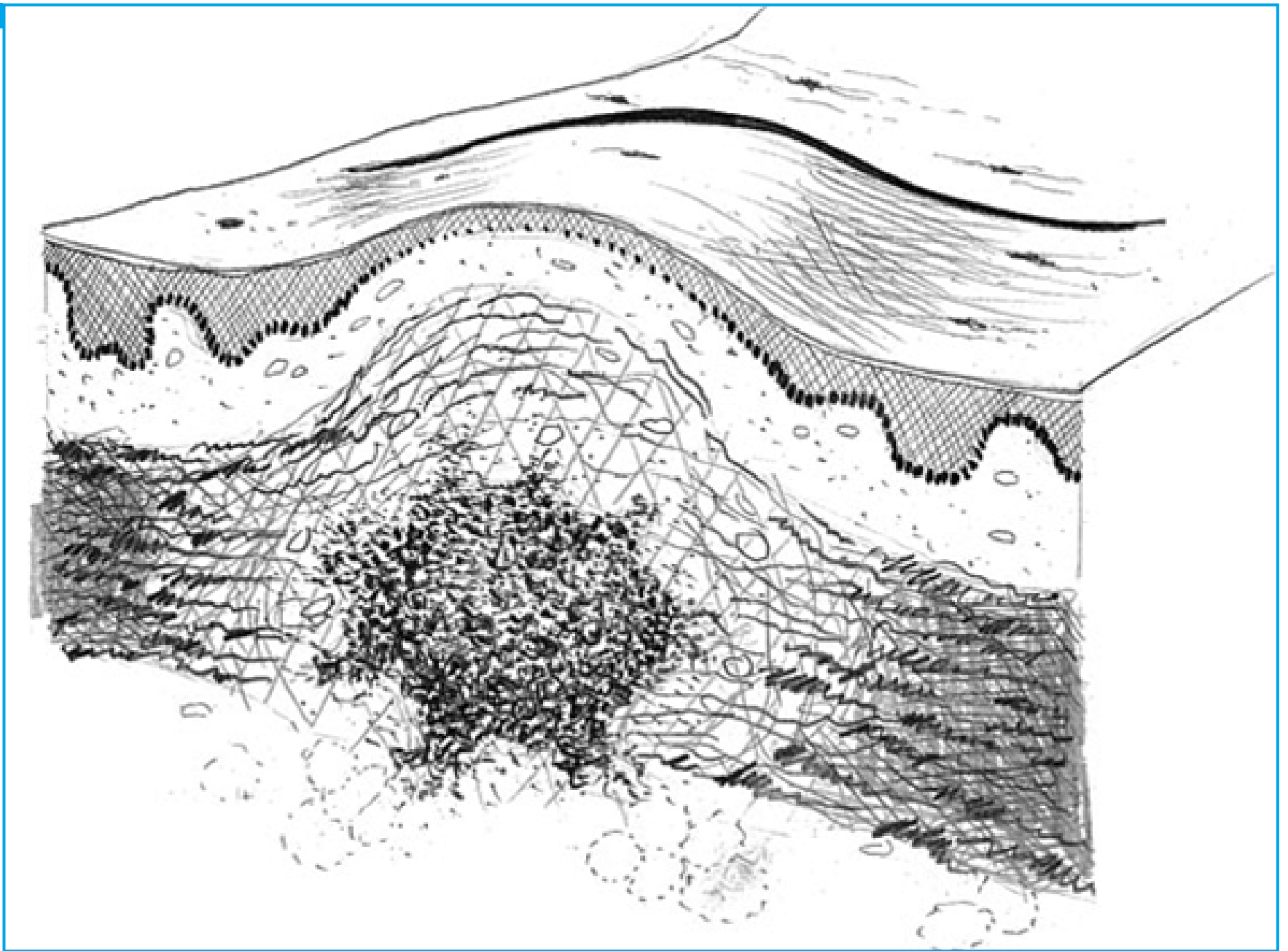
Copyright © 2009 Wolters Kluwer Health | Lippincott Williams & Wilkins

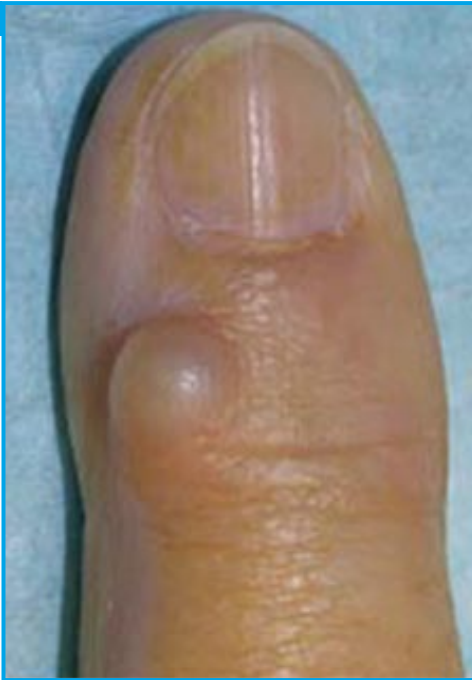“Tumeur”



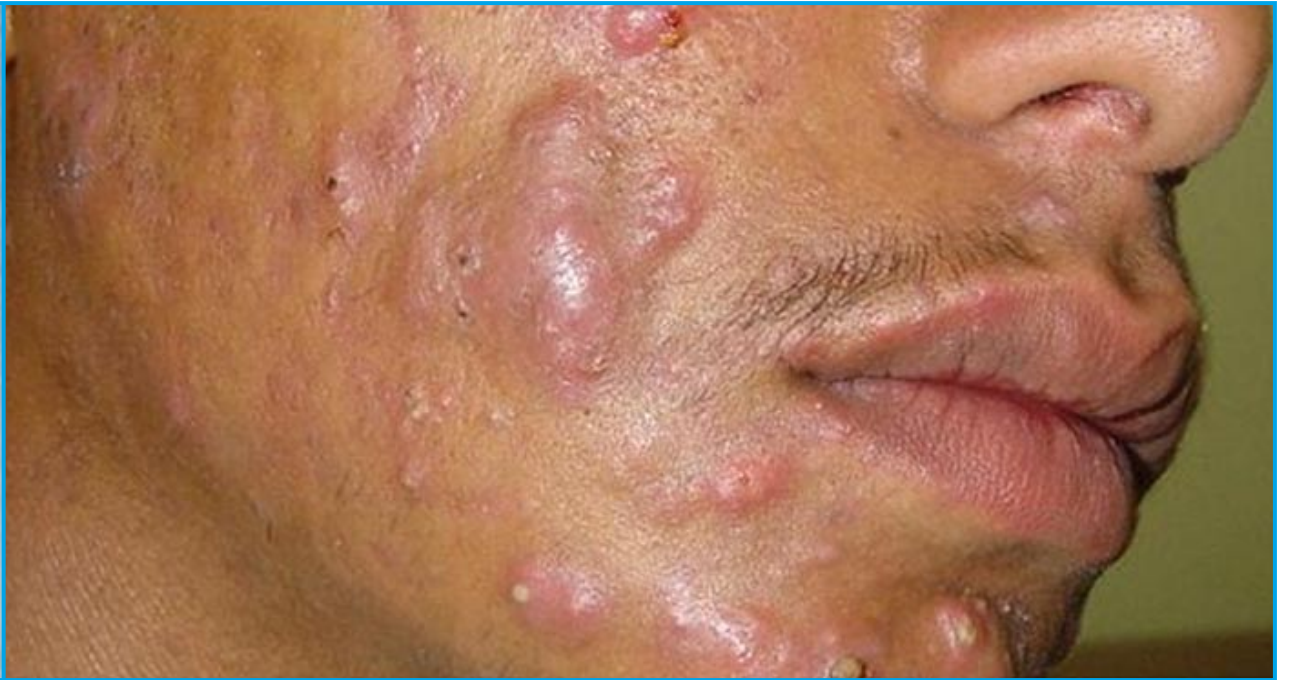■ Nodule fluctuant : abcès



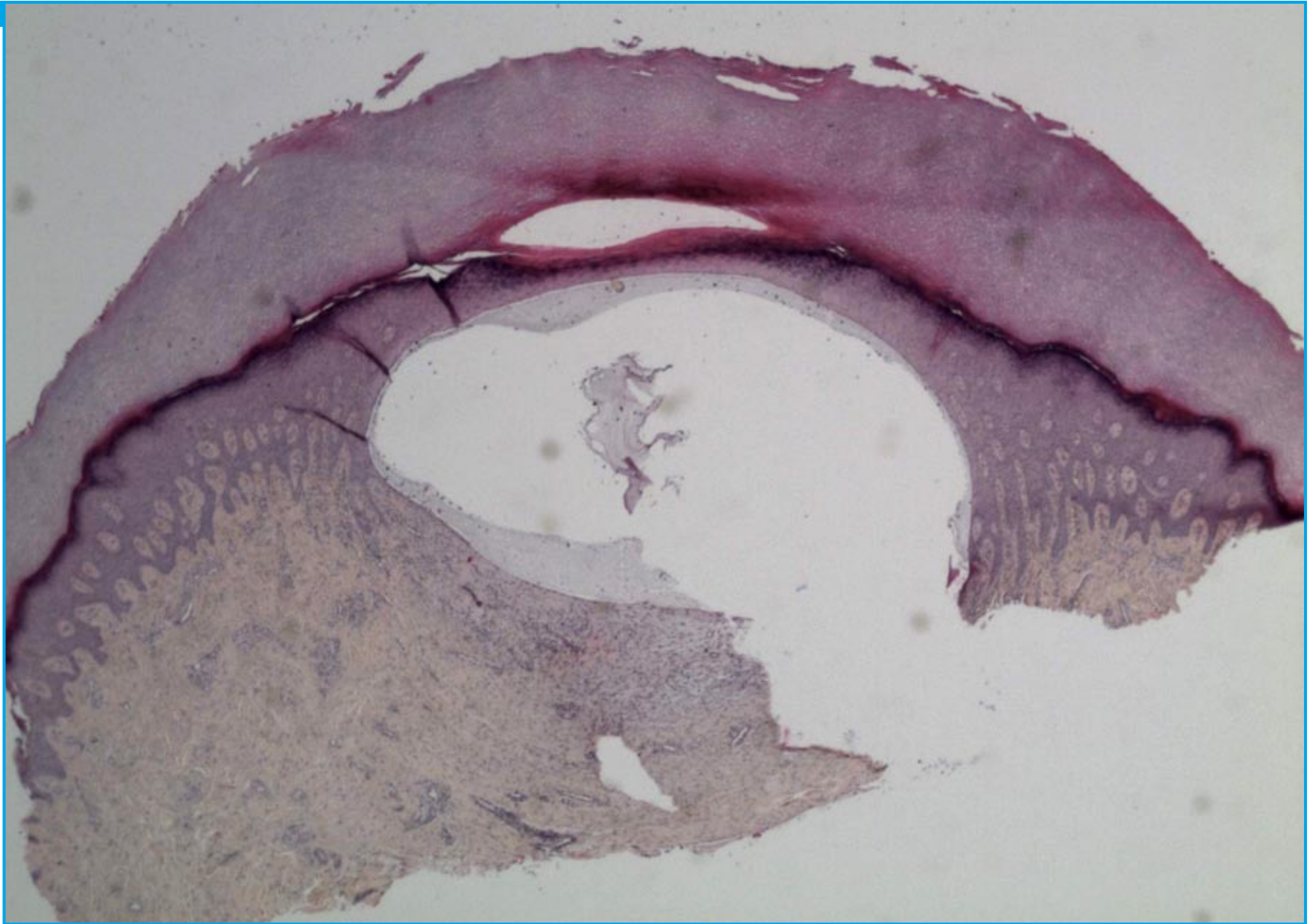




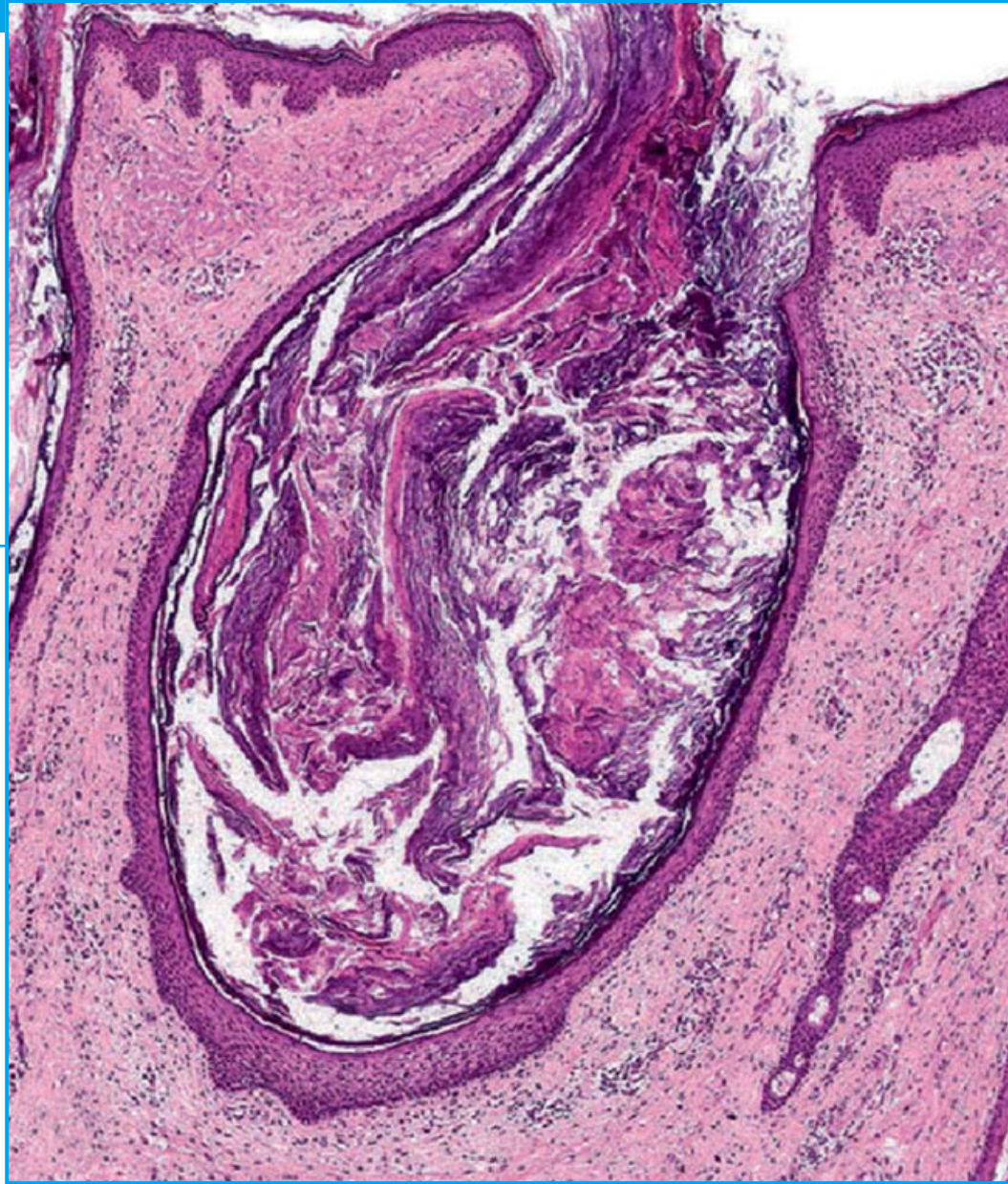
Kyste
liquidien



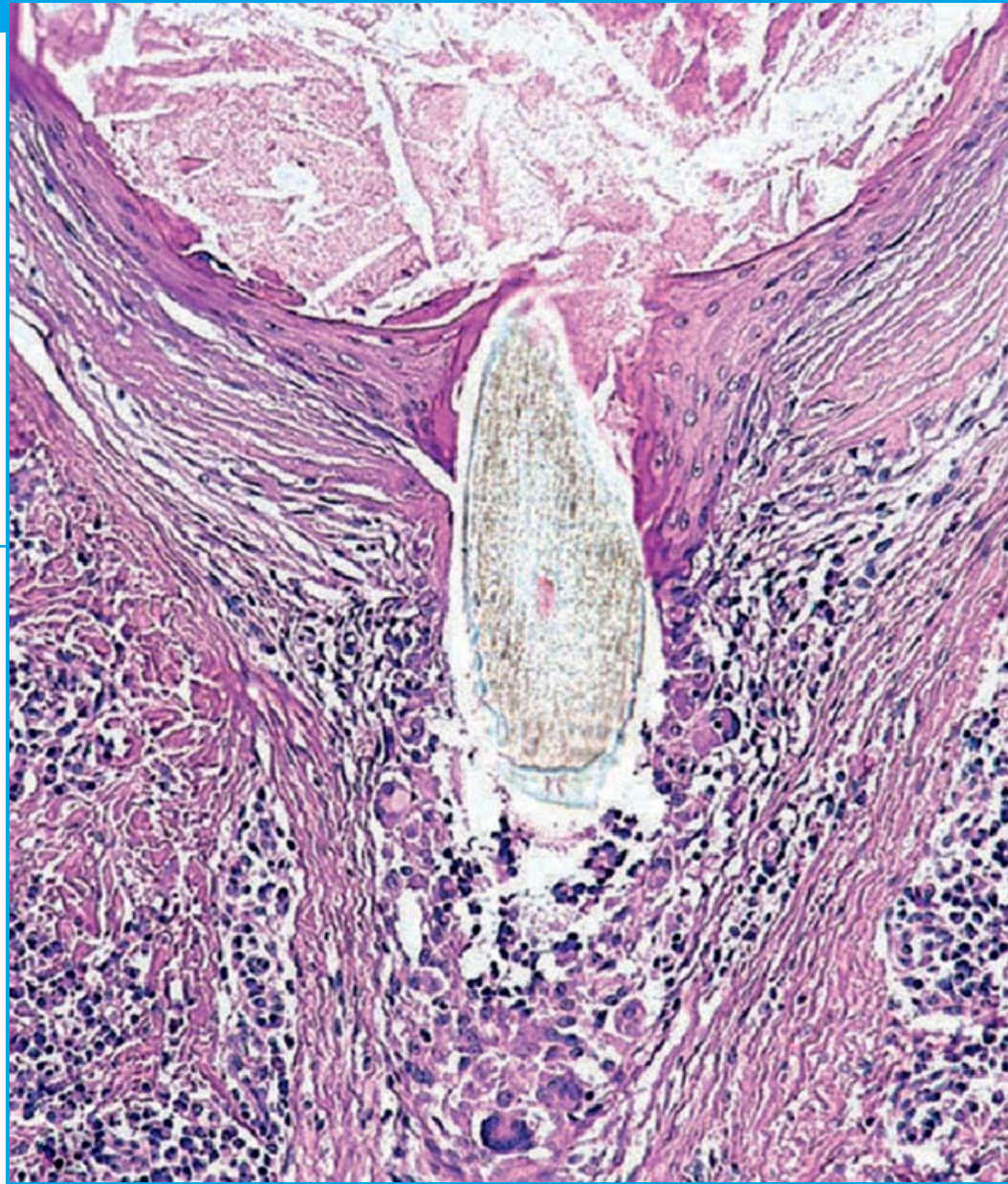
Kyste de contenu
solide



Acné

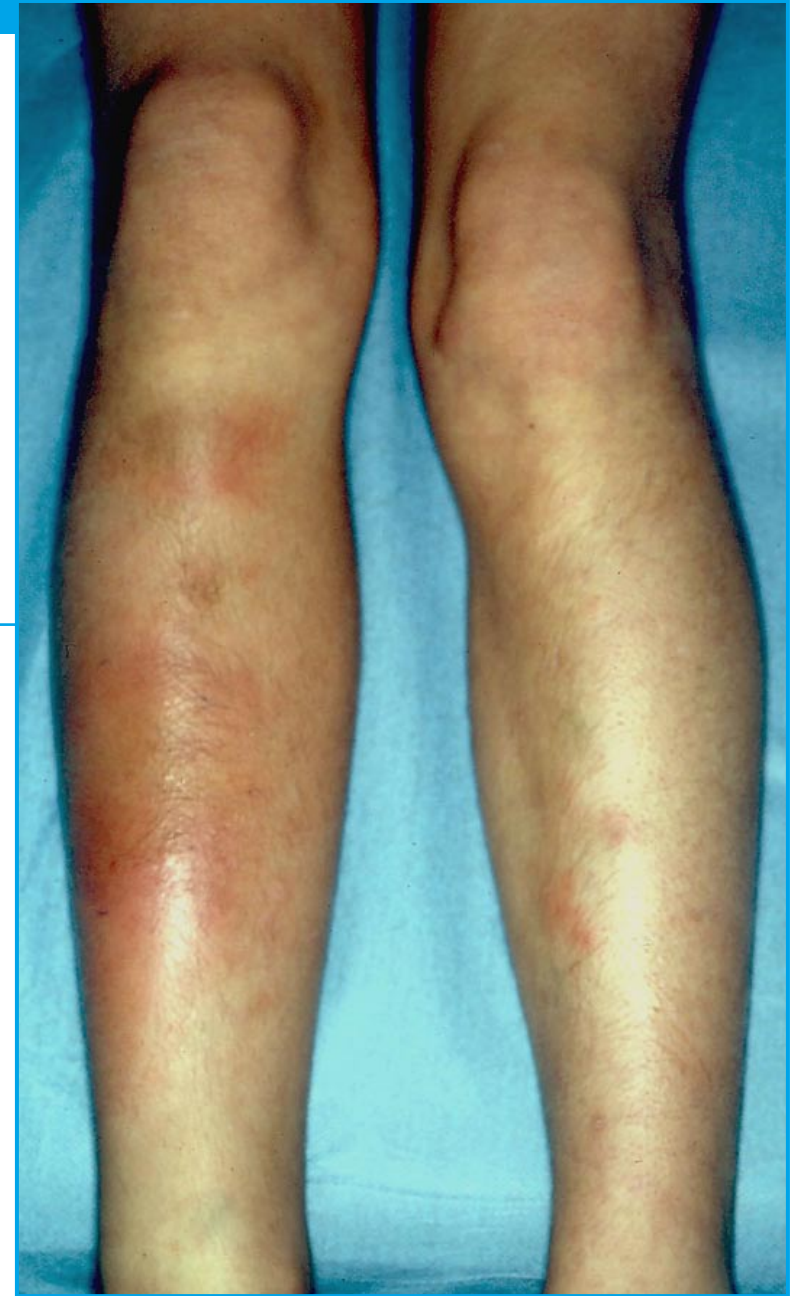

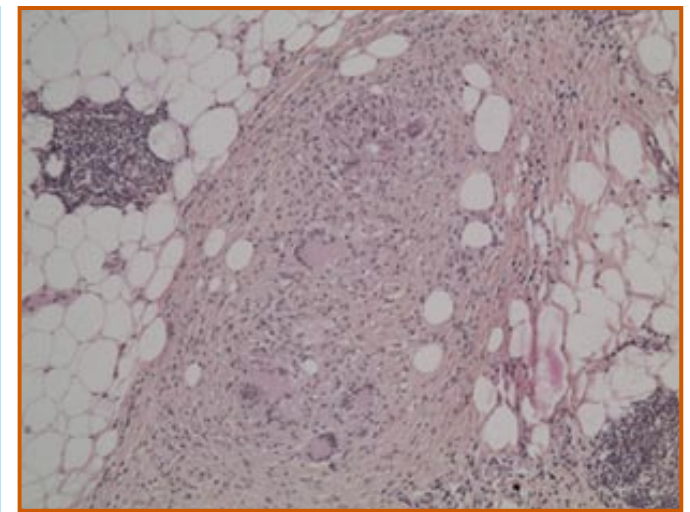
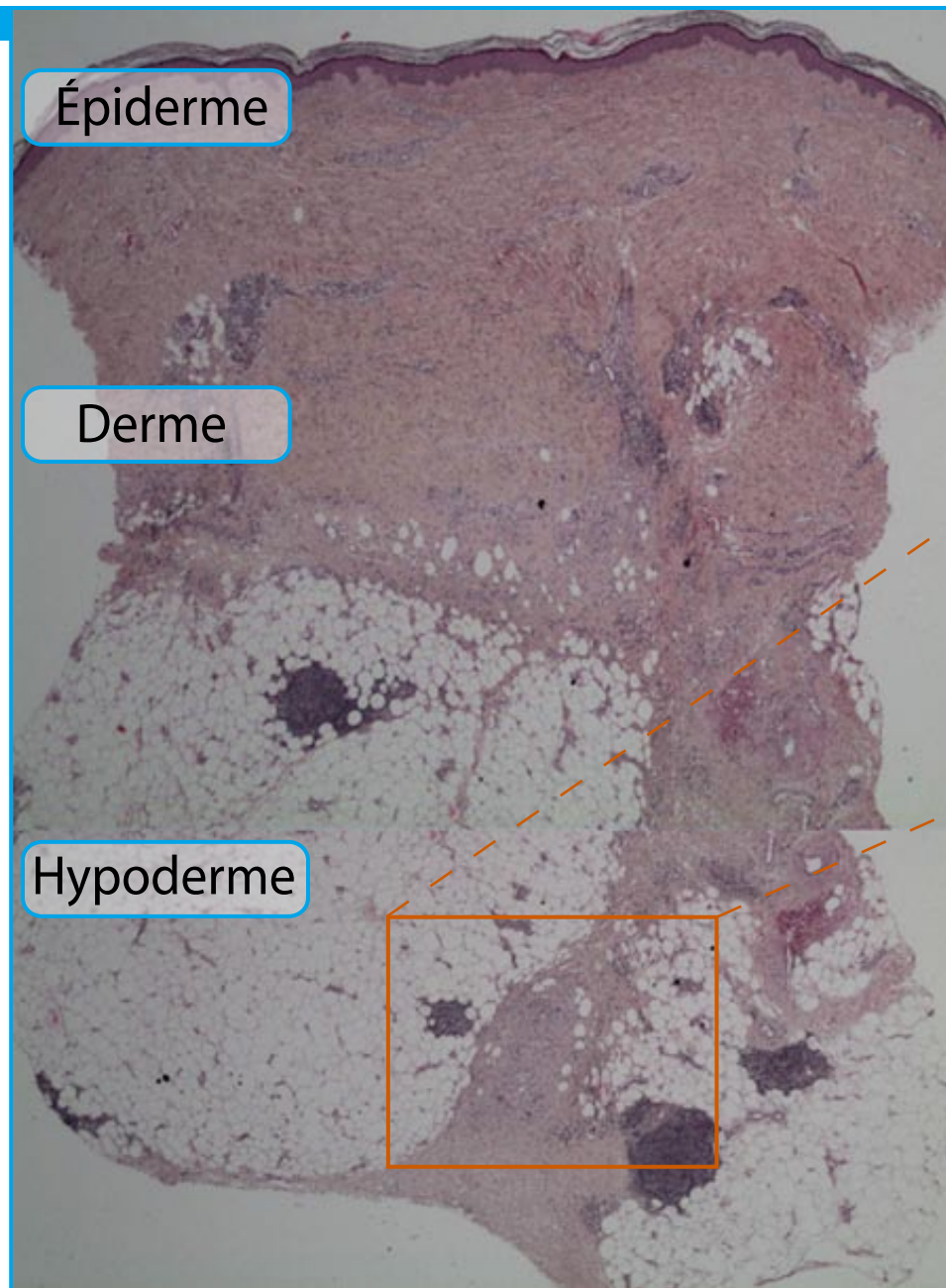
■ Acné



■ Copyright © 2010 by Saunders, an imprint of Elsevier Inc

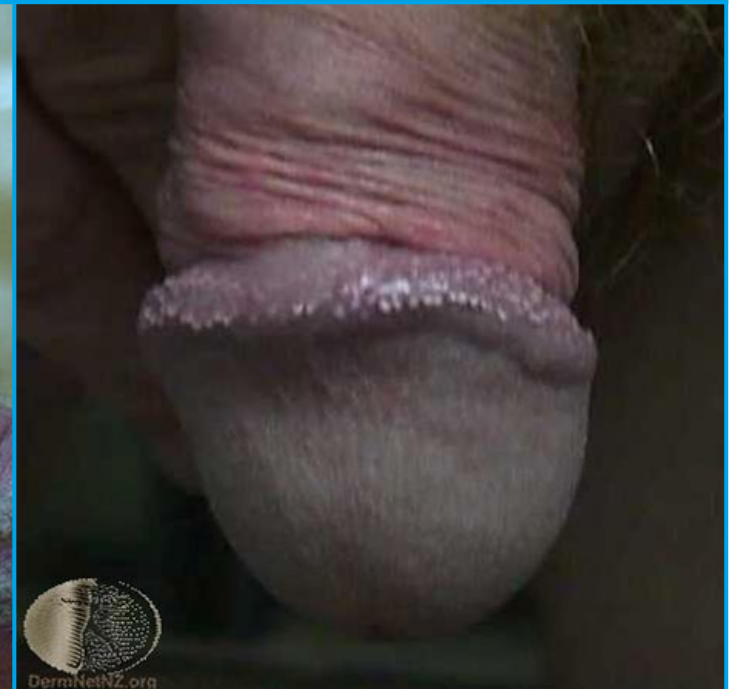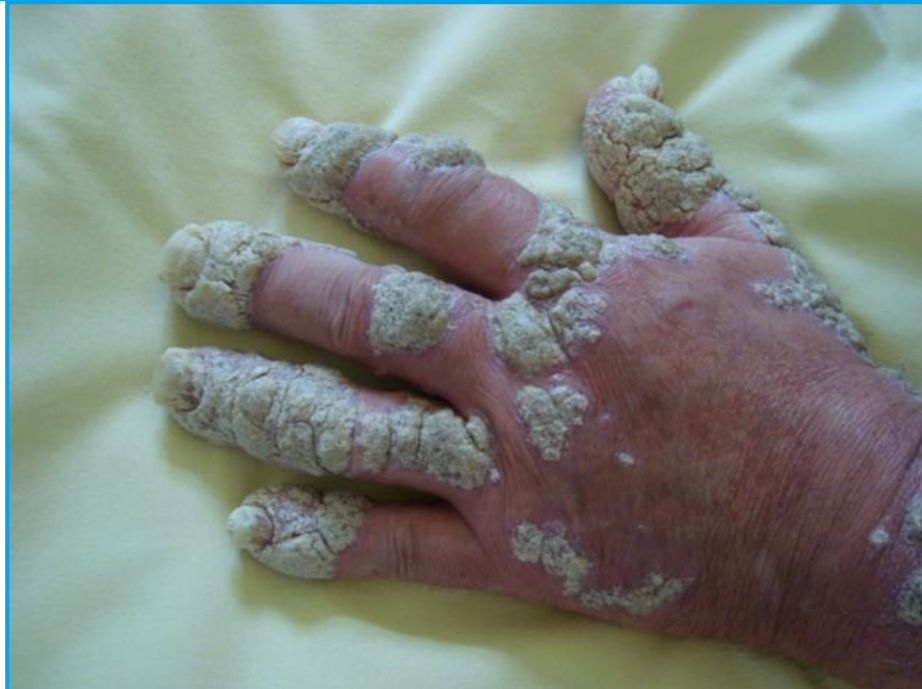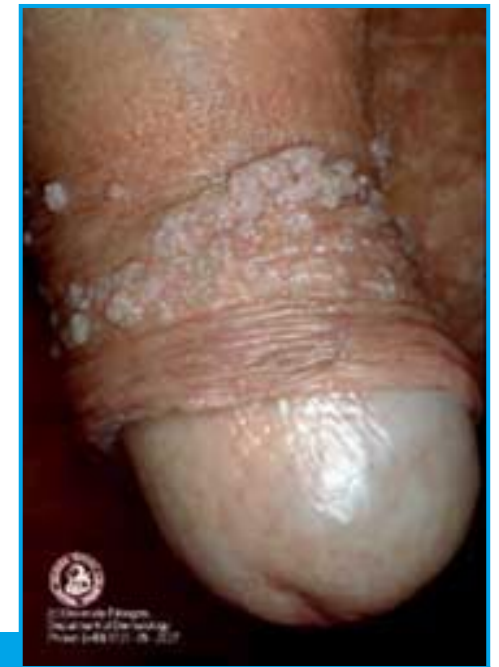■ Nodule hypodermique
Nouure



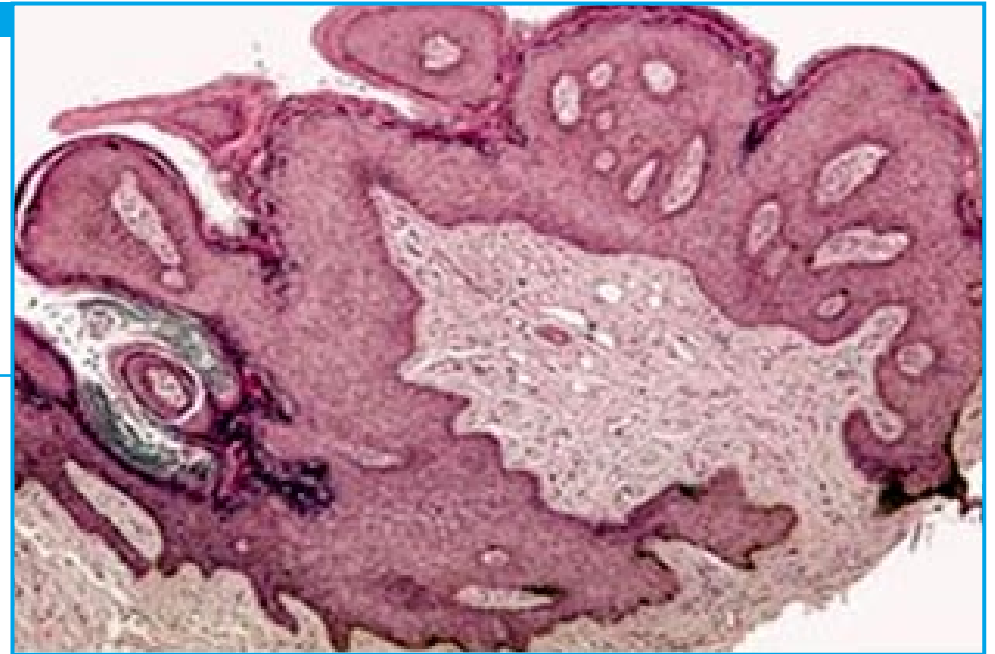


Inflammation du derme
et de l'hypoderme

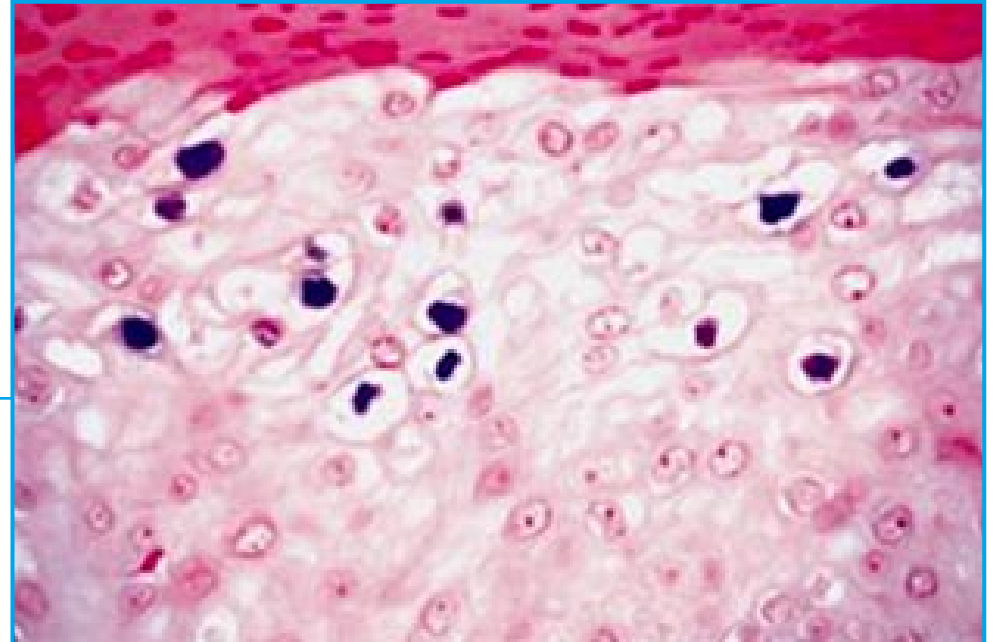
Végétations




■ Lésions végétantes



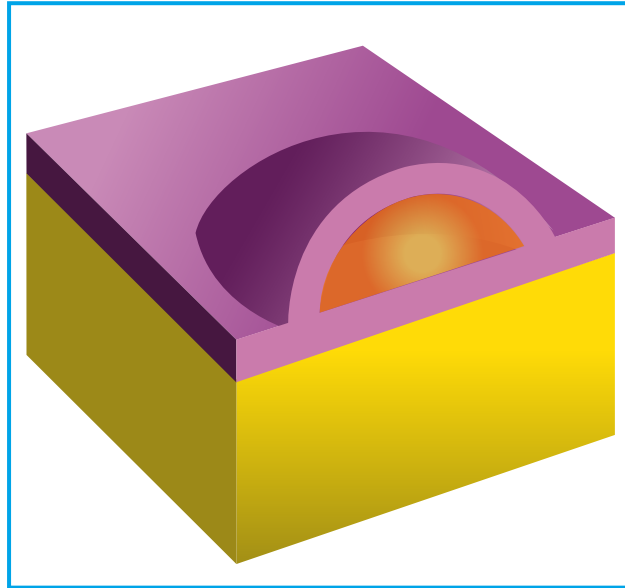
■ Mise en évidence de la nature virale de la lésion (détection du génome viral dans le noyau des cellules)



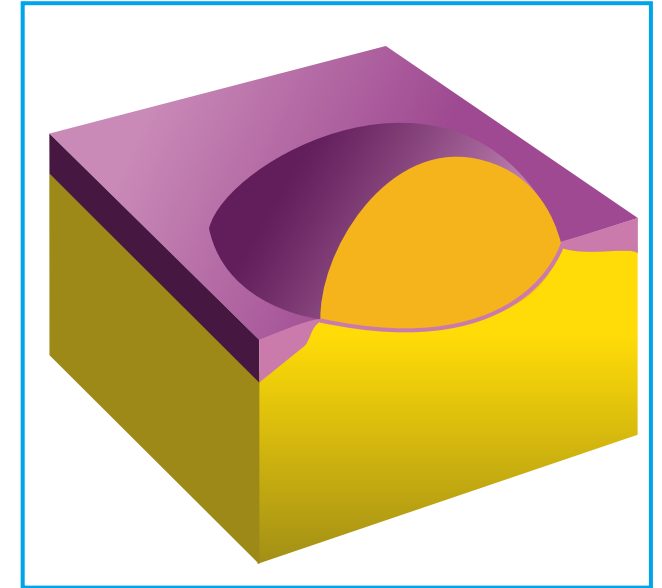
Lésions liquidiennes



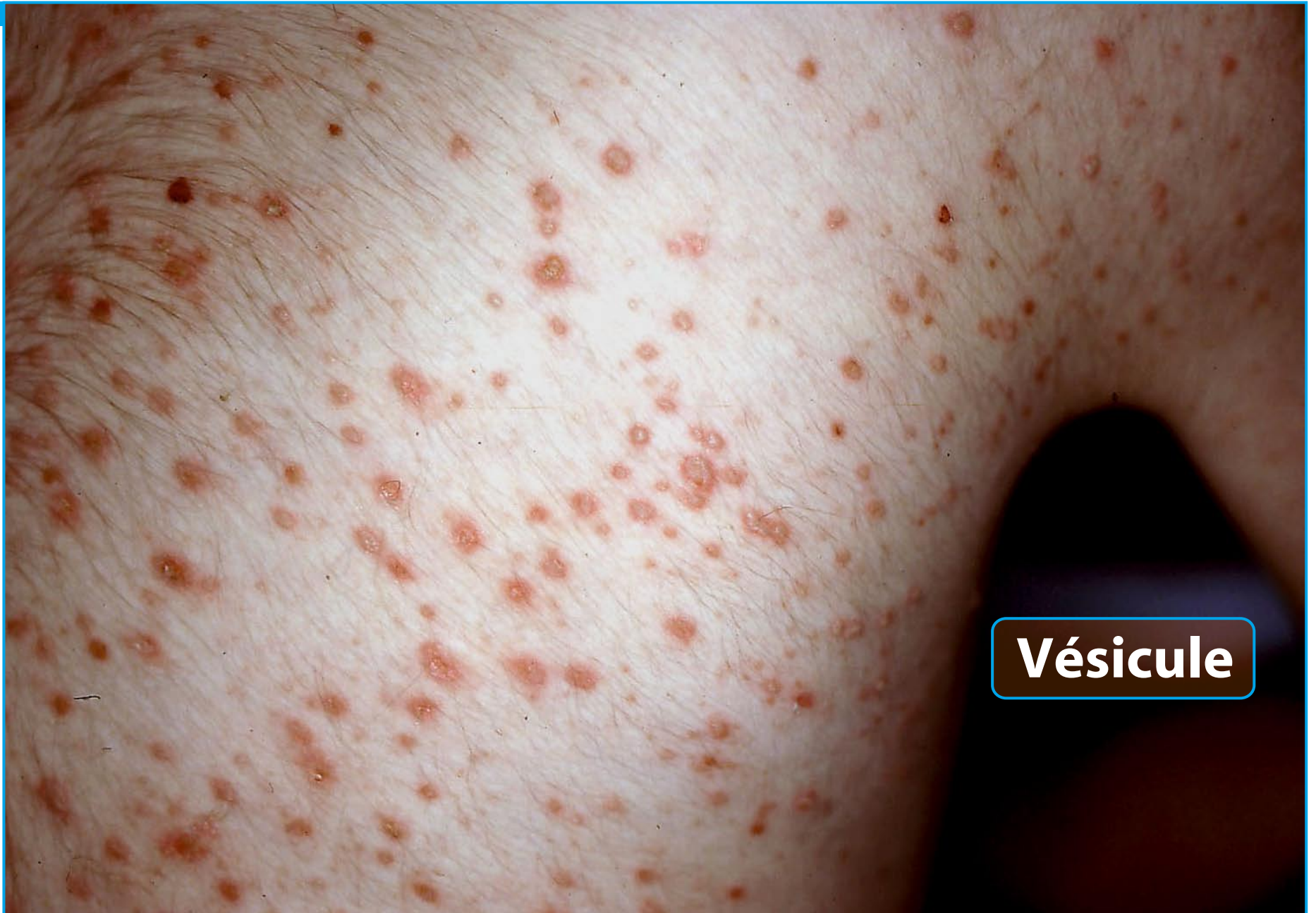Vésicule ou bulle
sous-épidermique



Vésicule ou bulle
intra-épidermique

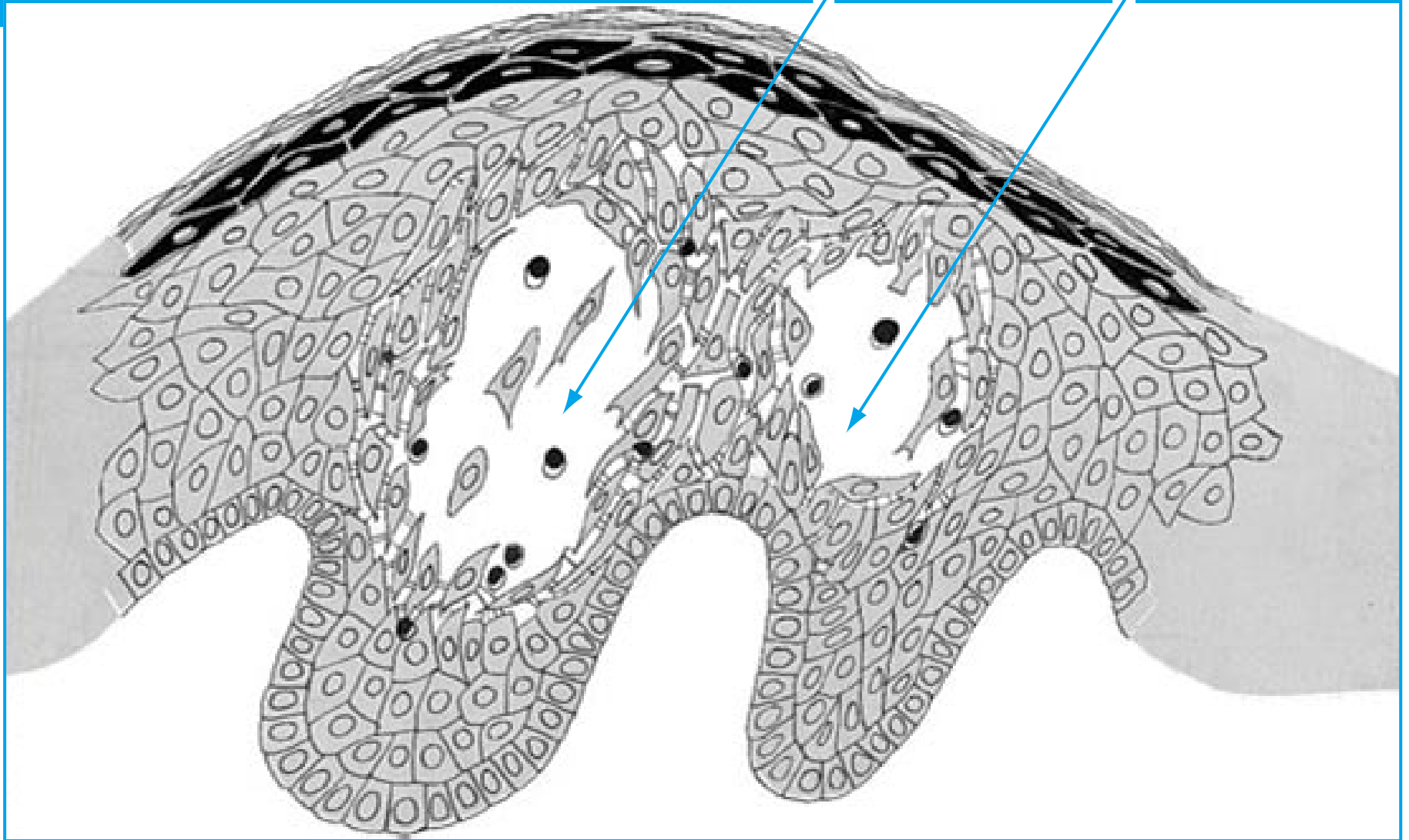


Pustule



Vésicule

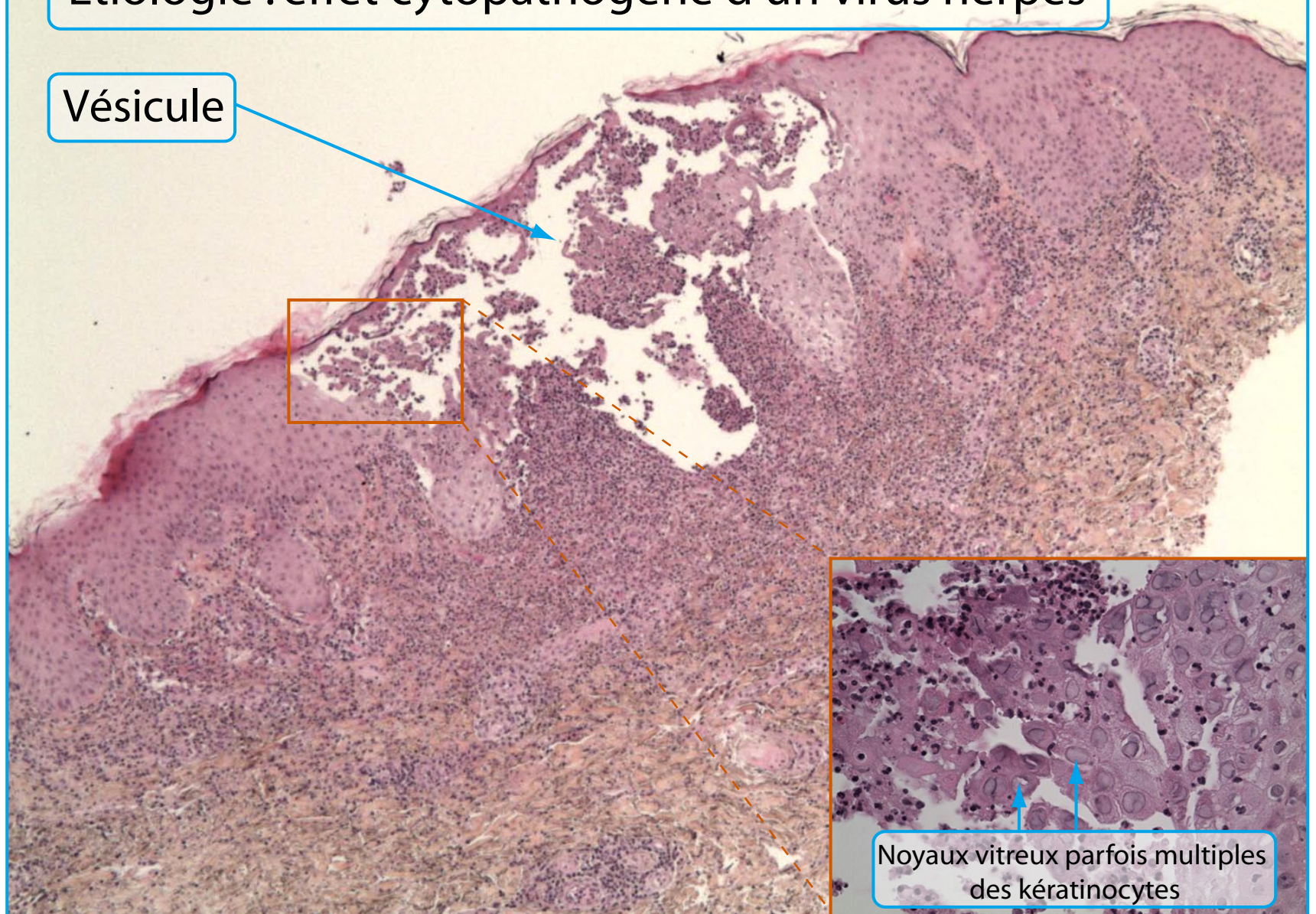
■ Vésicule histologique



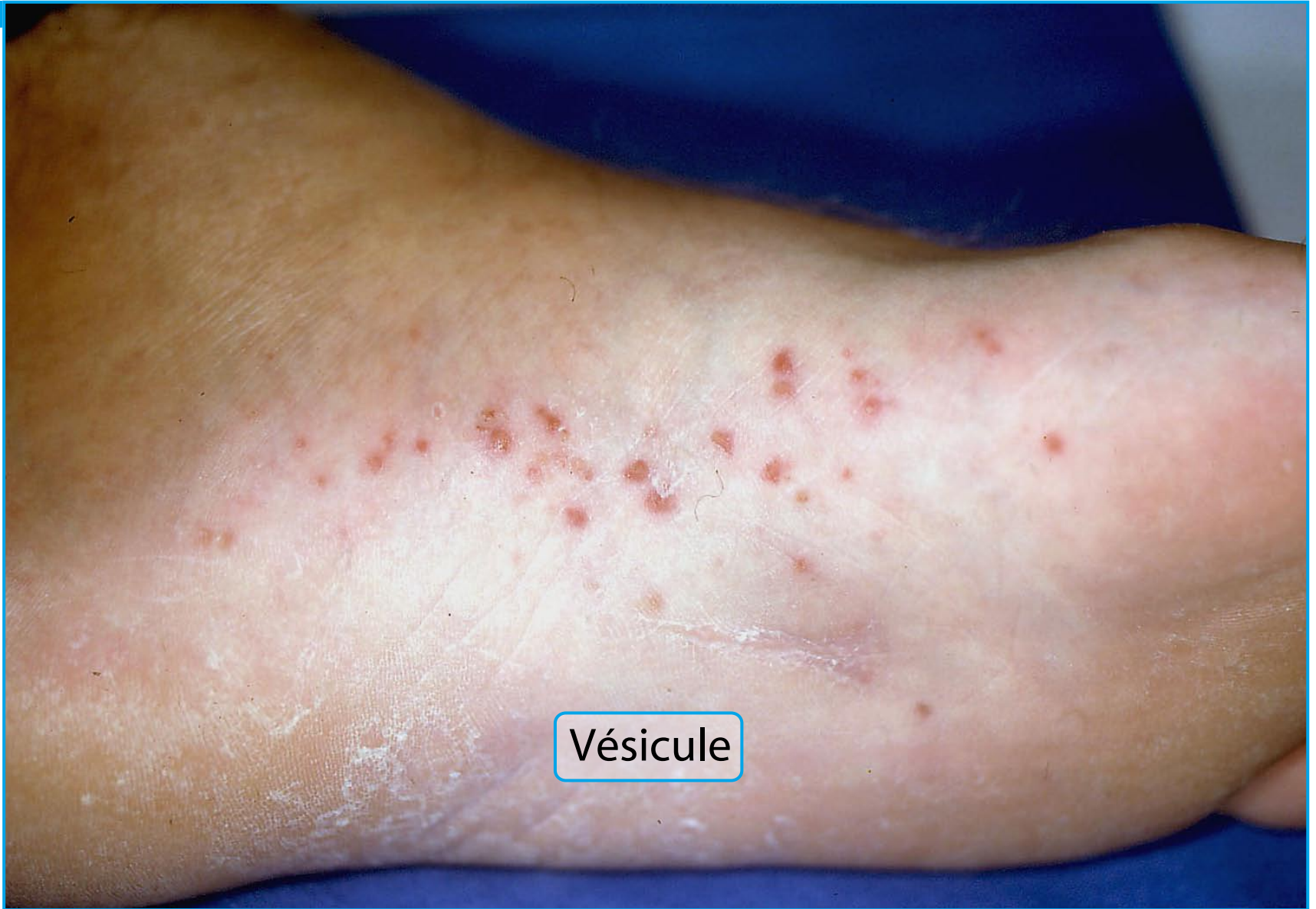■ Dissociation des kératinocytes les uns des autres

Étiologie : effet cytopathogène d'un virus herpès

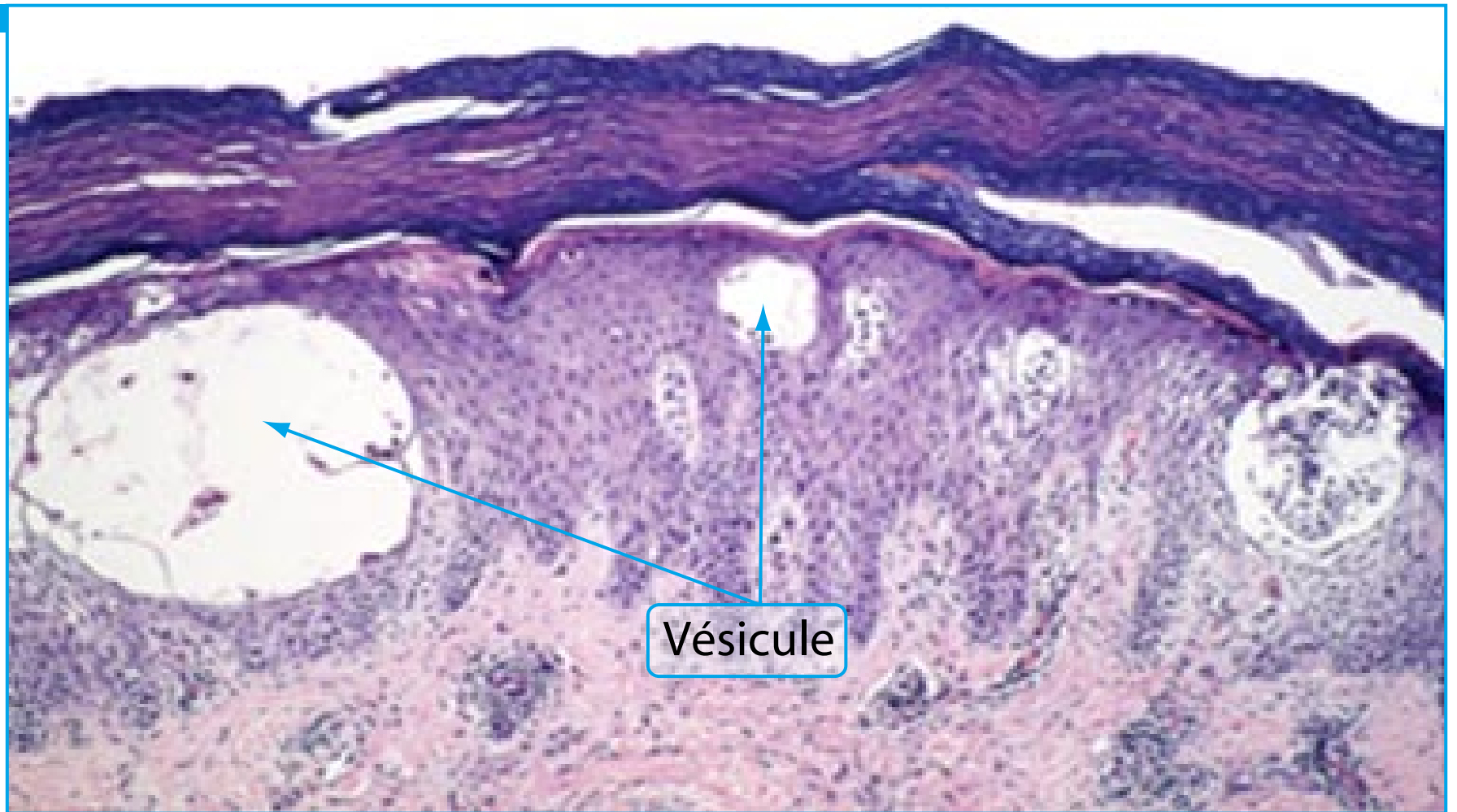
Vésicule



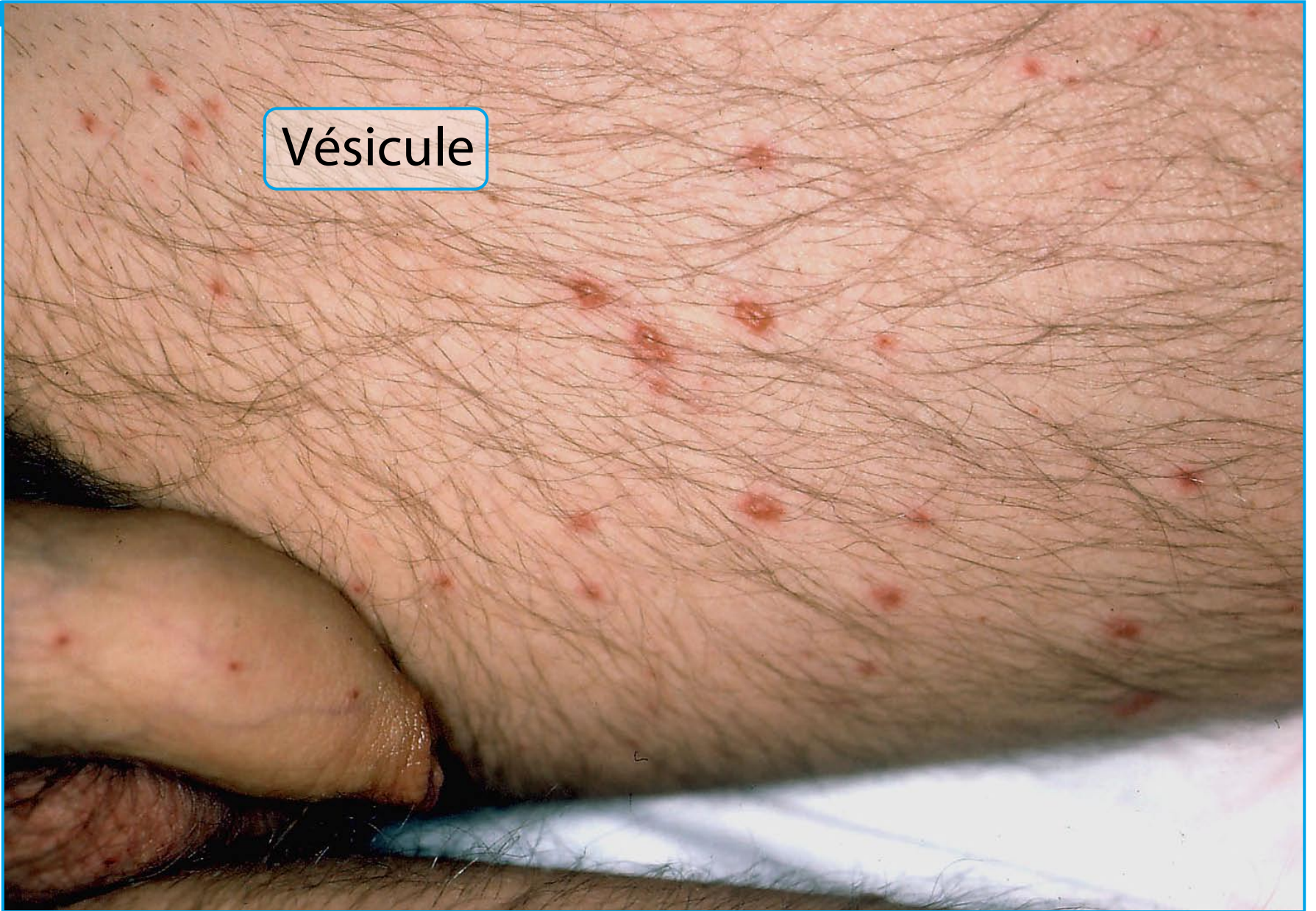Noyaux vitreux parfois multiples des kératinocytes

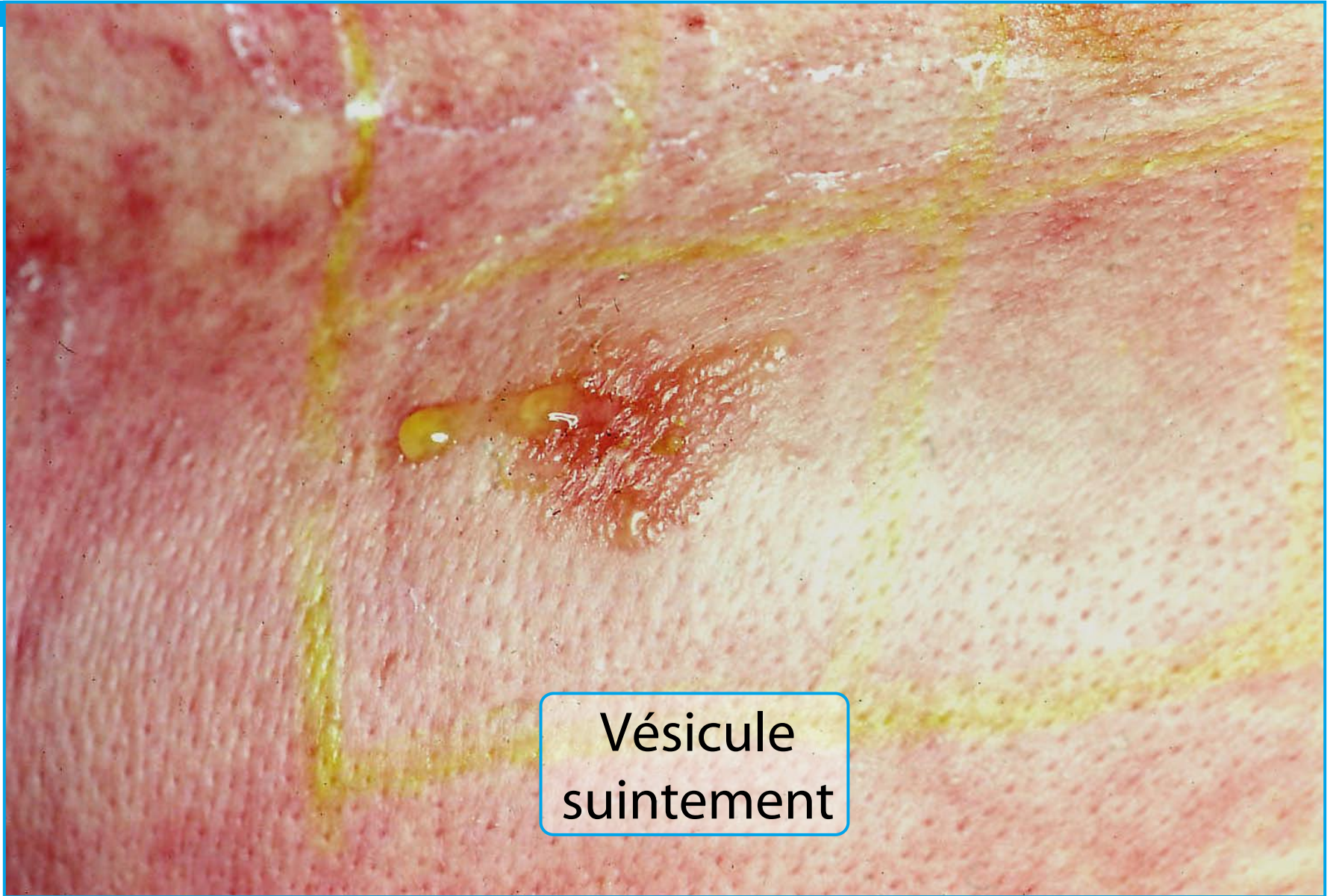


Vésicule



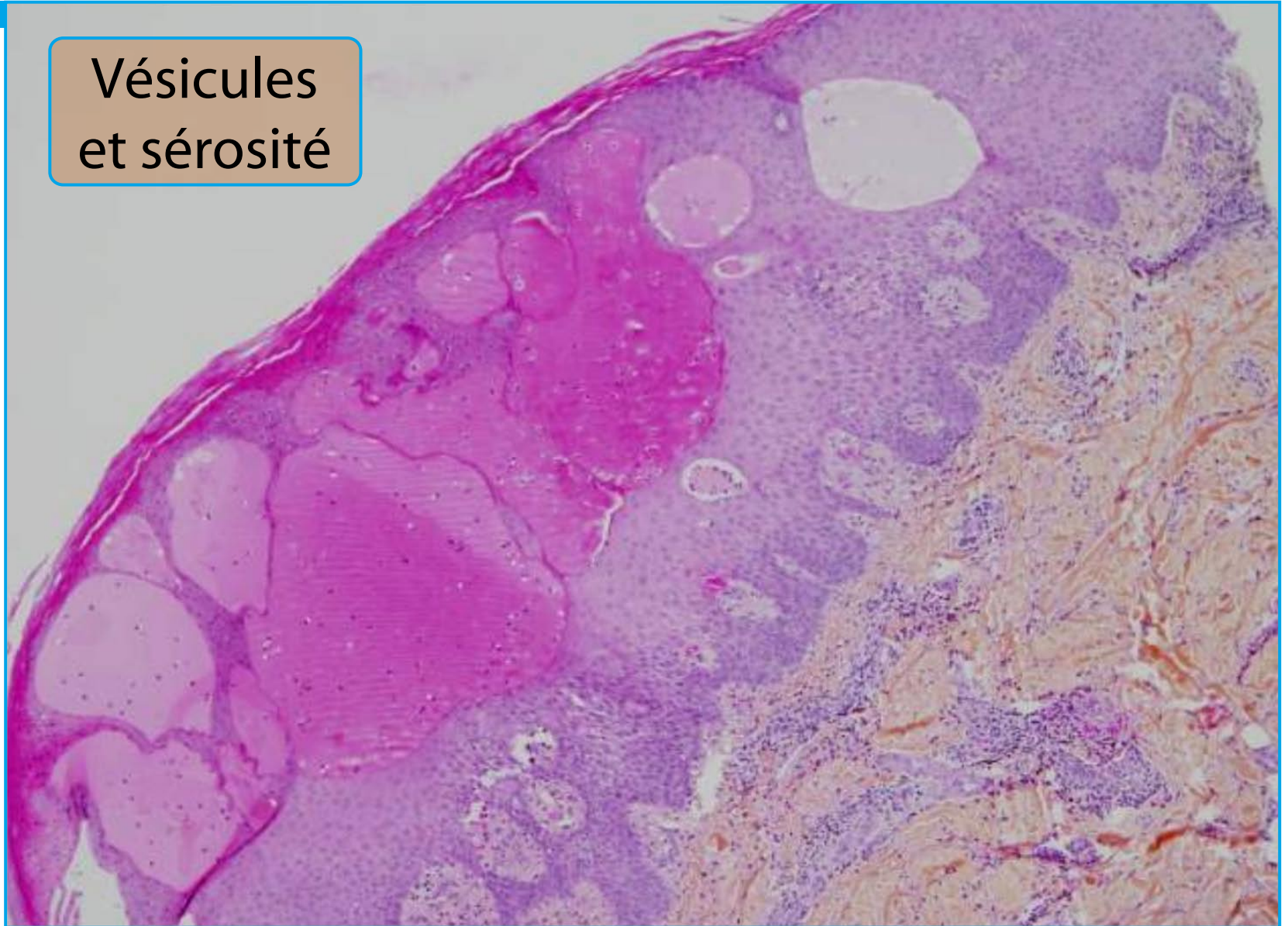
Vésicule



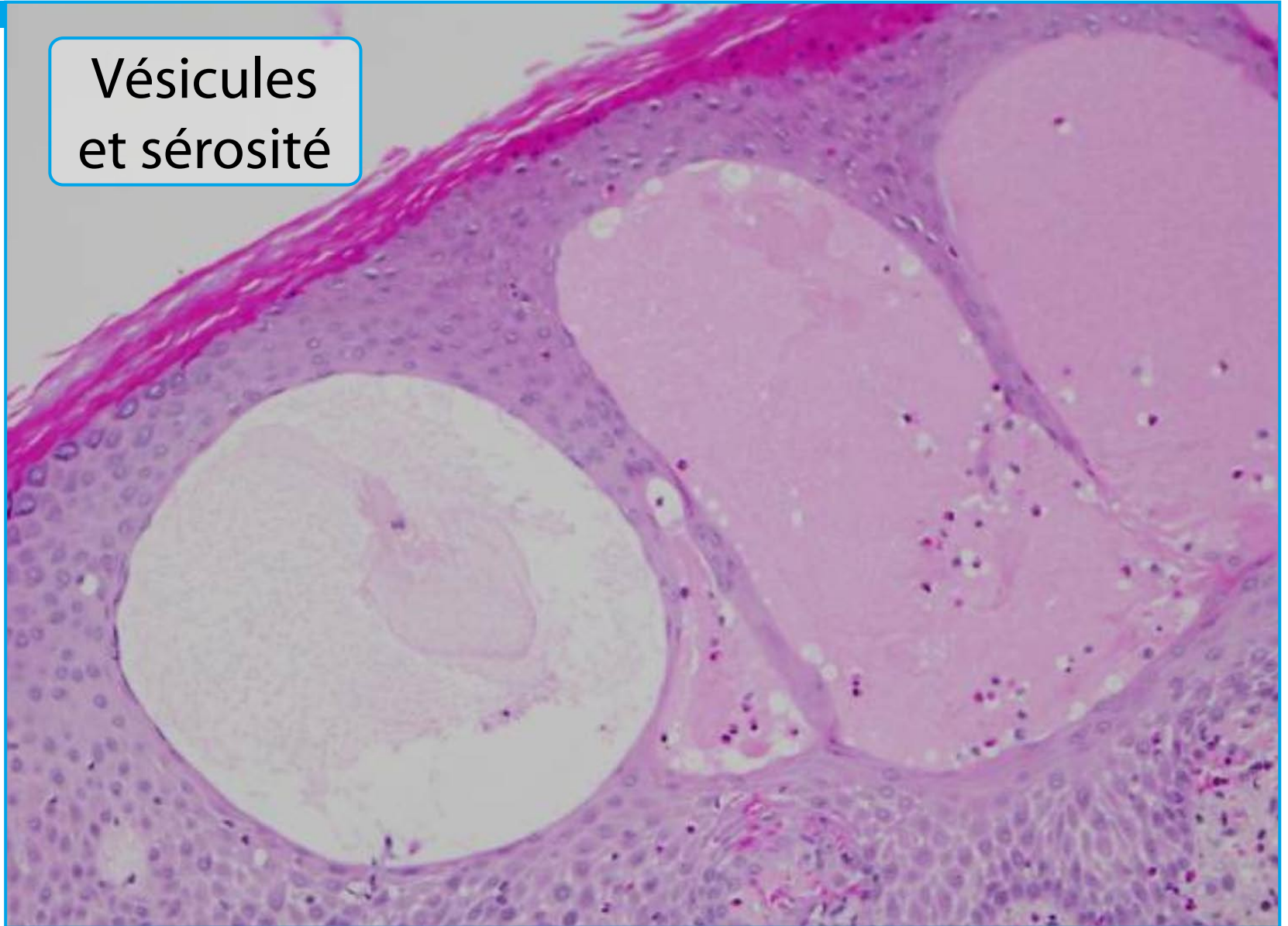

Vésicule
suintement

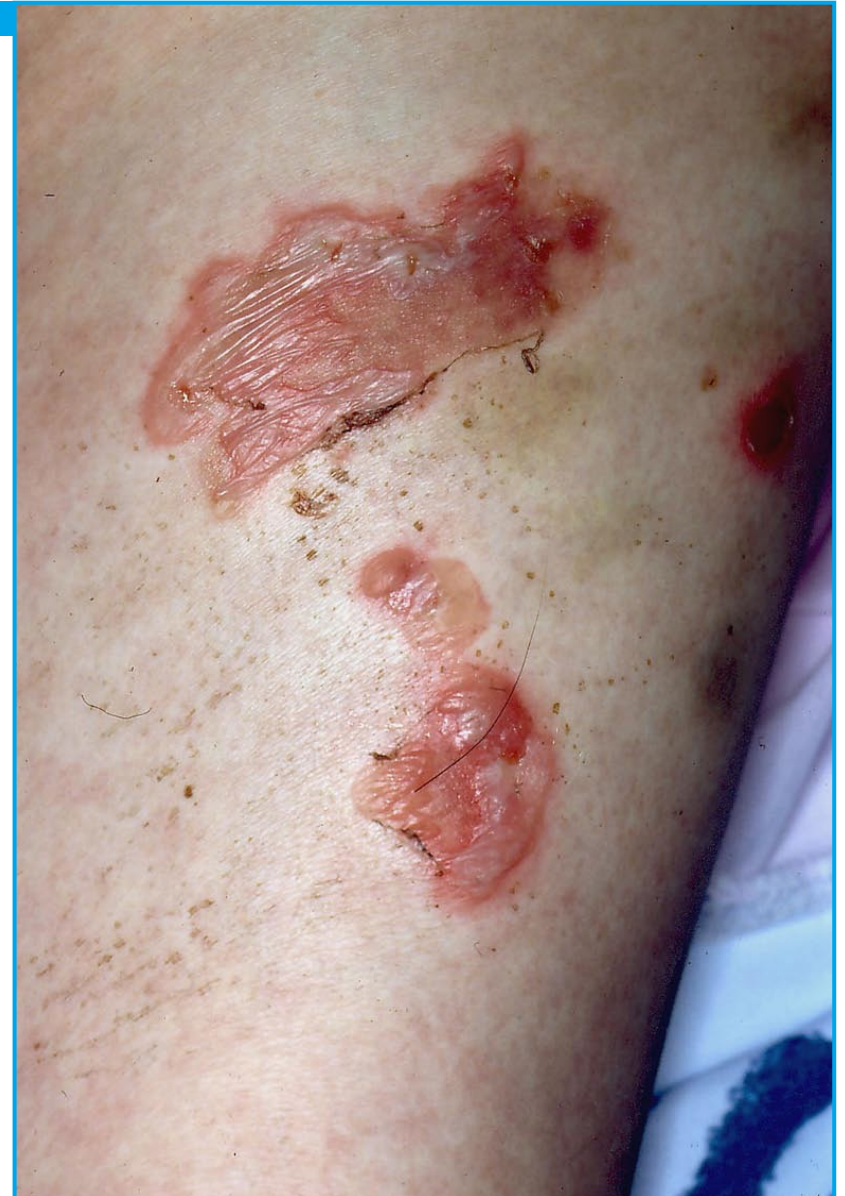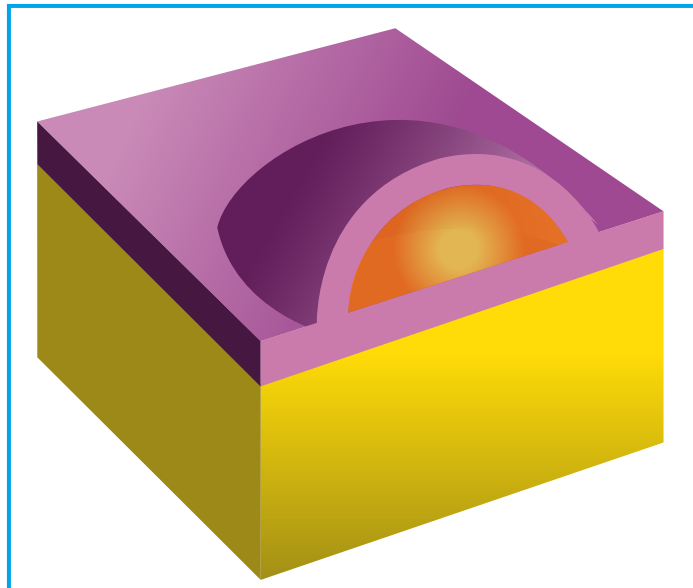
Vésicules
et sérosité



Vésicules
et sérosité



■ Bulle
intra-épidermique

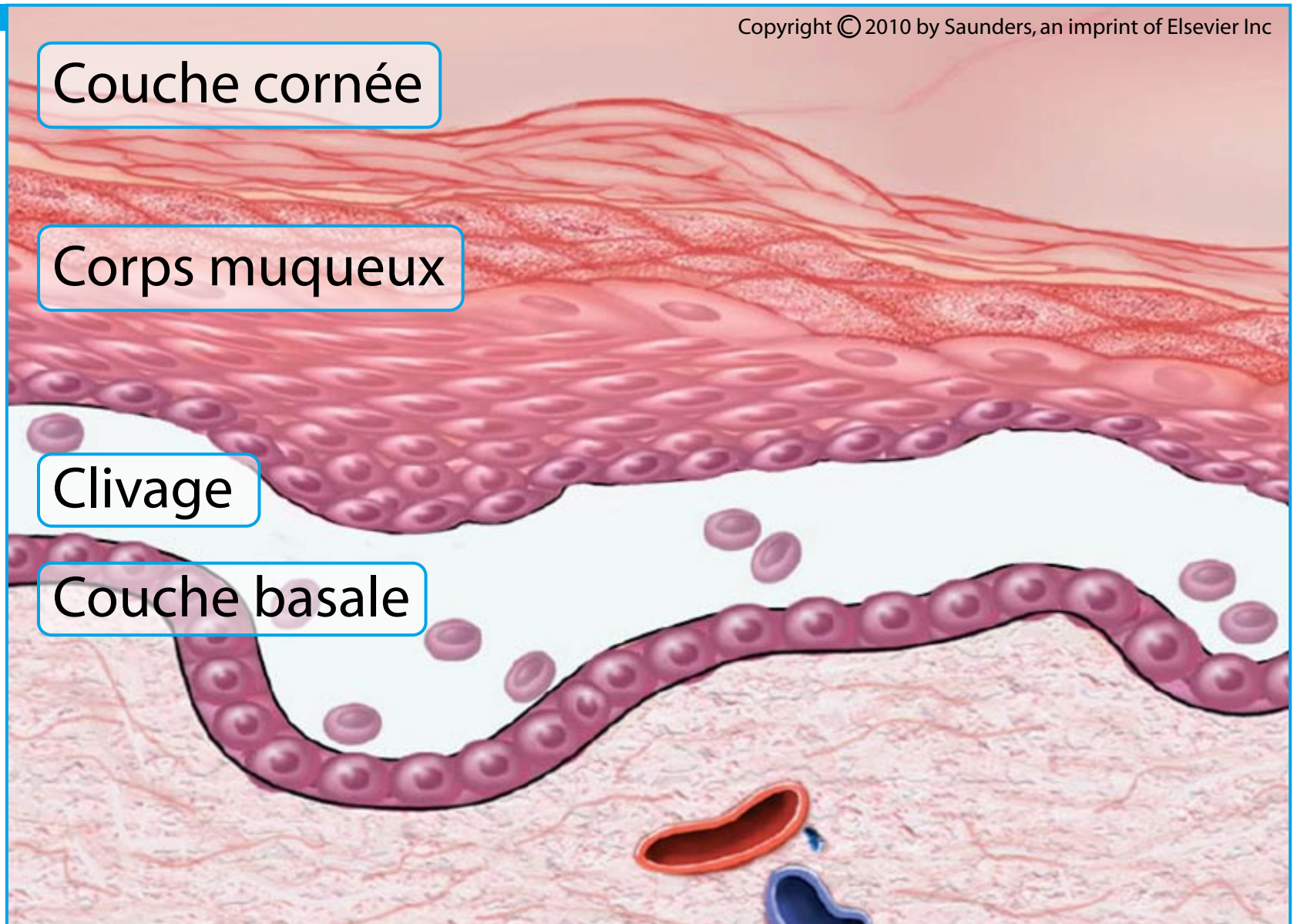


Couche cornée

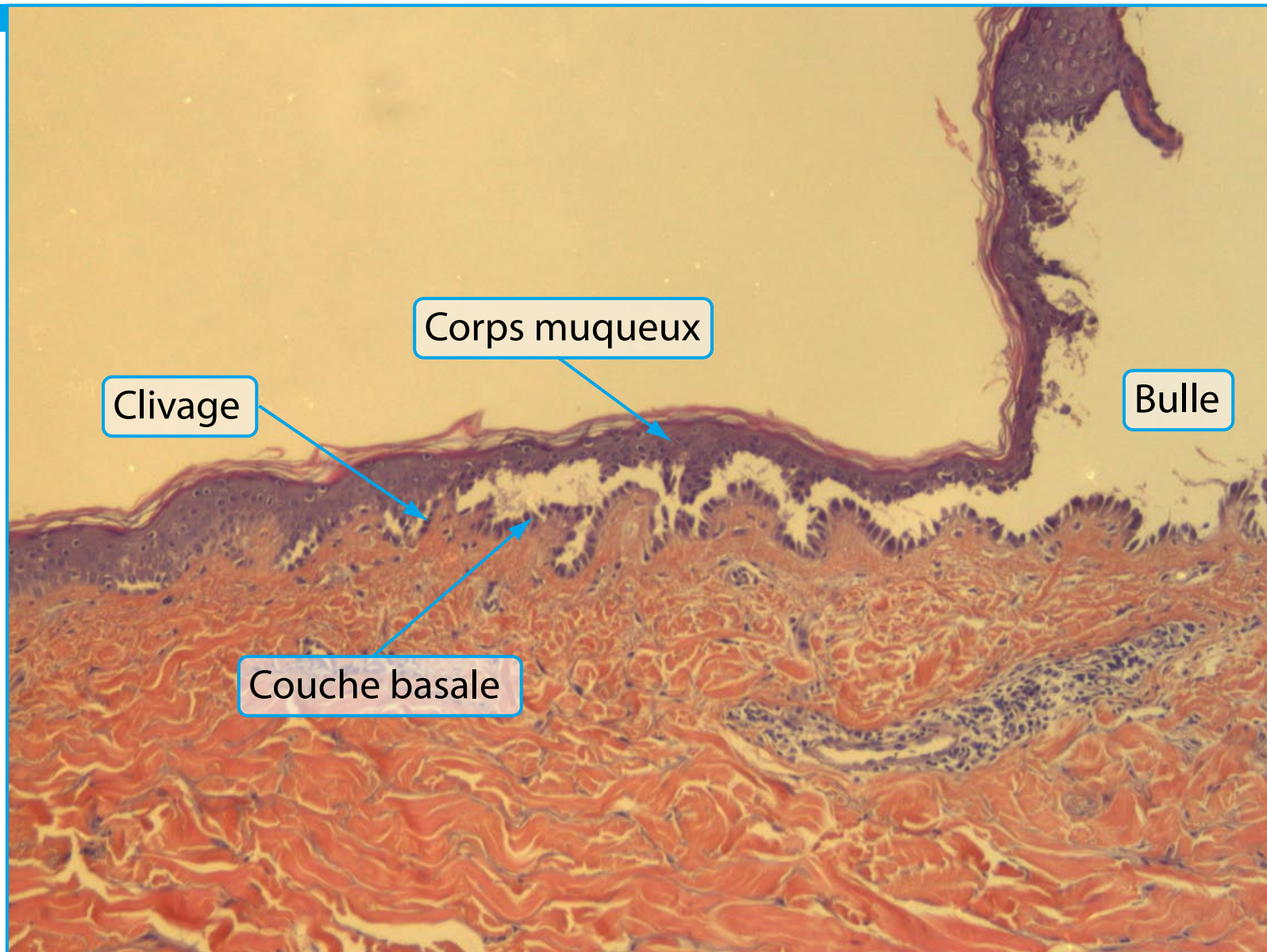
Corps muqueux

Clivage

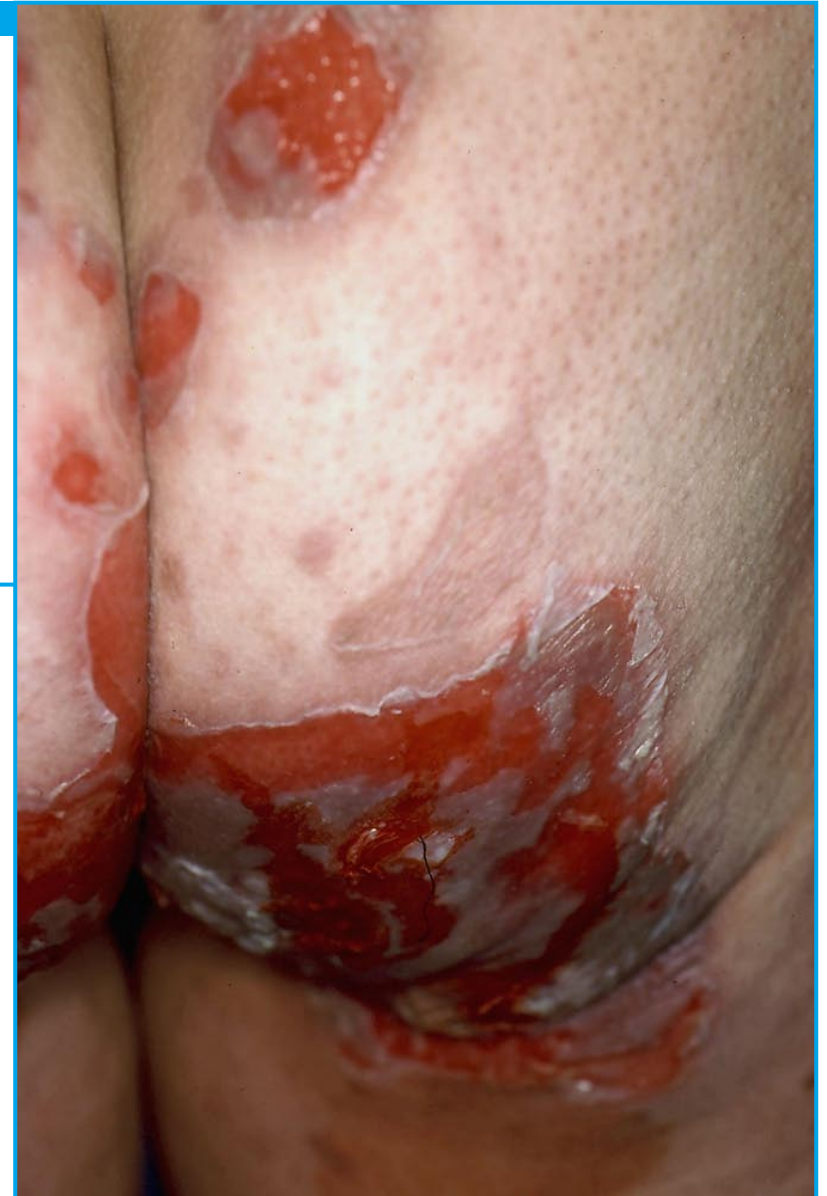Couche basale

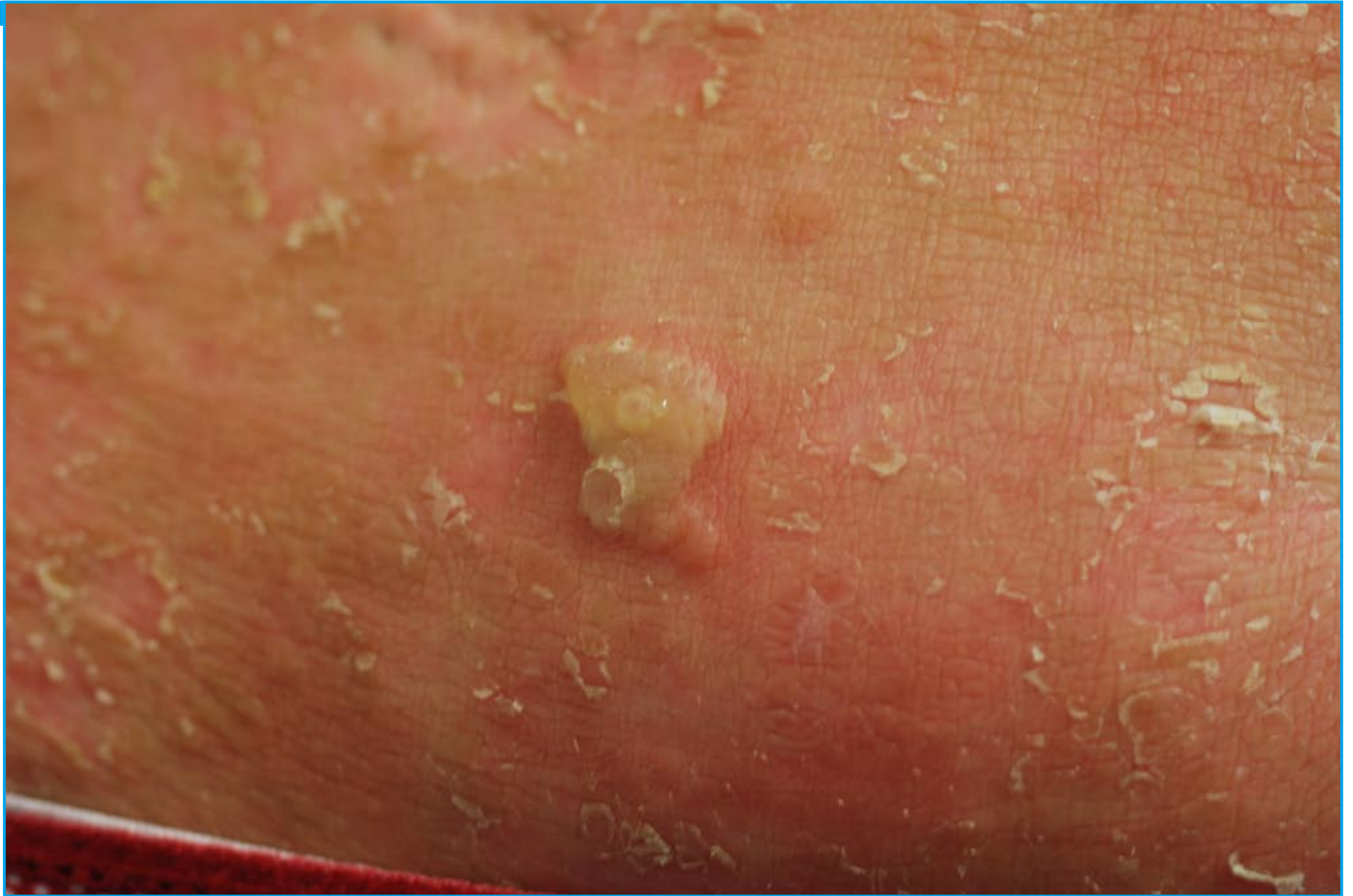

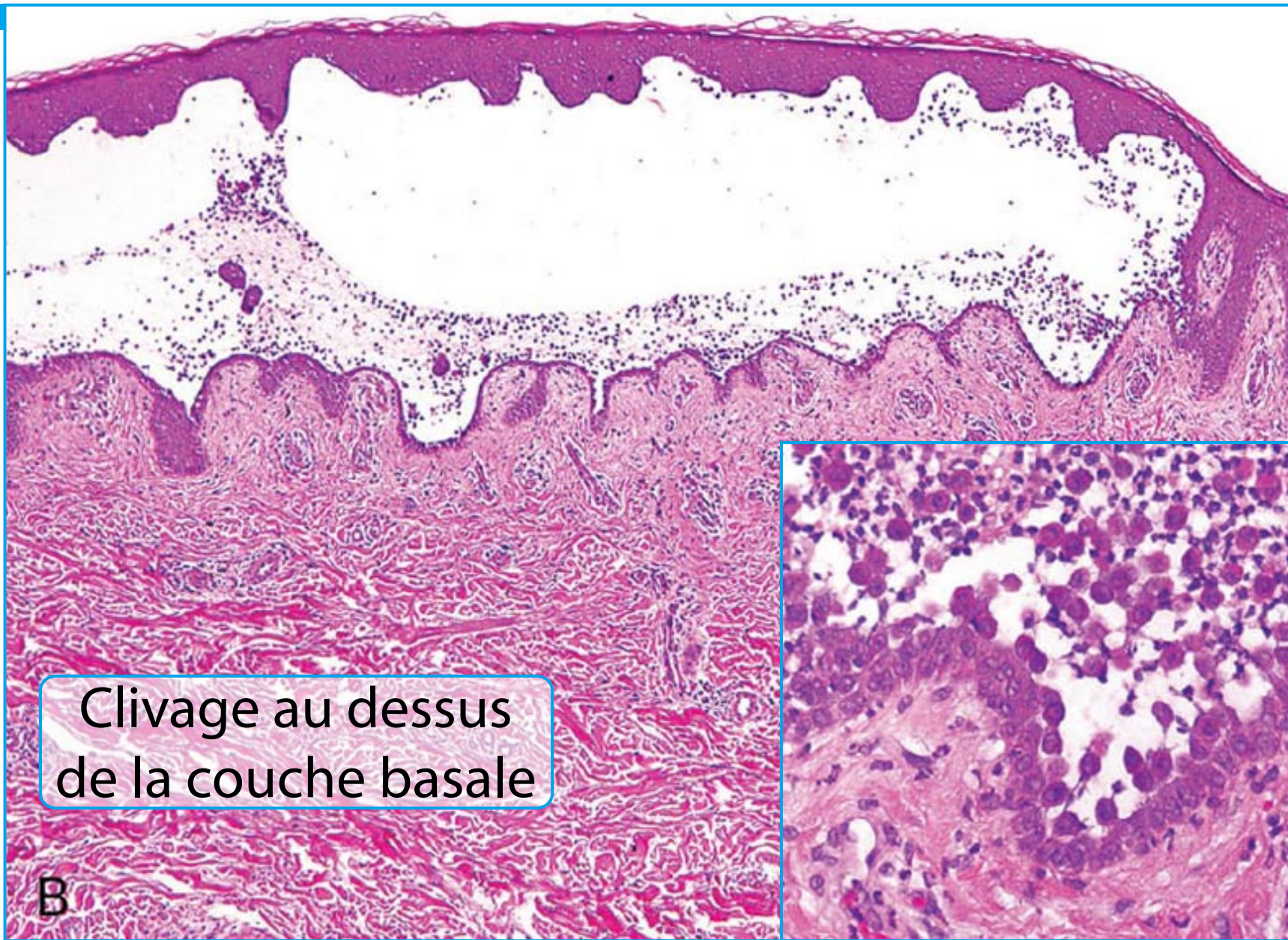
Clivage suprabasal



■ Bulle intra-épidermique

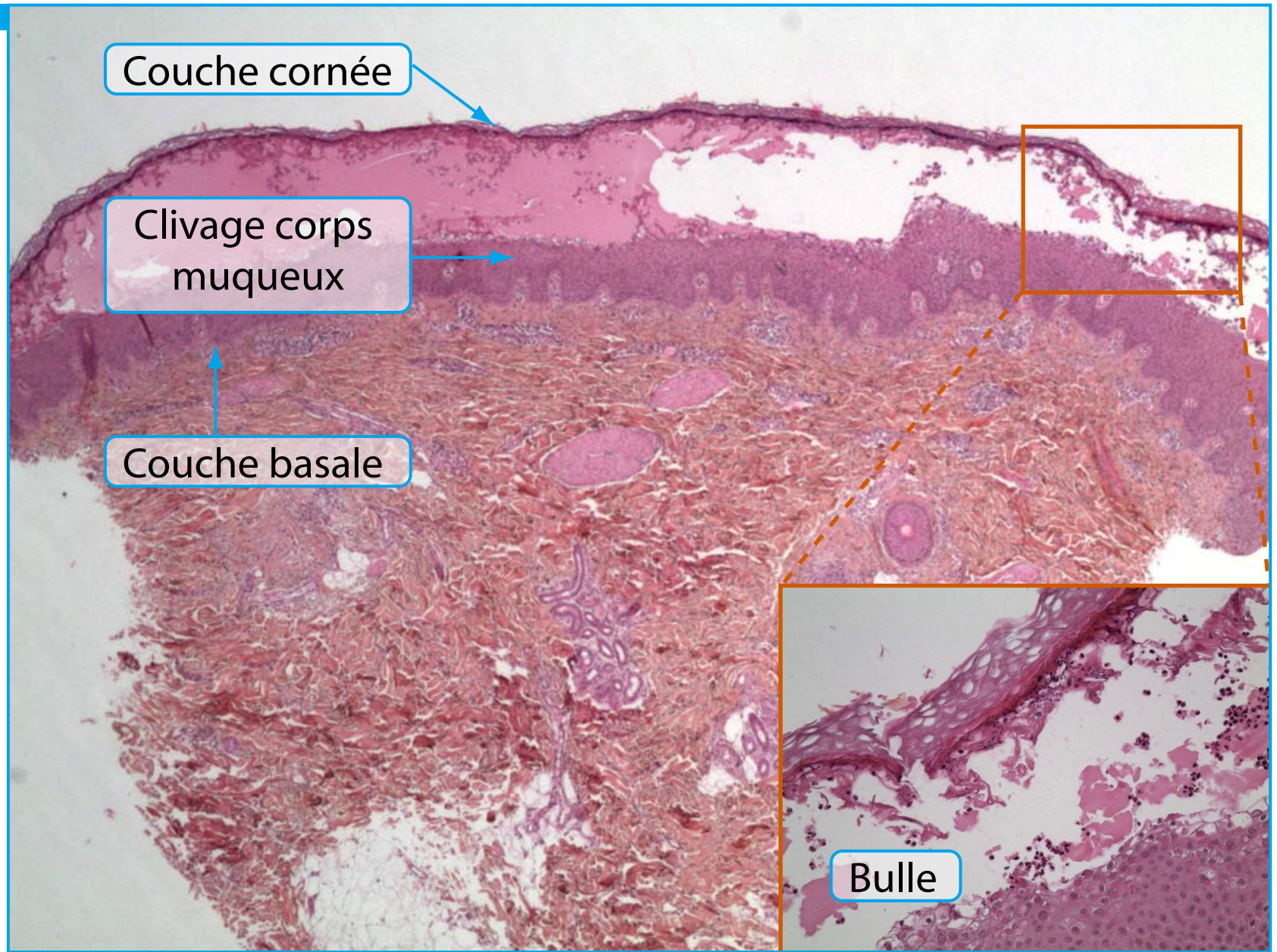






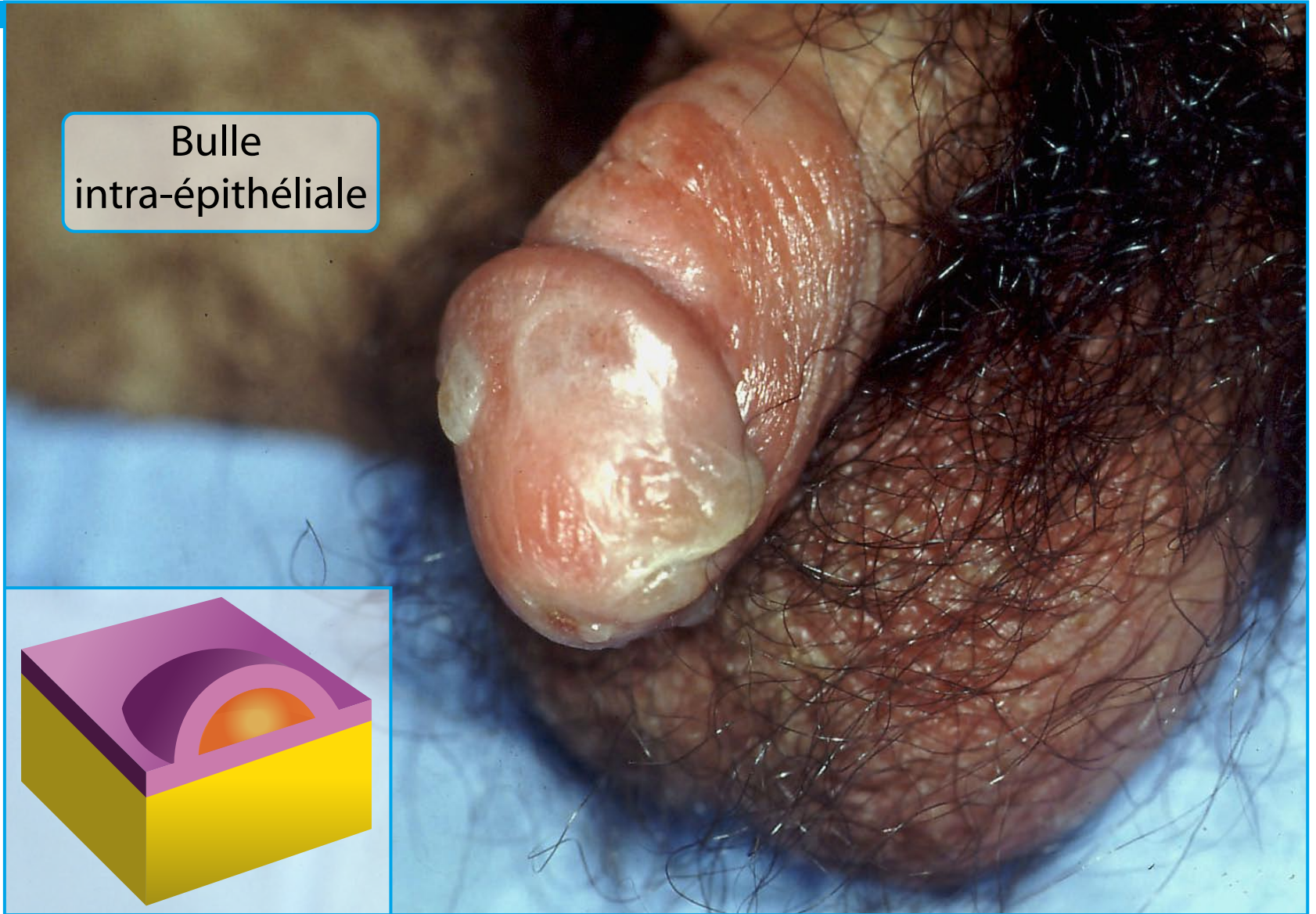

Clivage au dessus
de la couche basale

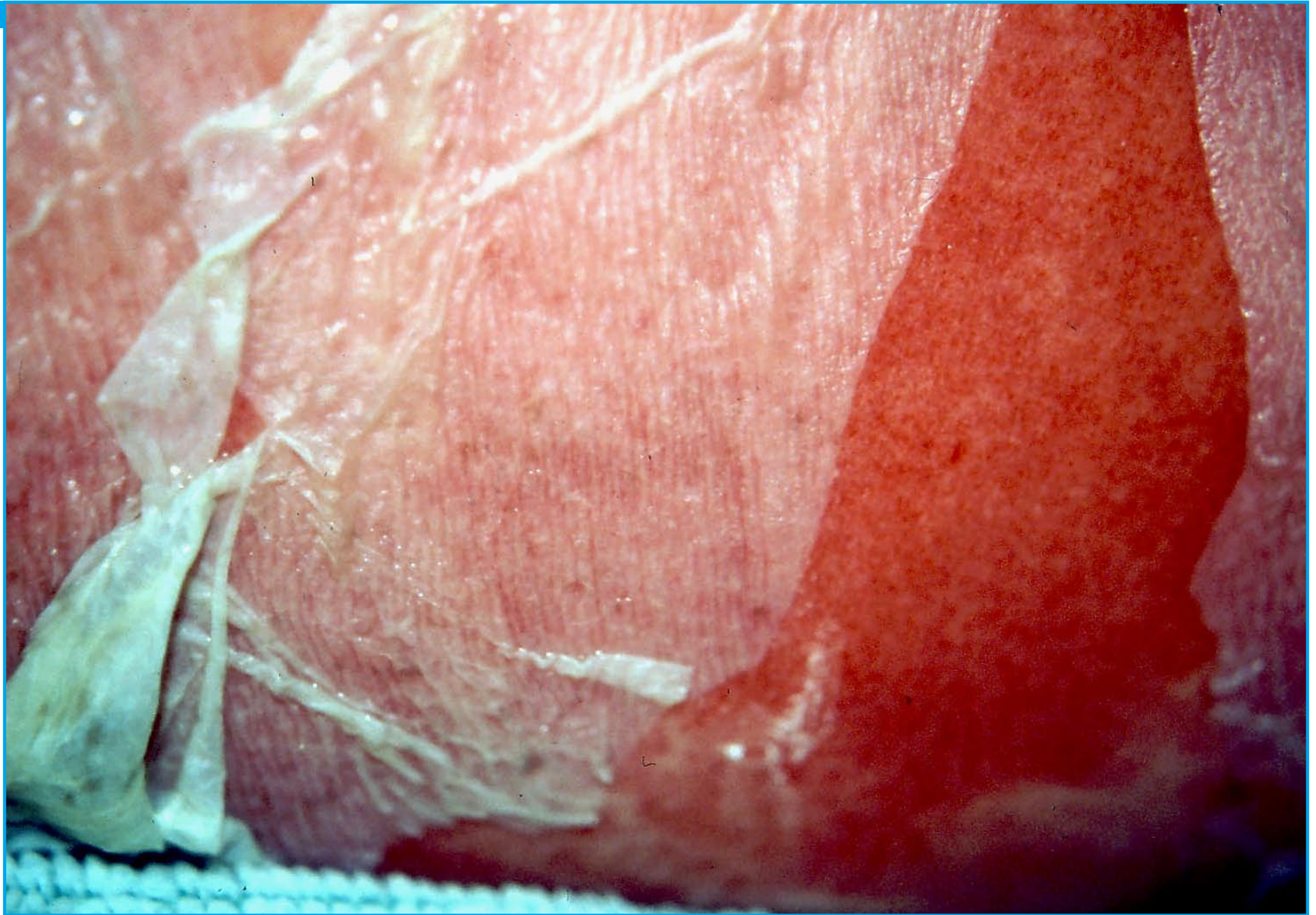
B



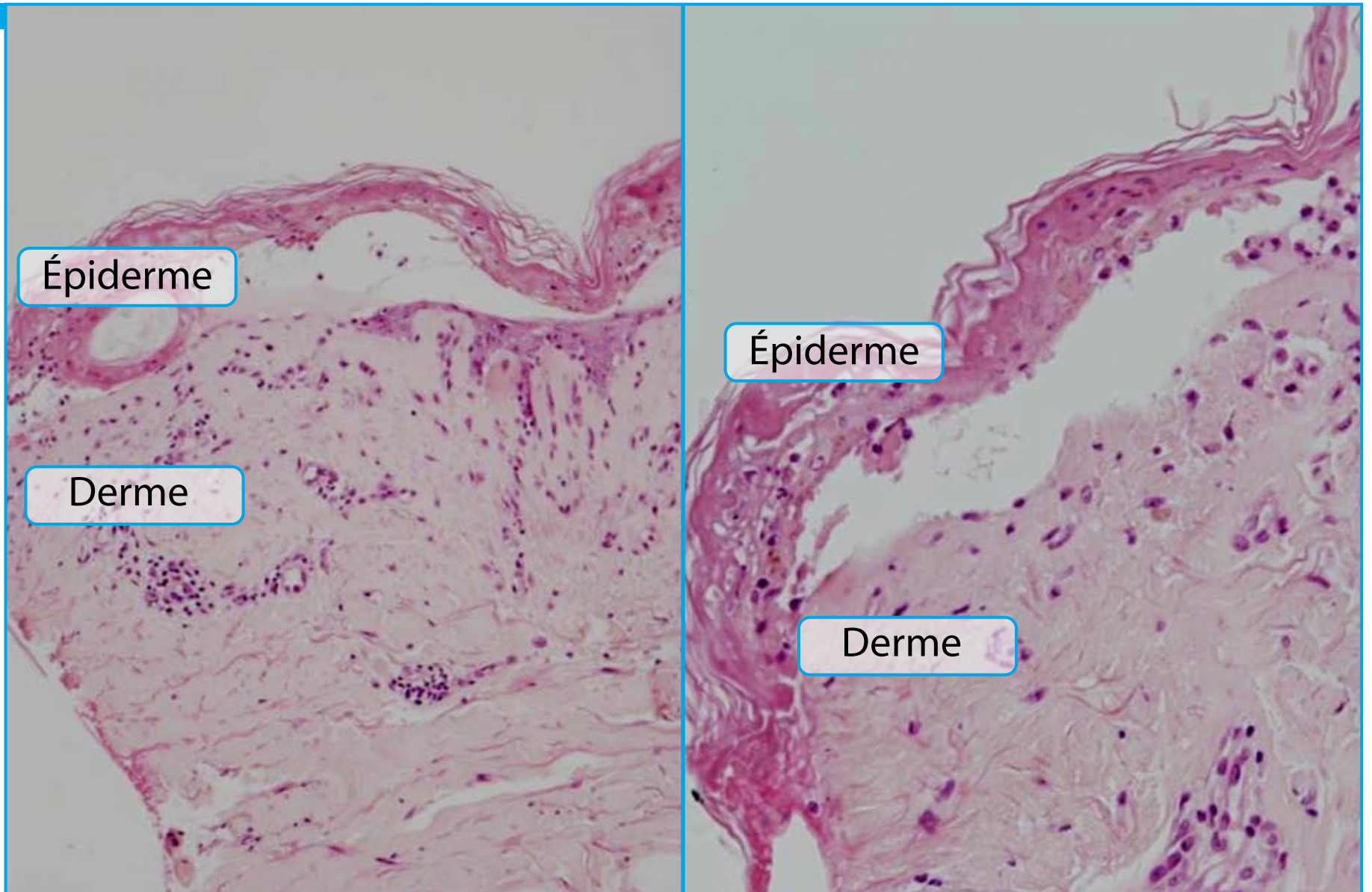
Clivage plus superficiel

Bulle
intra-épithéliale



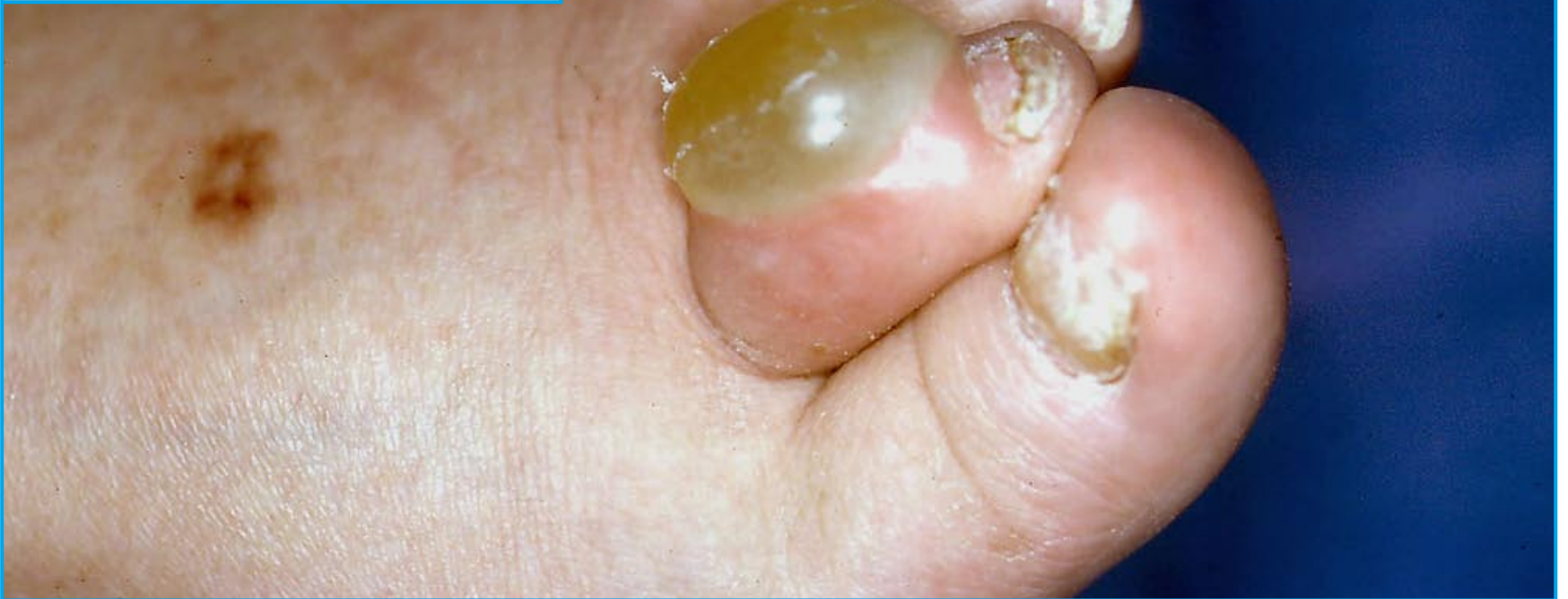


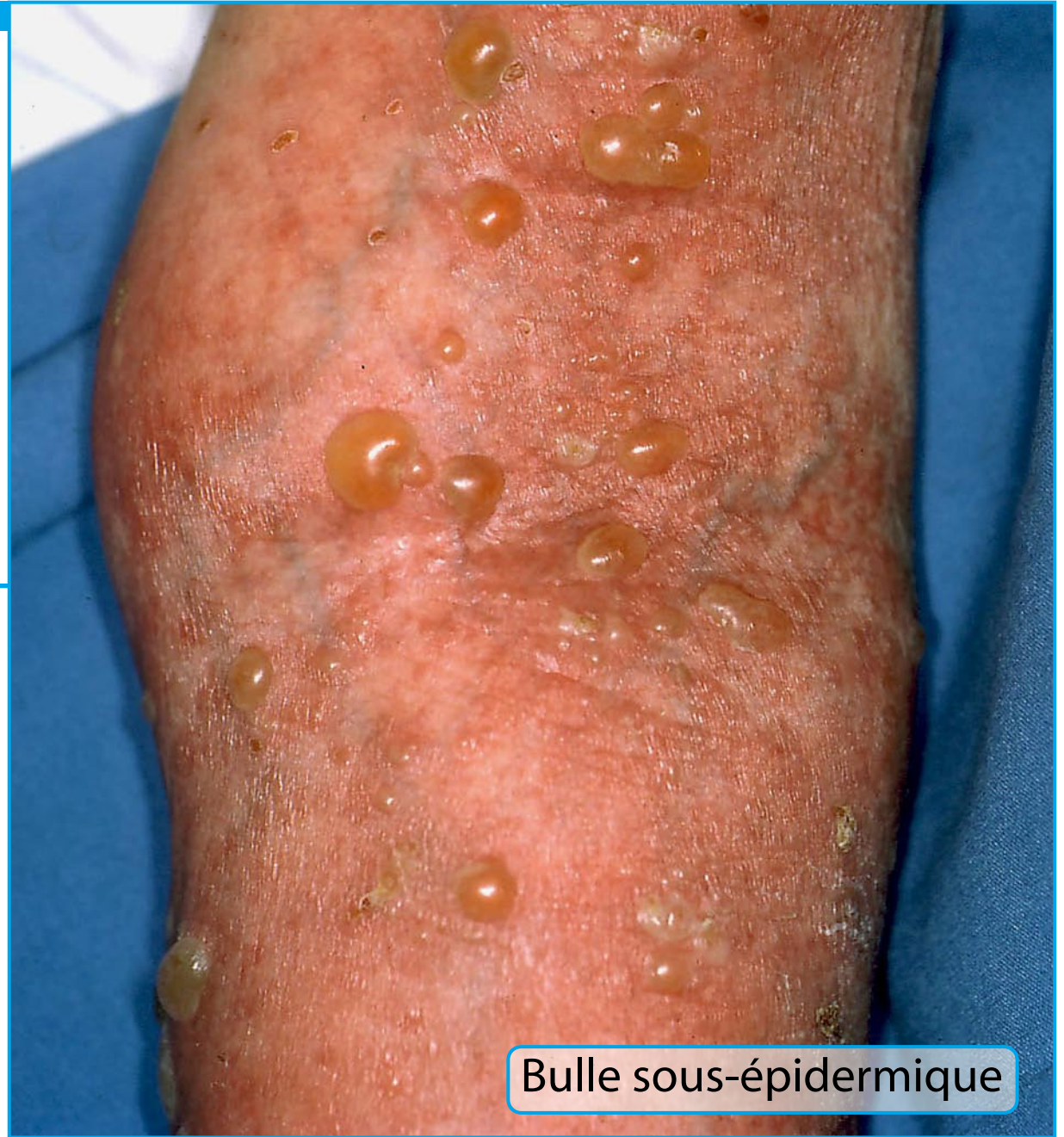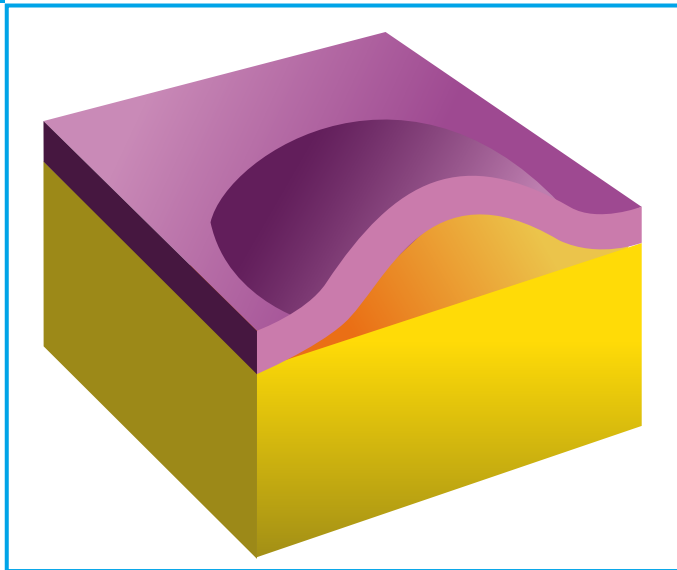
■ Bulle intra-épidermique : signe de Nikolsky



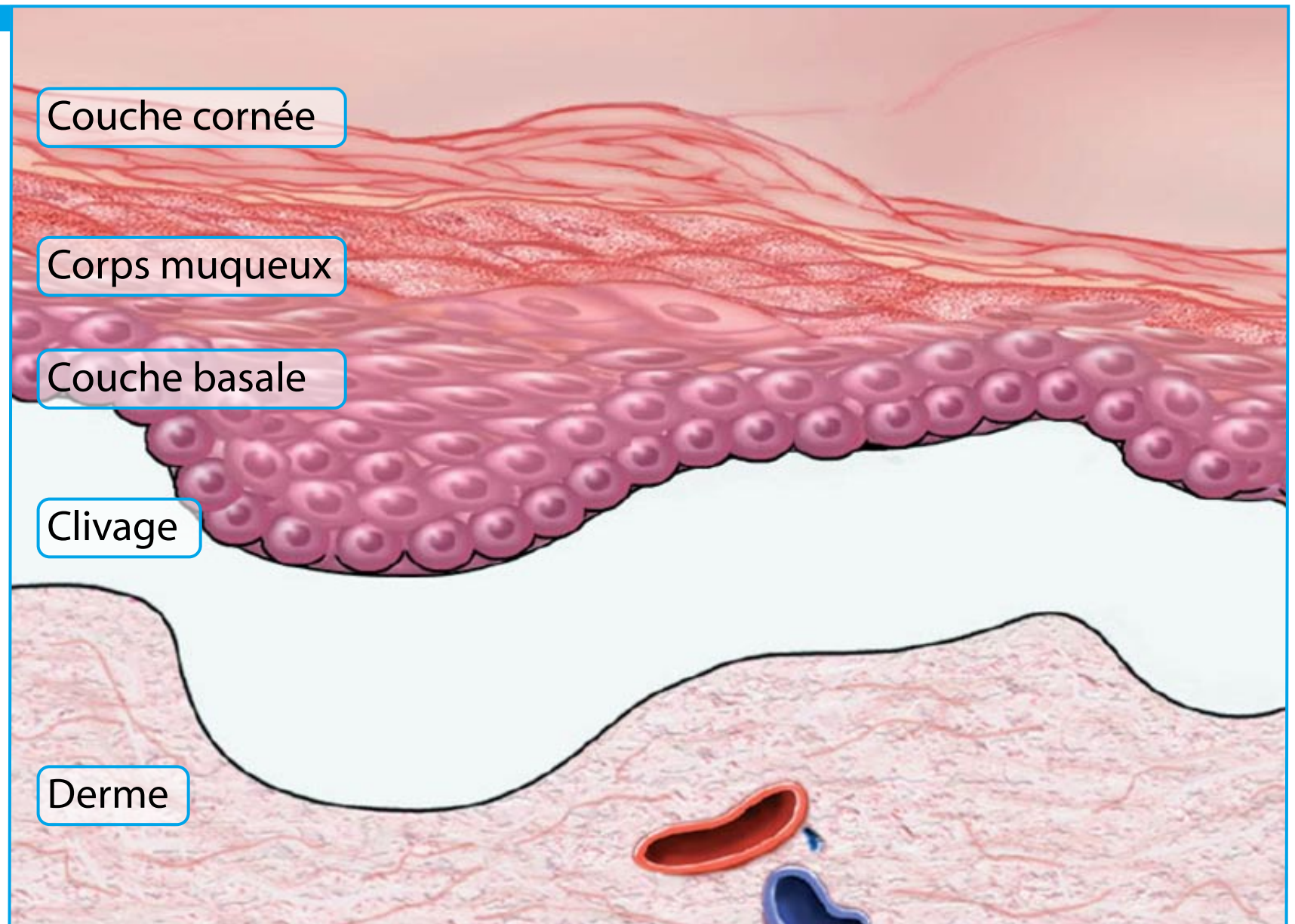
- Nécrose complète de l'épiderme et décollement de cet épiderme nécrosé

Bulle sous-épidermique



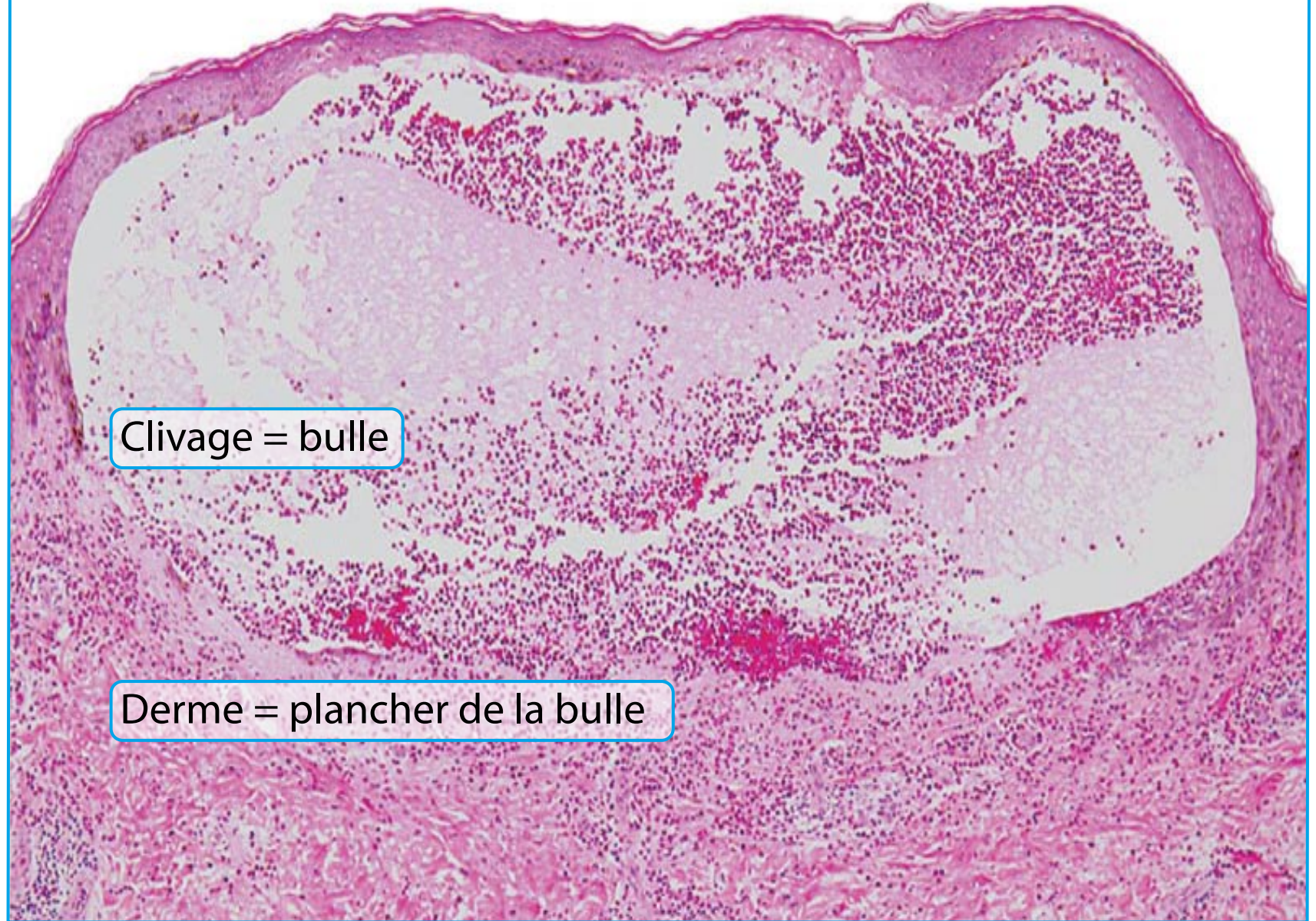


Bulle sous-épidermique



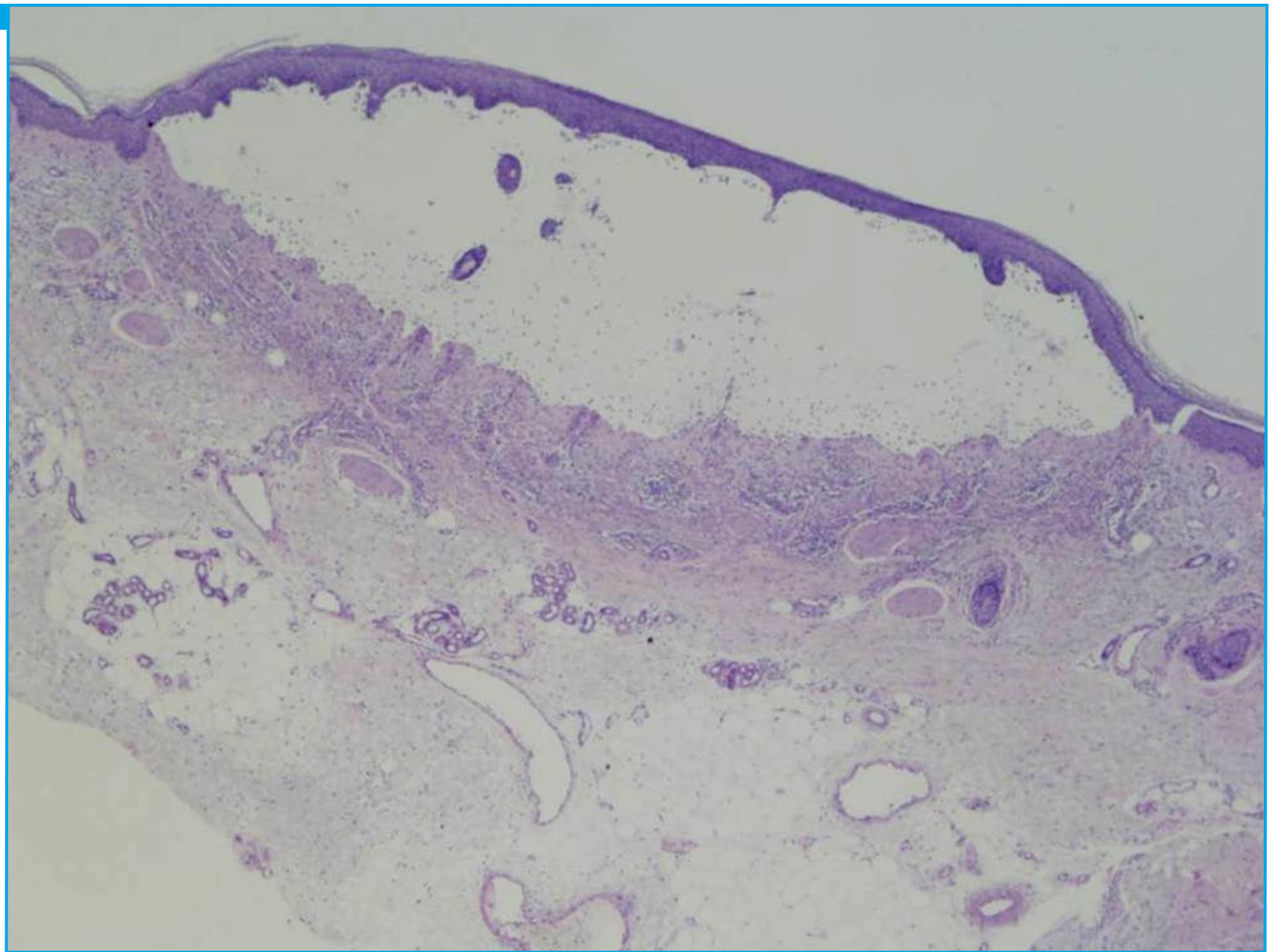
Clivage sous-épidermique

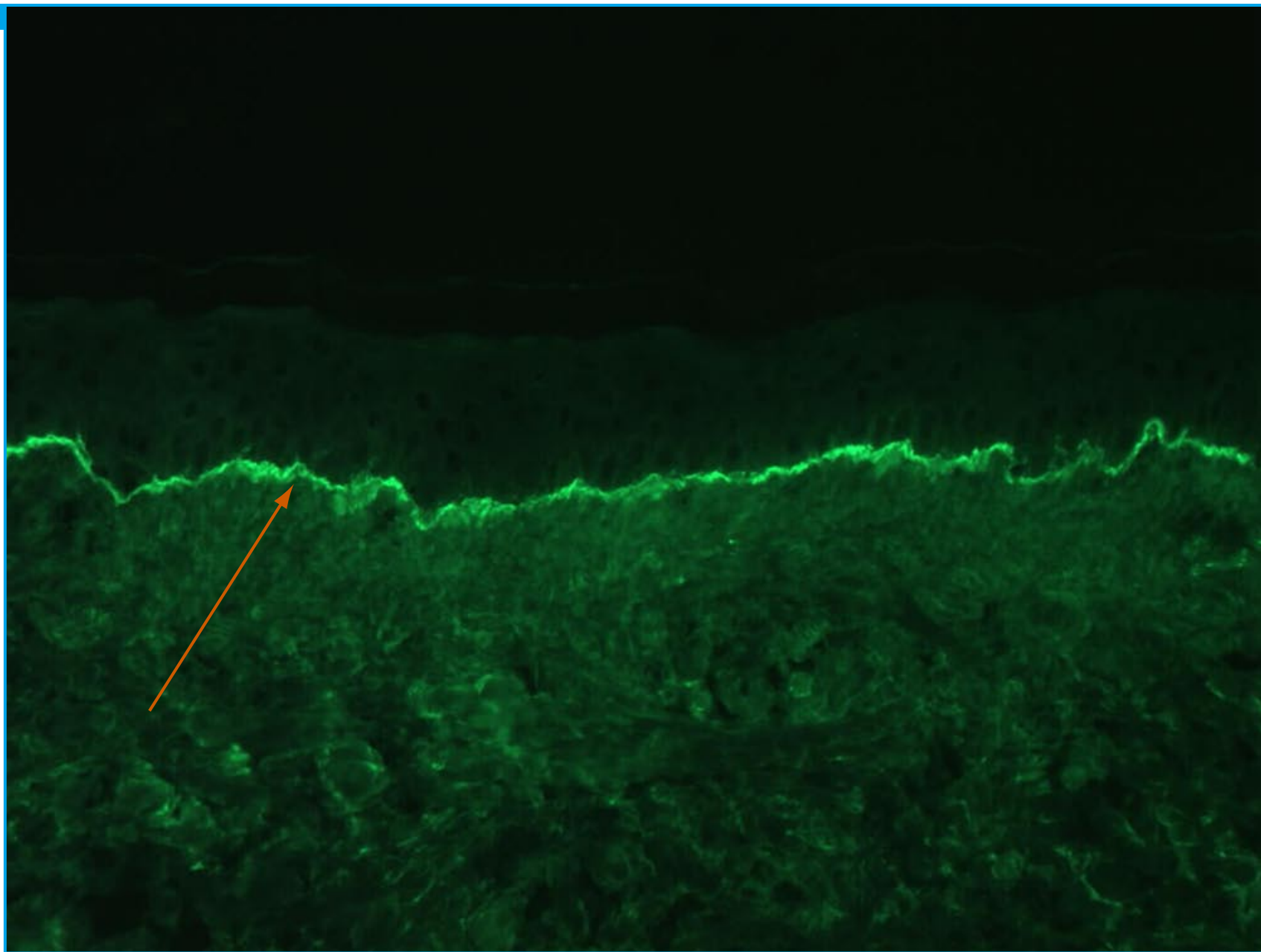
Couche cornée + corps muqueux = toit de la bulle



Clivage = bulle

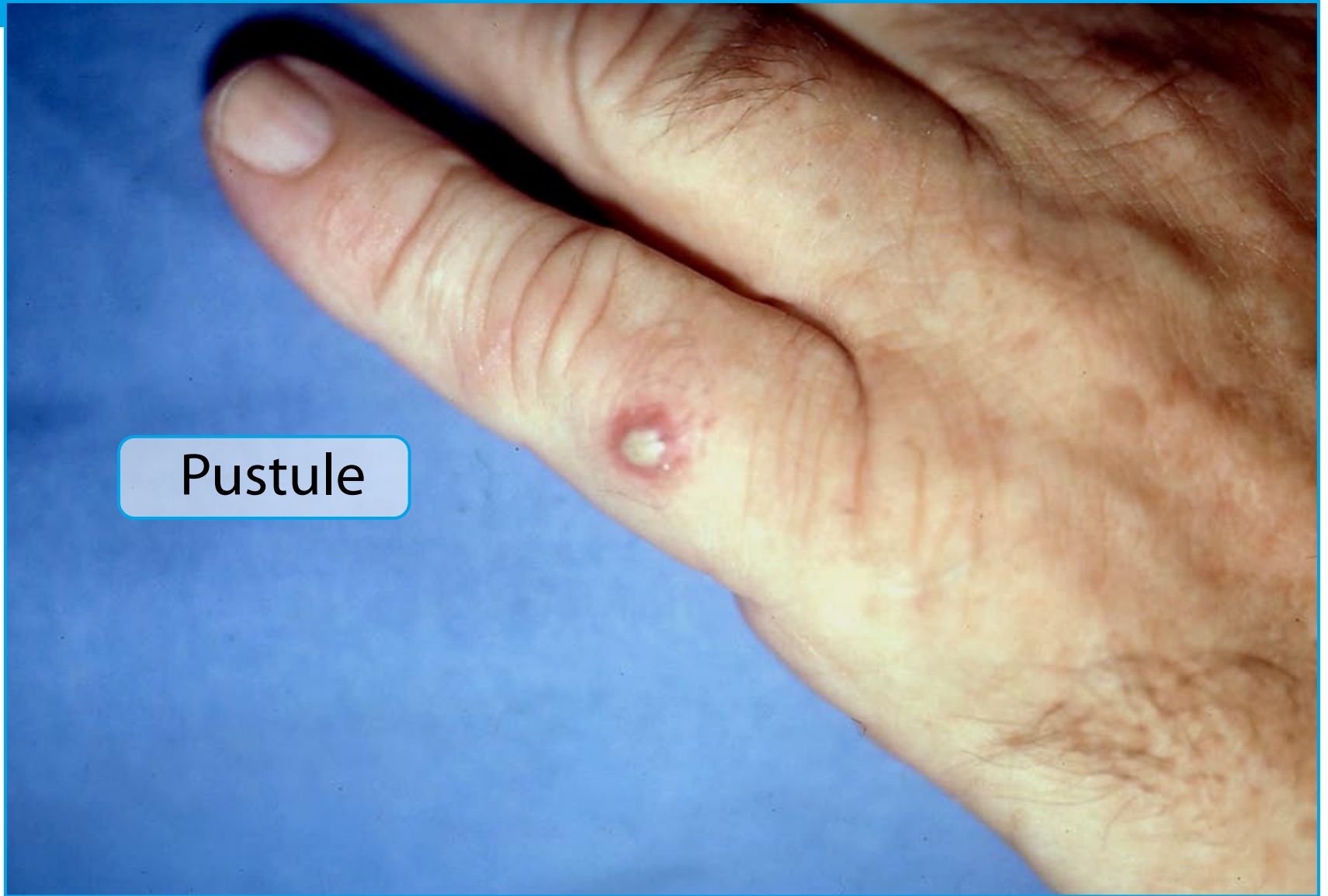Derme = plancher de la bulle



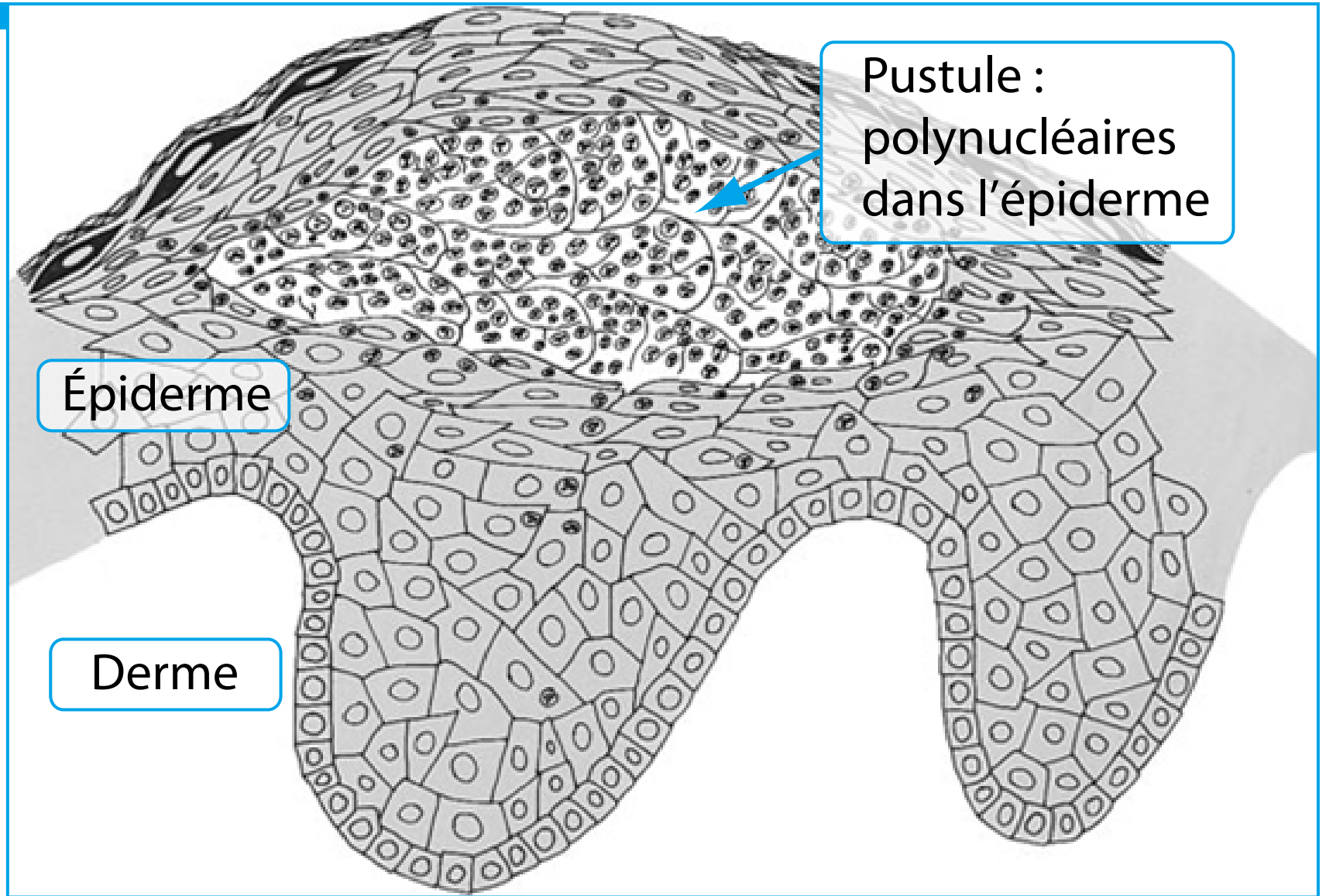


■ Immunofluorescence directe

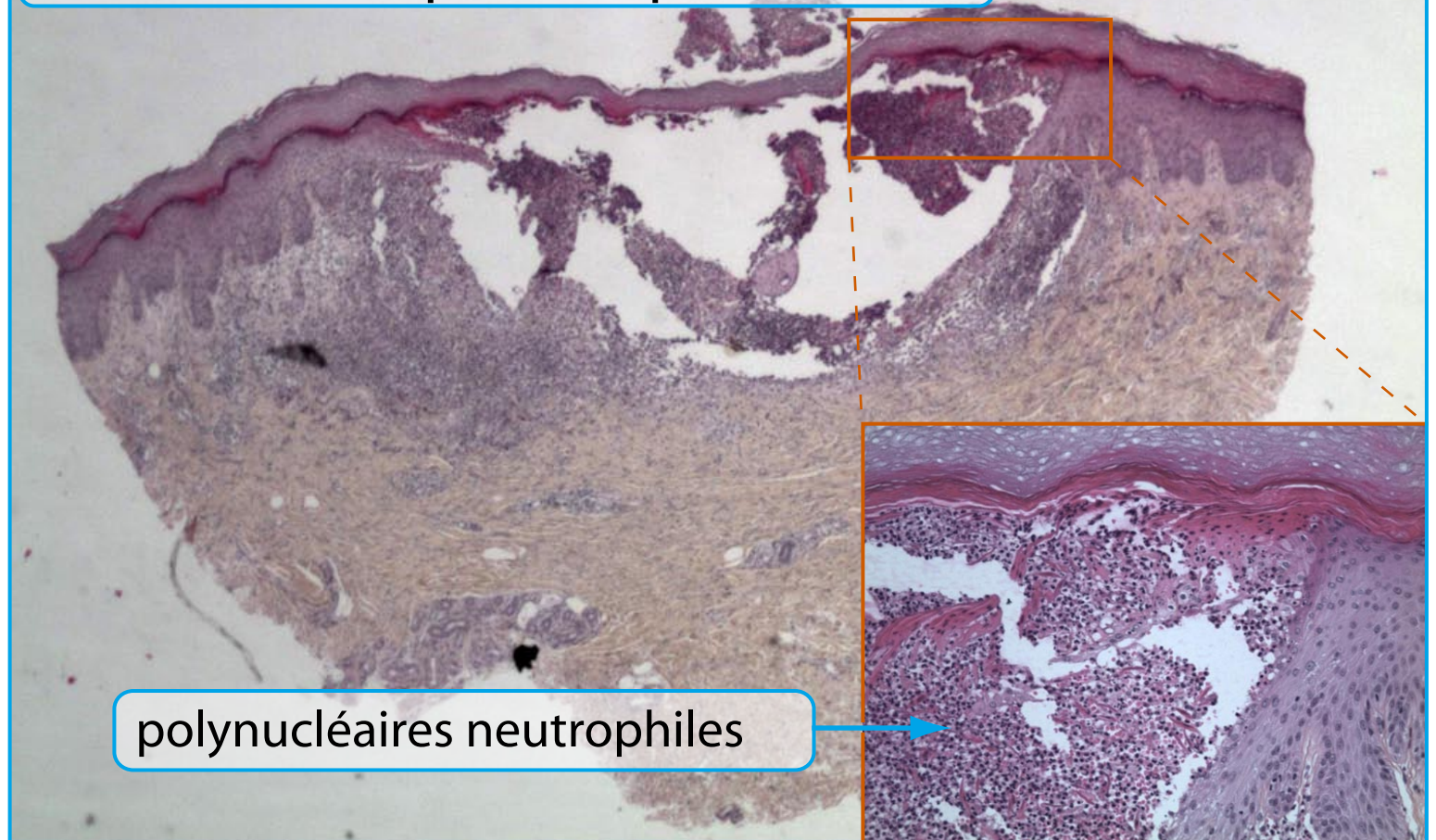
■ Revêtement cutané



Pustule



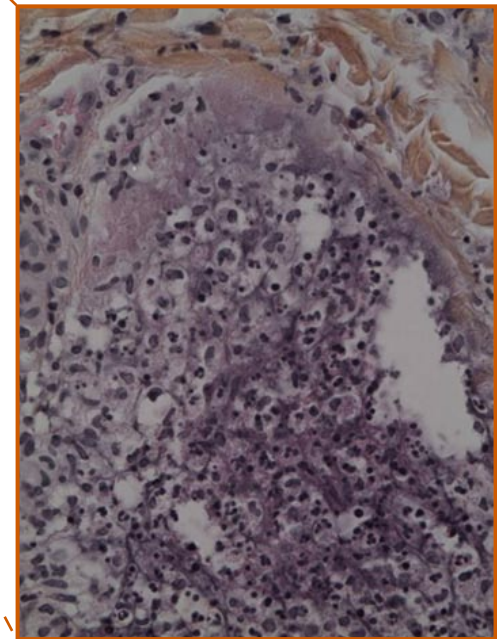
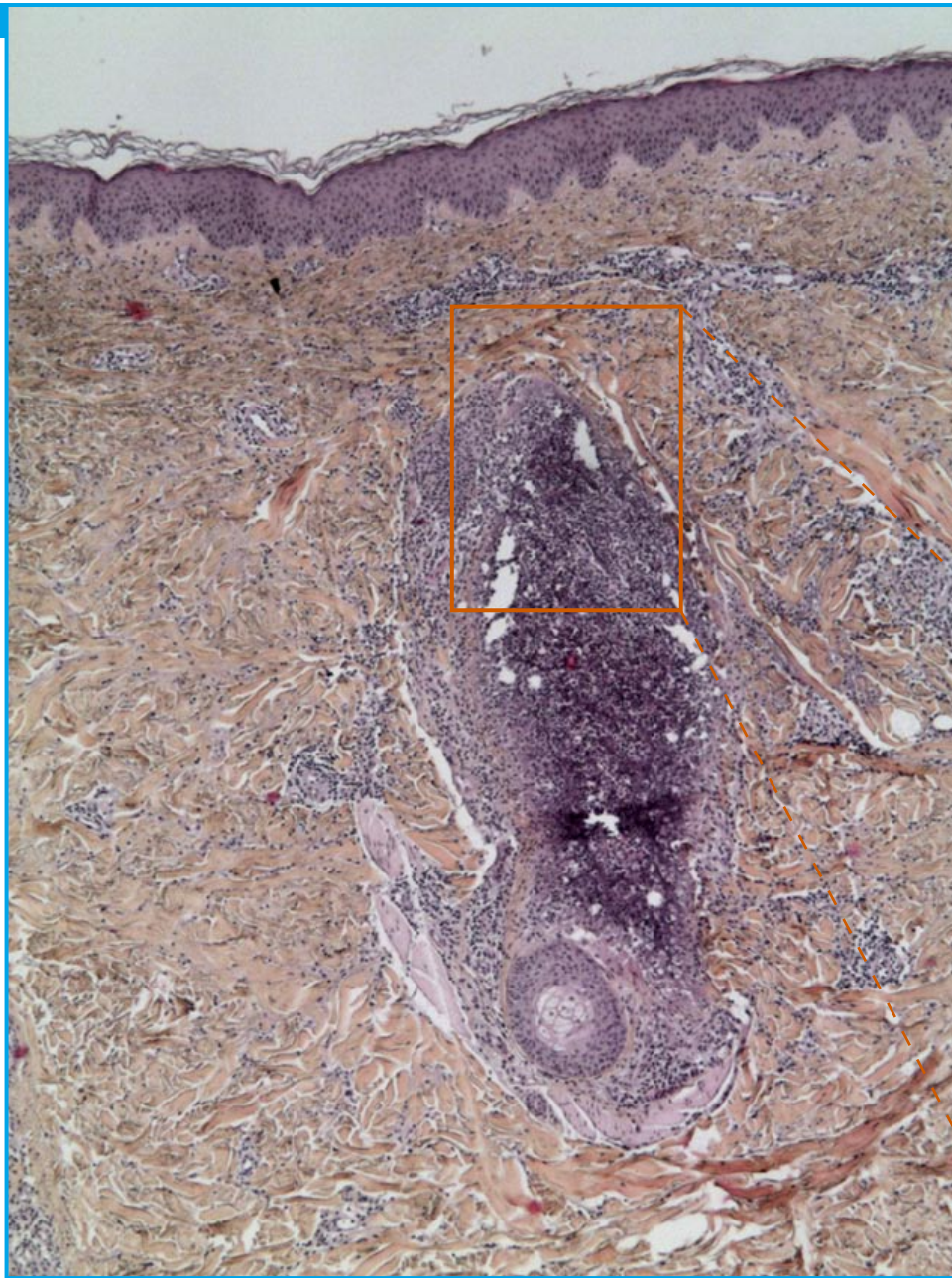Pustule : nombreux polynucléaires neutrophiles dans une ou plusieurs cavités intra épidermiques



polynucléaires neutrophiles



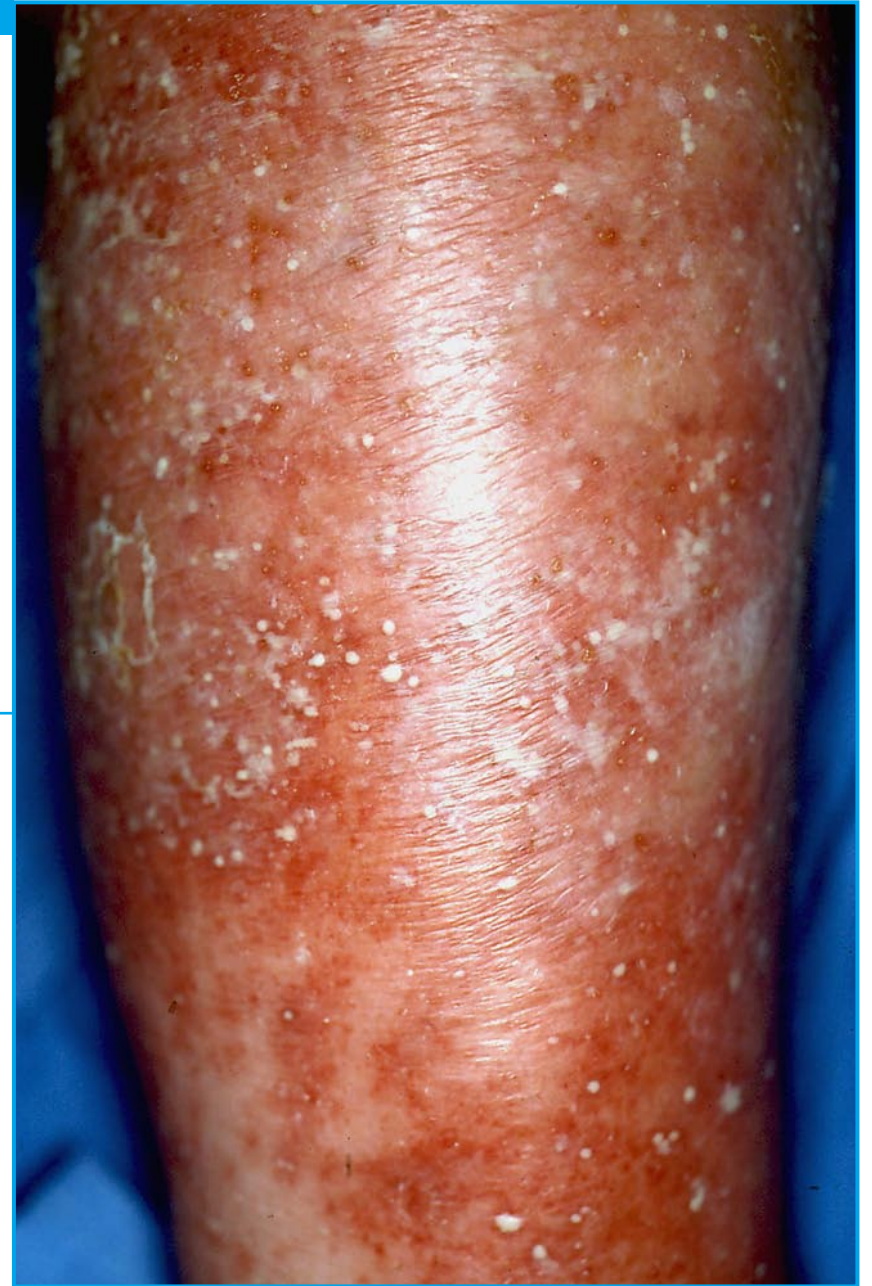Pustule folliculaire

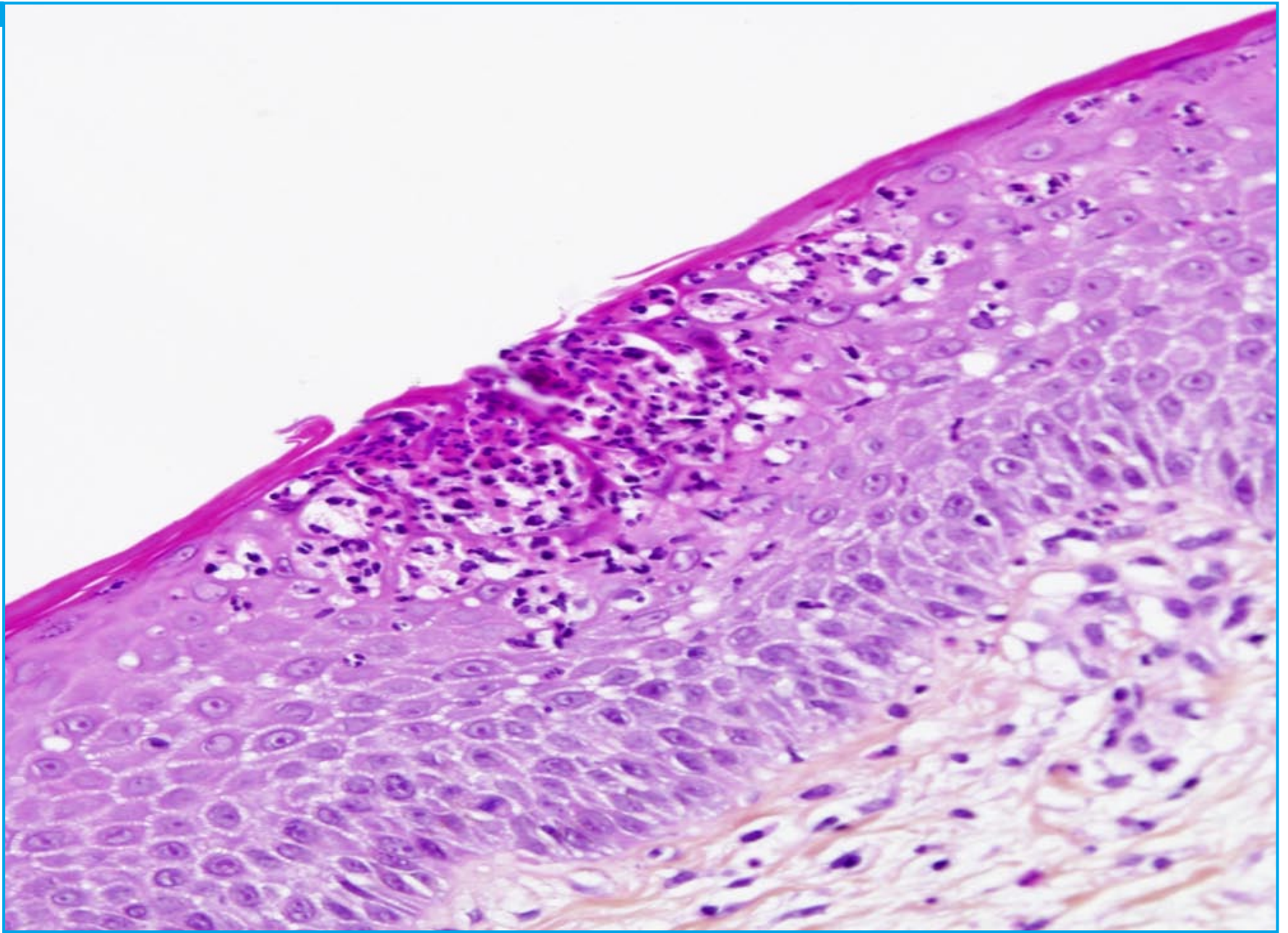


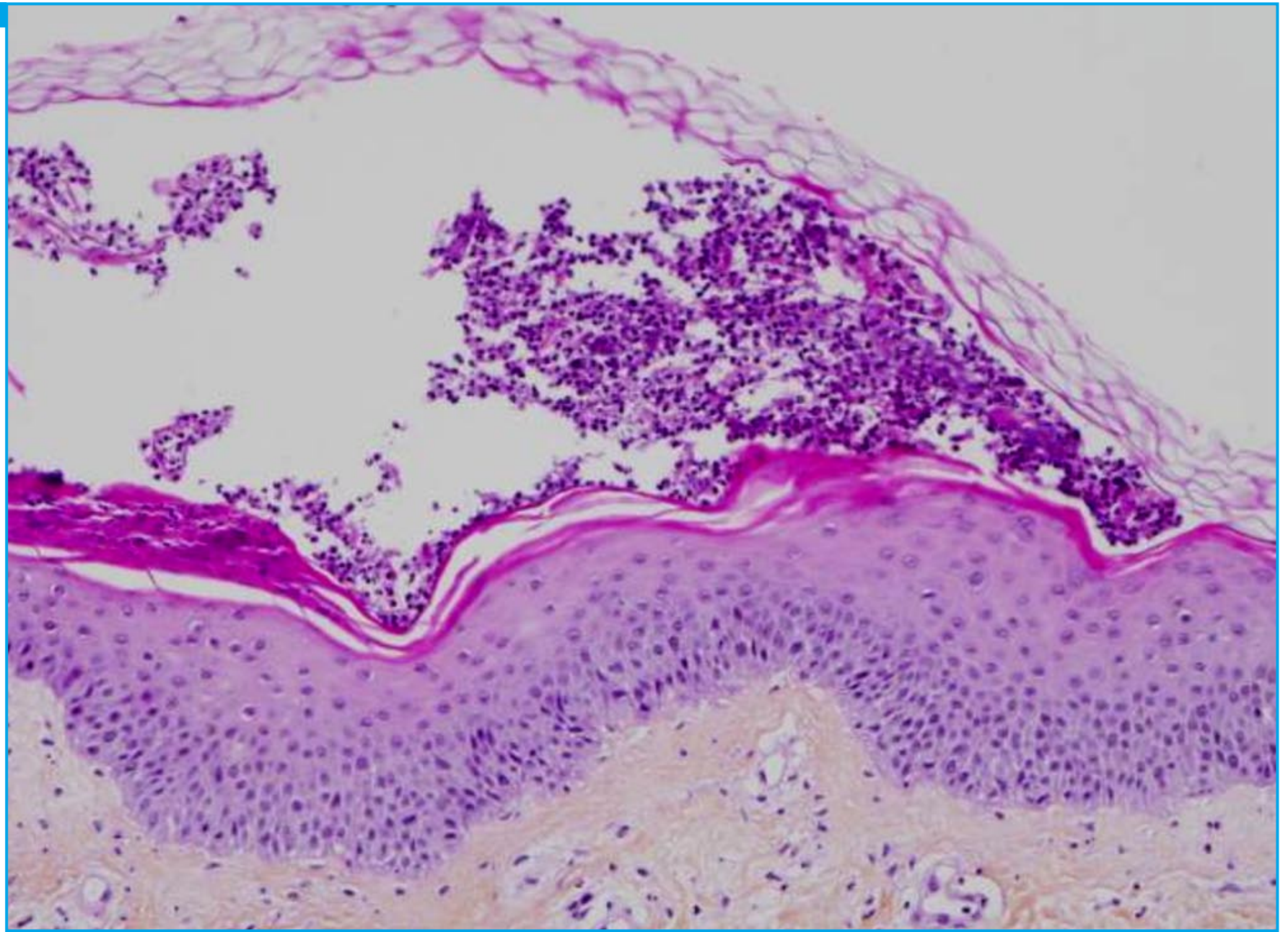
■ Pustule dans un follicule pilo-sébacé : folliculite

■ Revêtement cutané

■ Pustule non-folliculaire

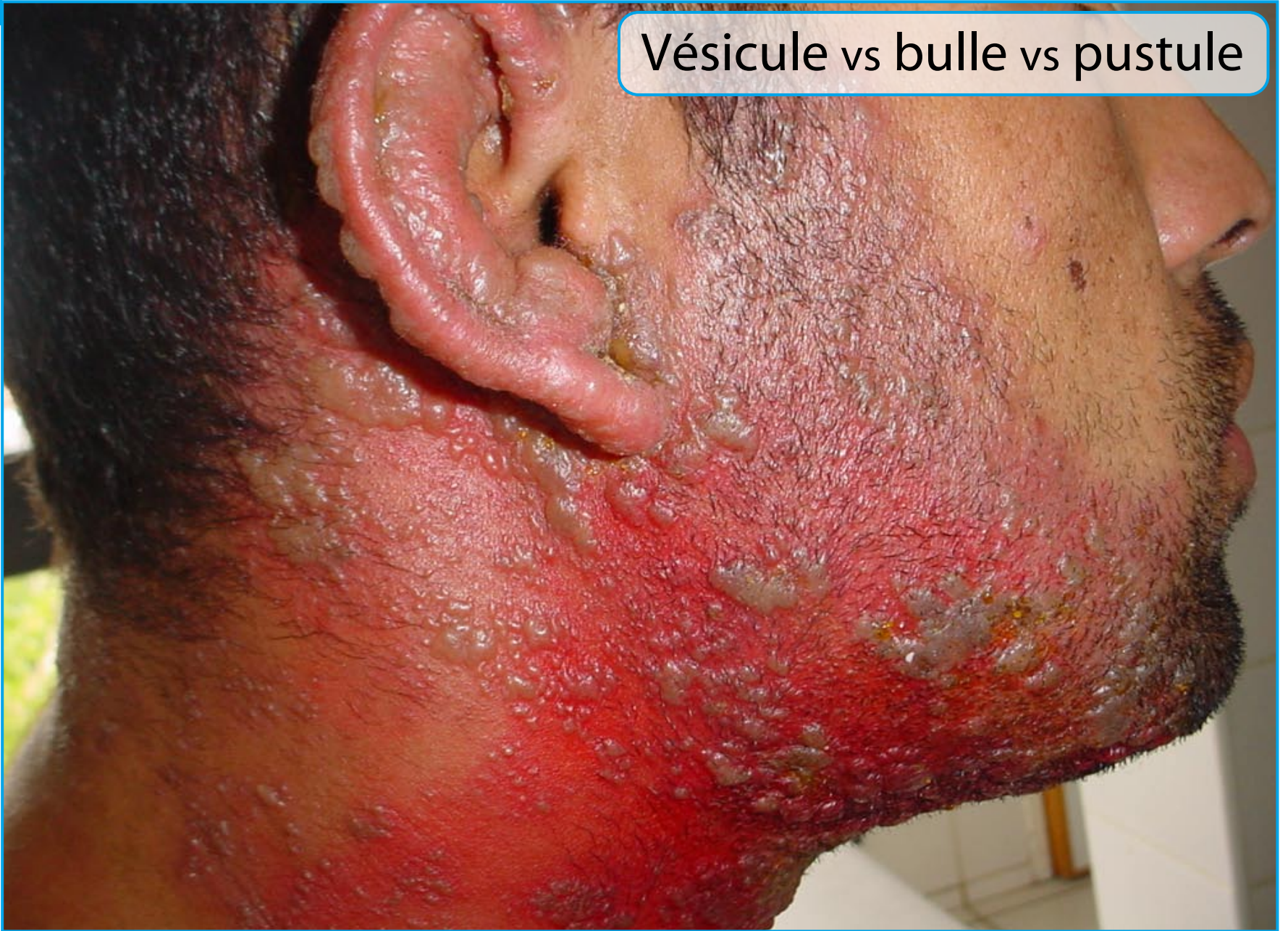




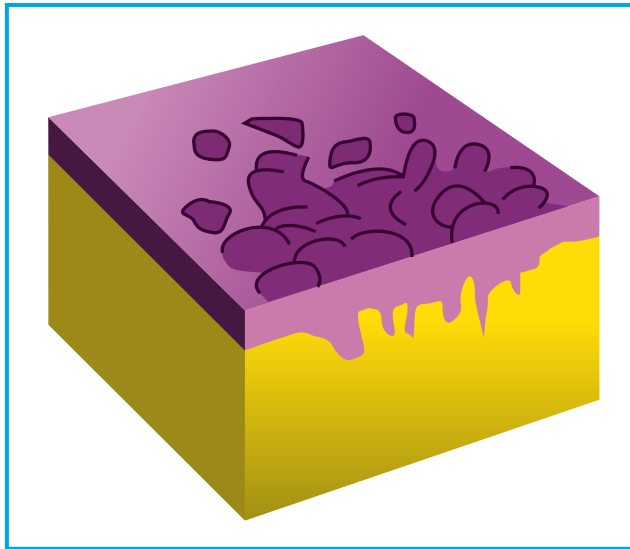


Pustule

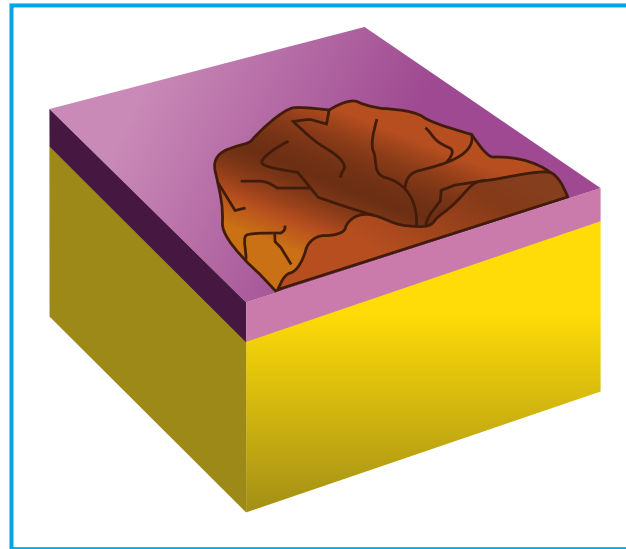
Vésicule vs bulle vs pustule



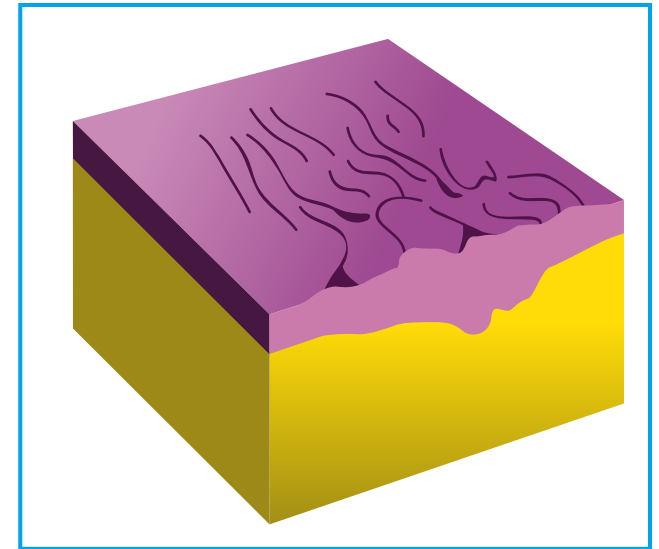
Lésions tissulaires secondaires



Squame

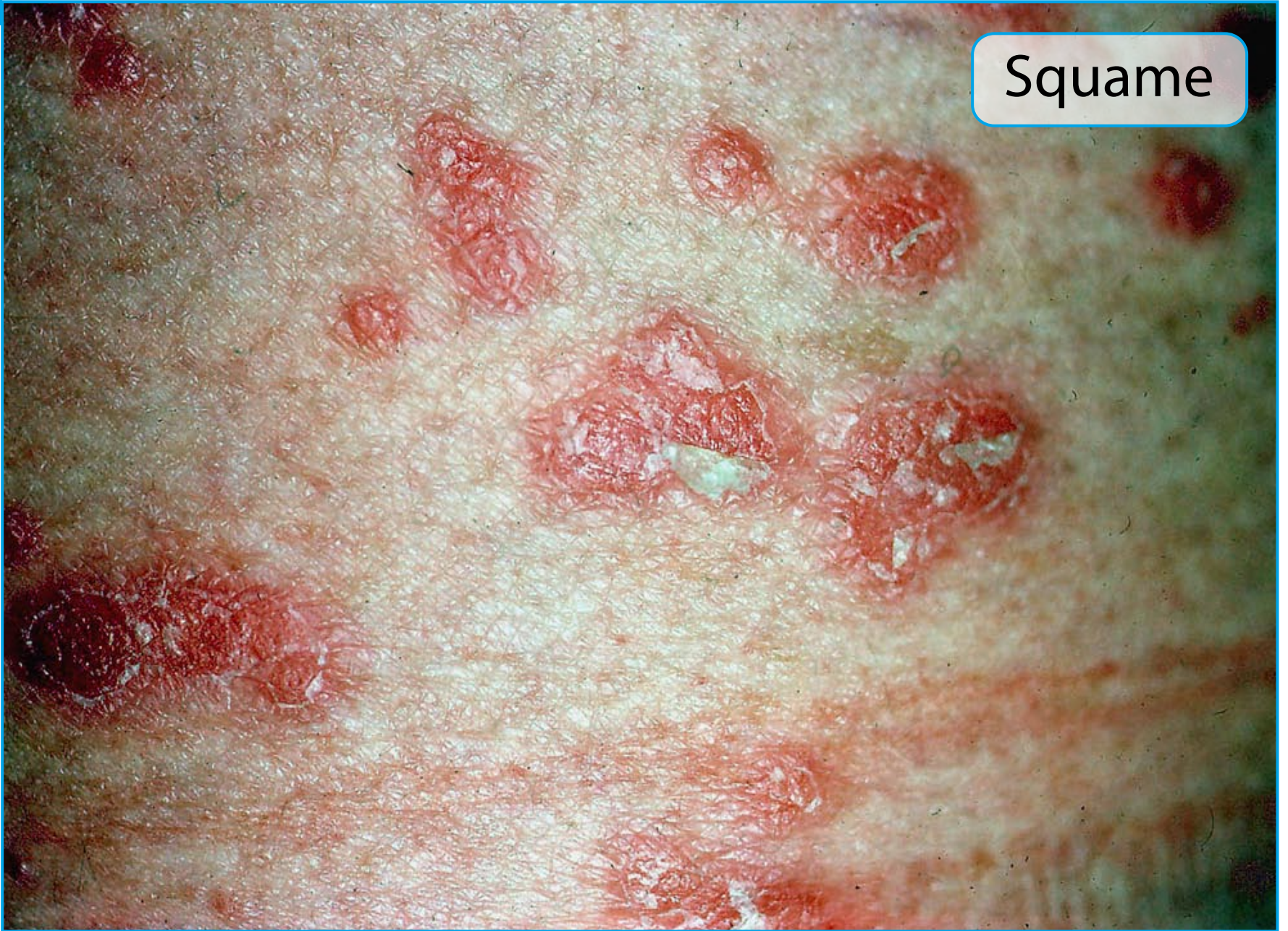

Lichenification

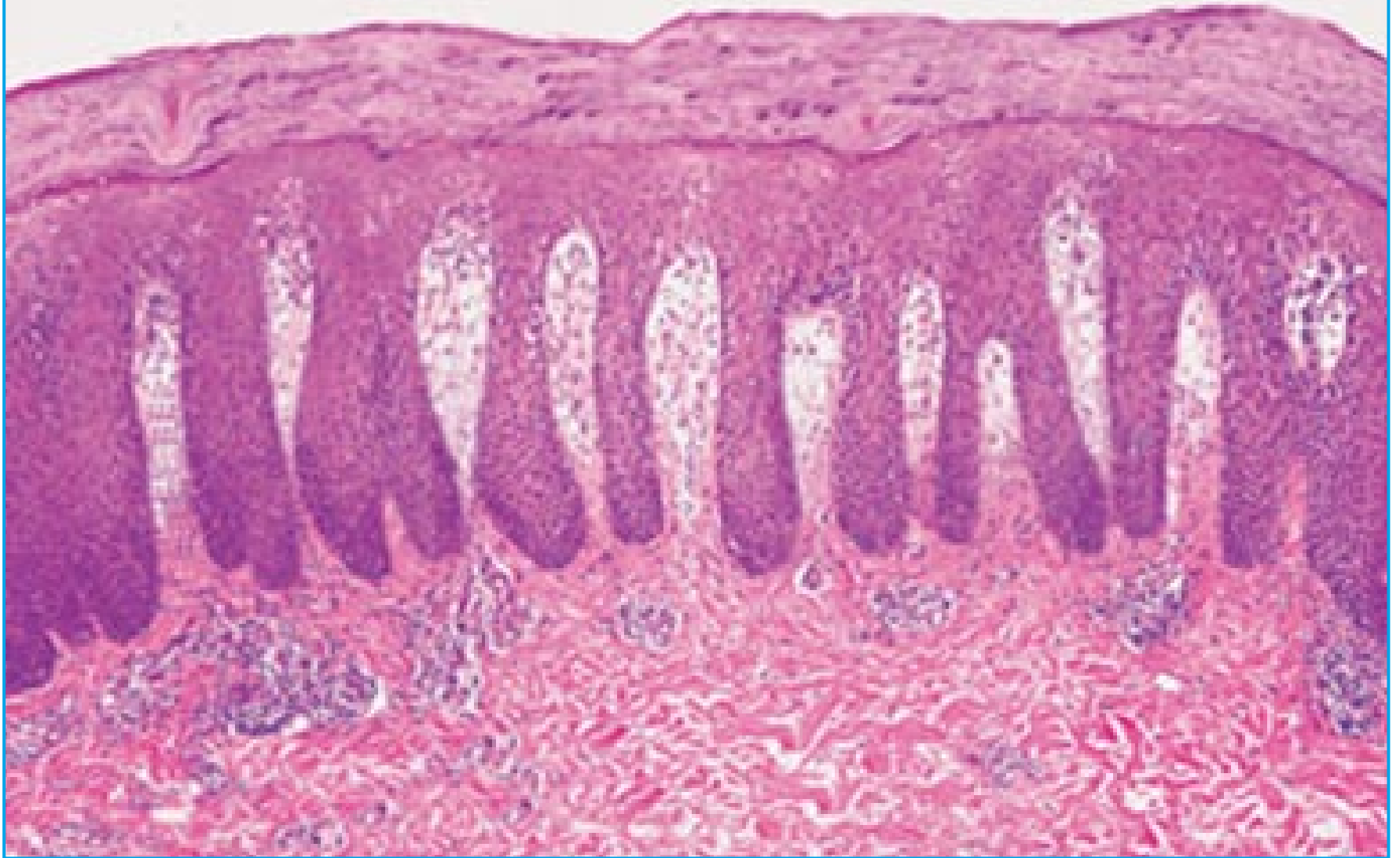


Croûte

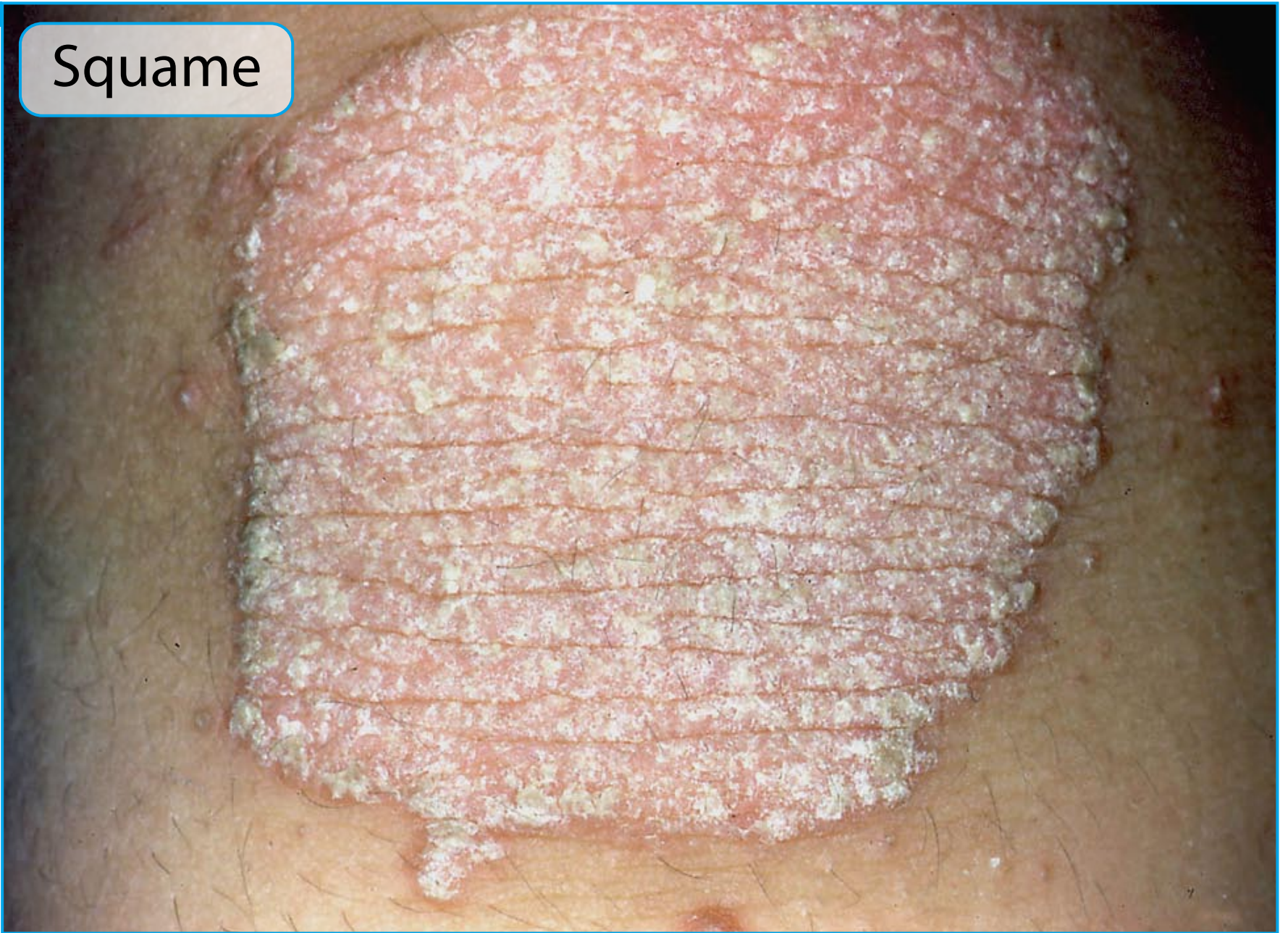Squame

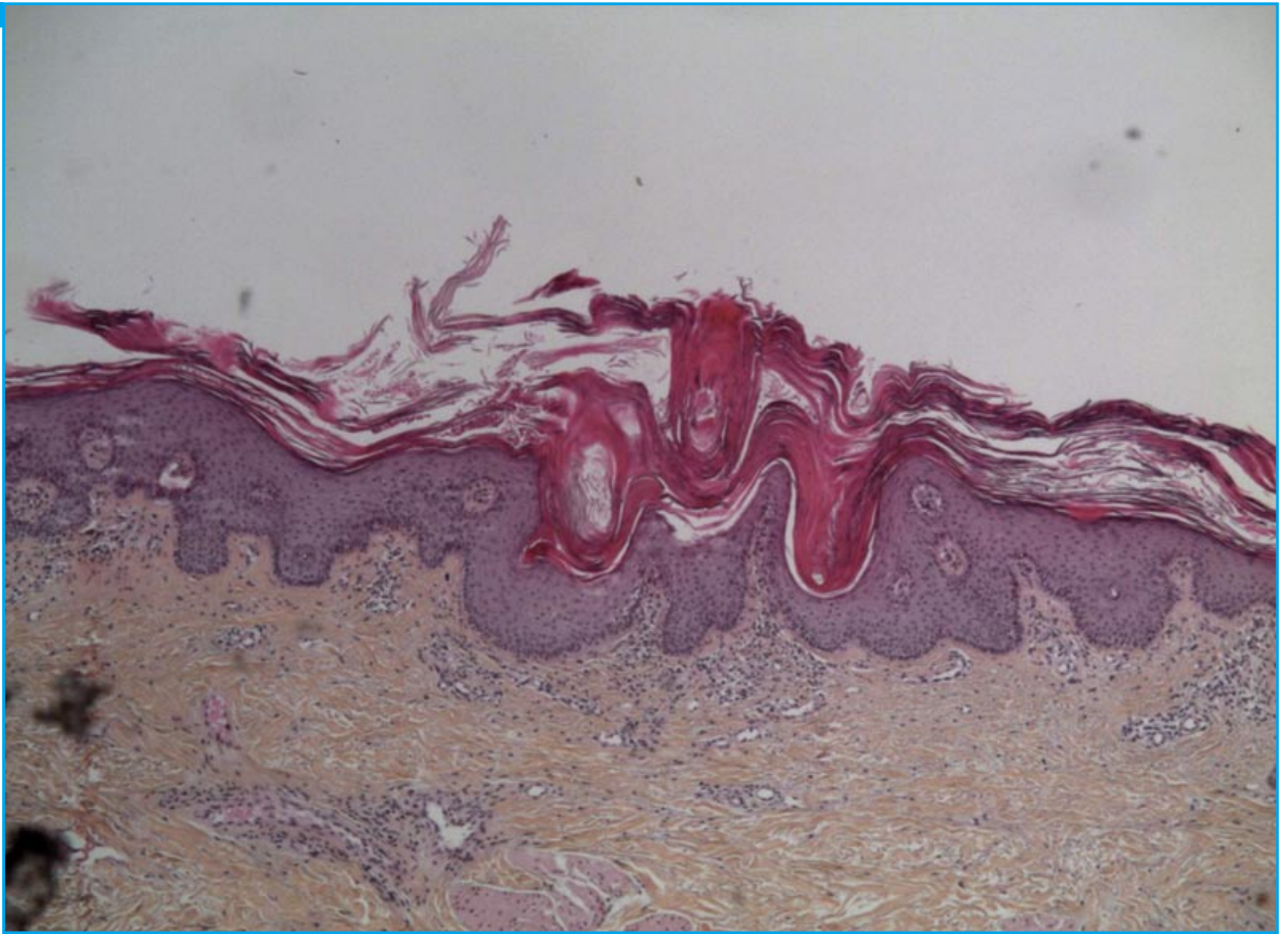


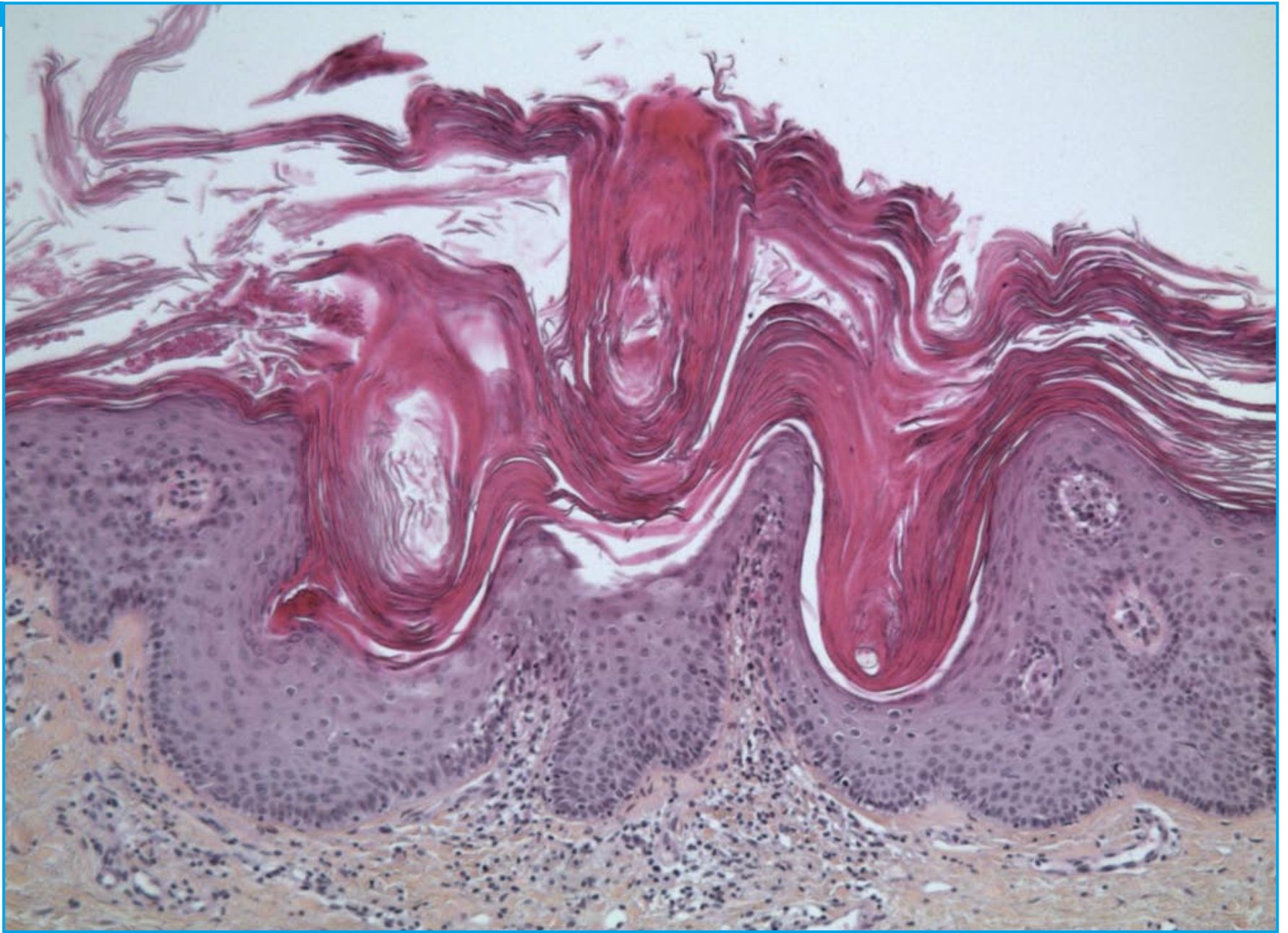
Épaississement de la couche cornée



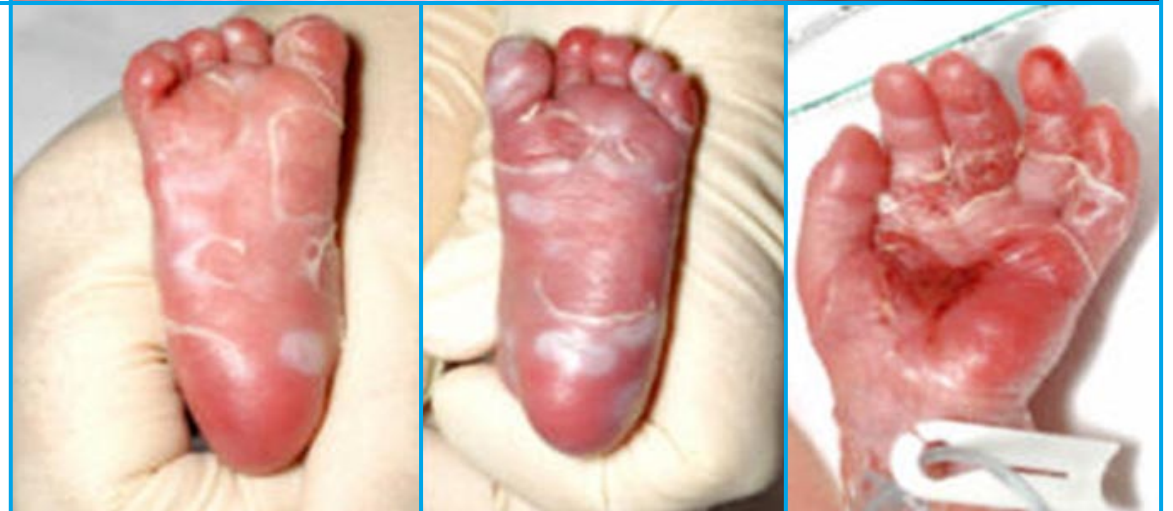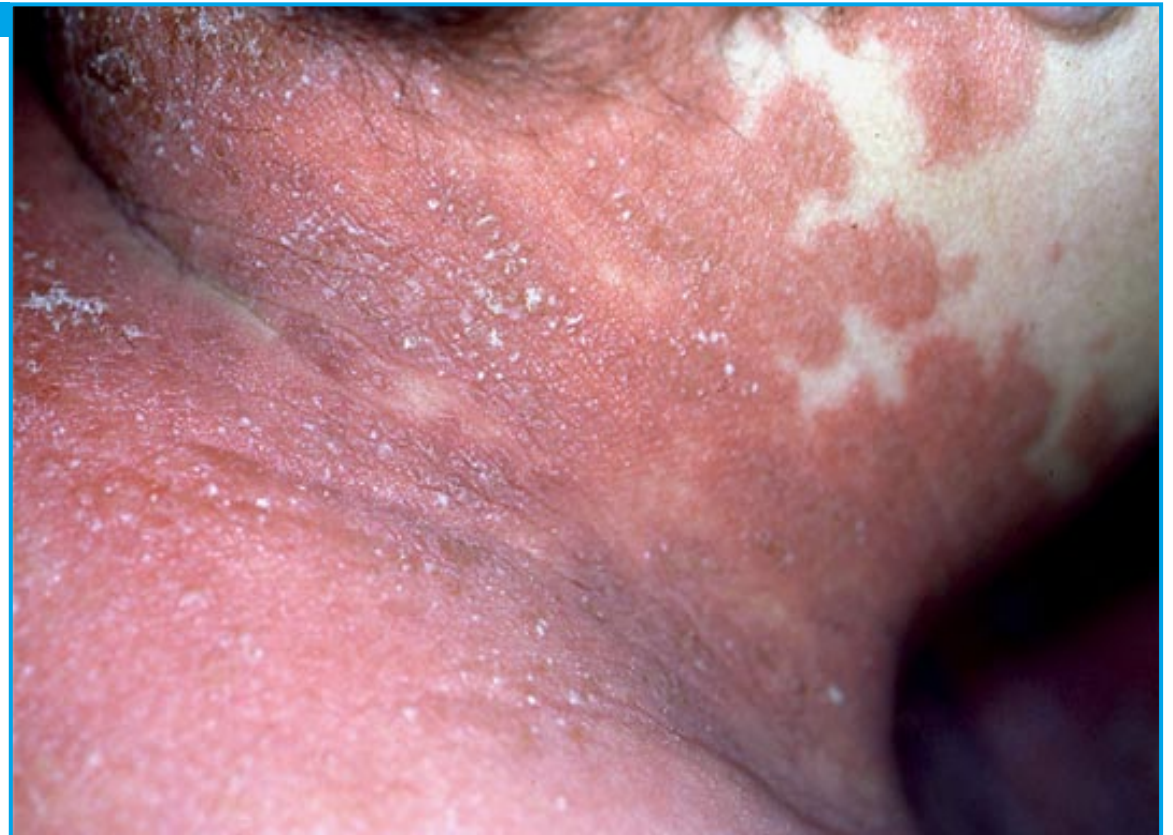Squame



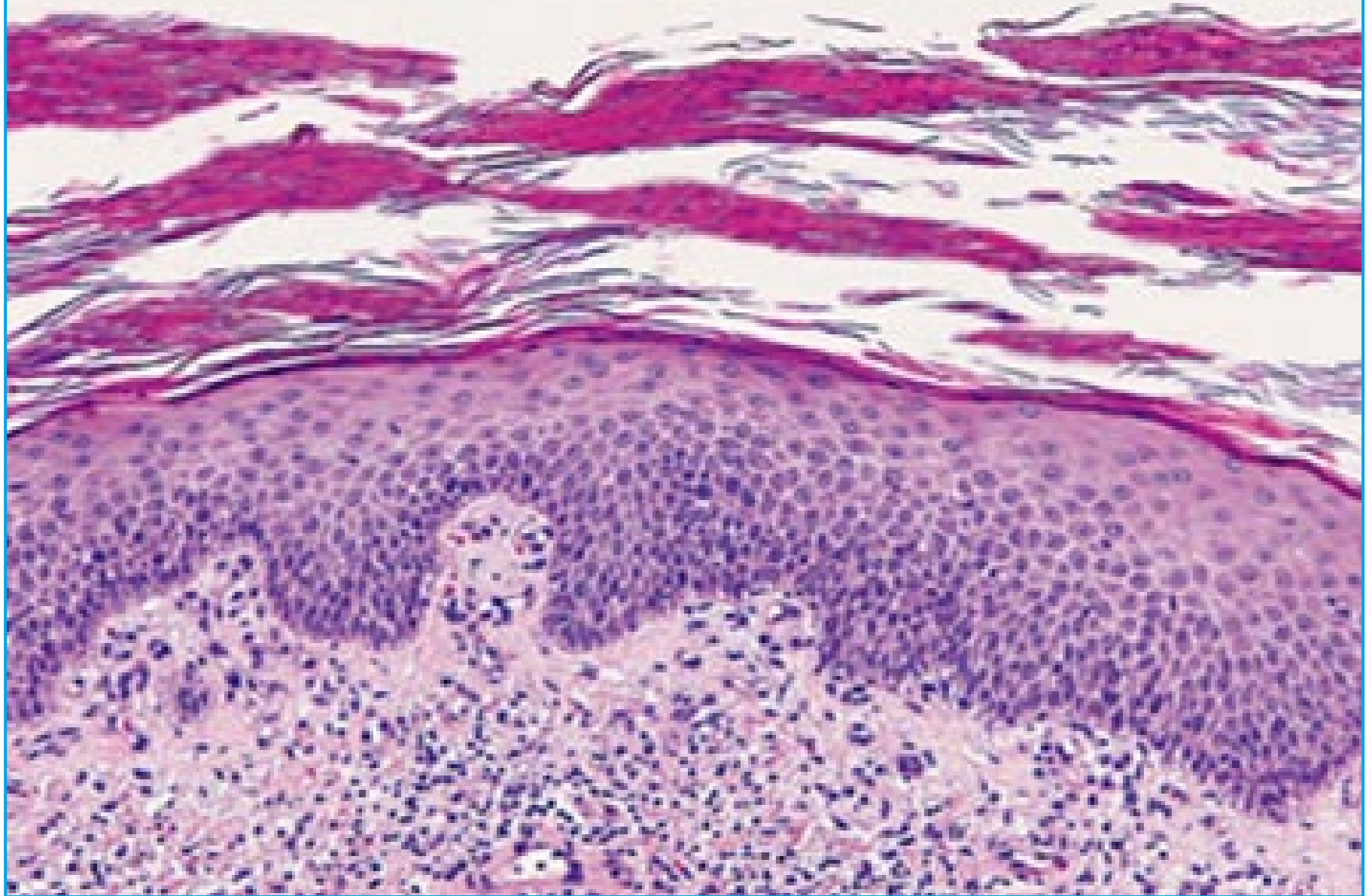


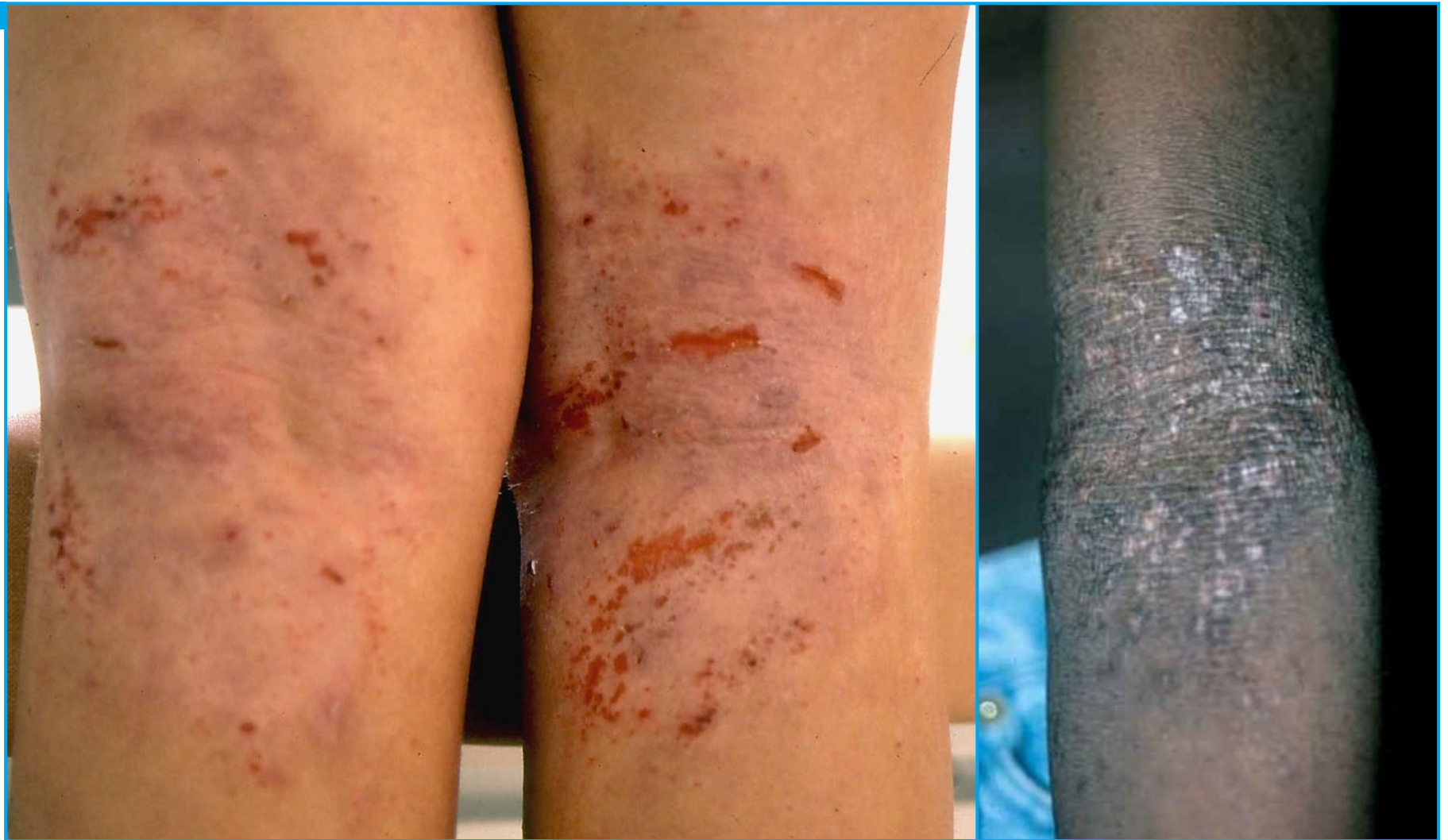


■ Désquamation ▶

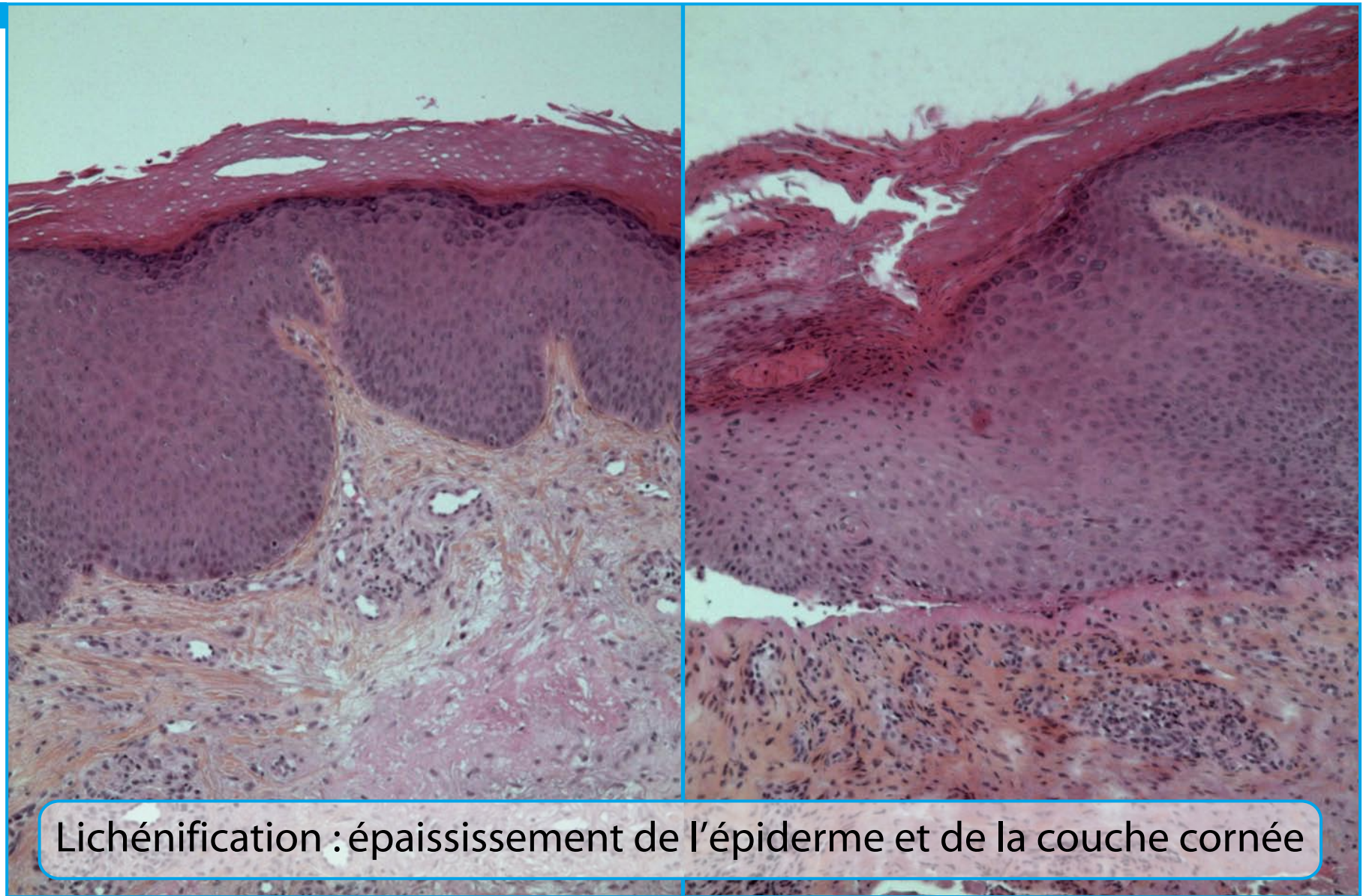


Desquamation : couche cornée épaissie en histologie

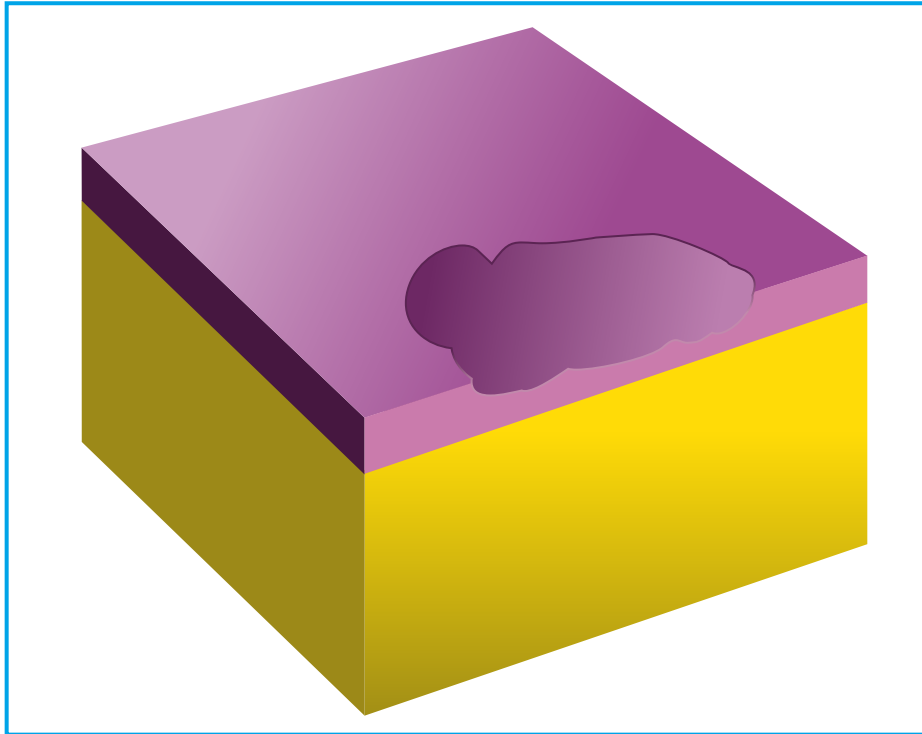





■ Lichenification ▶



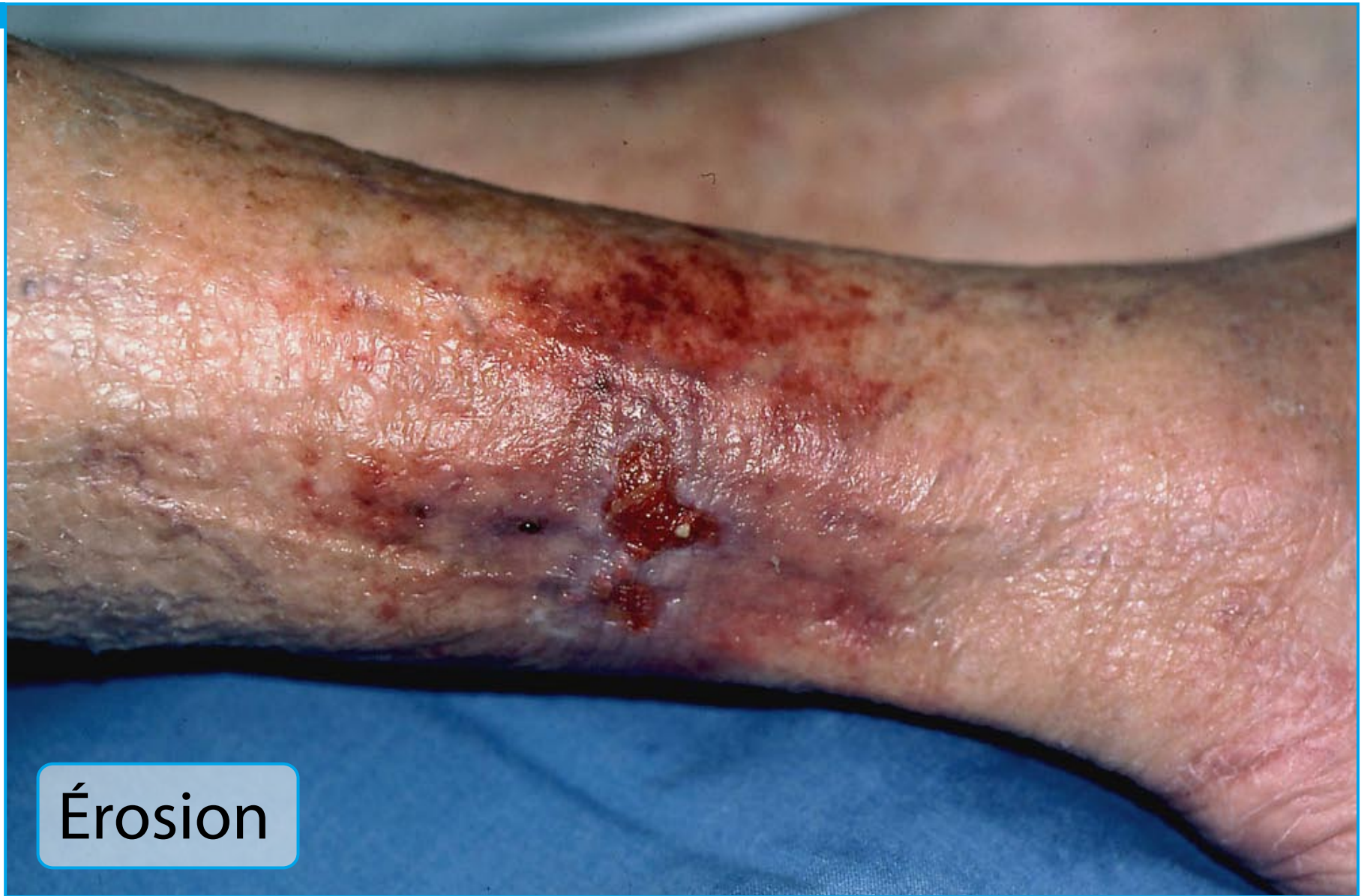Pertes de substance



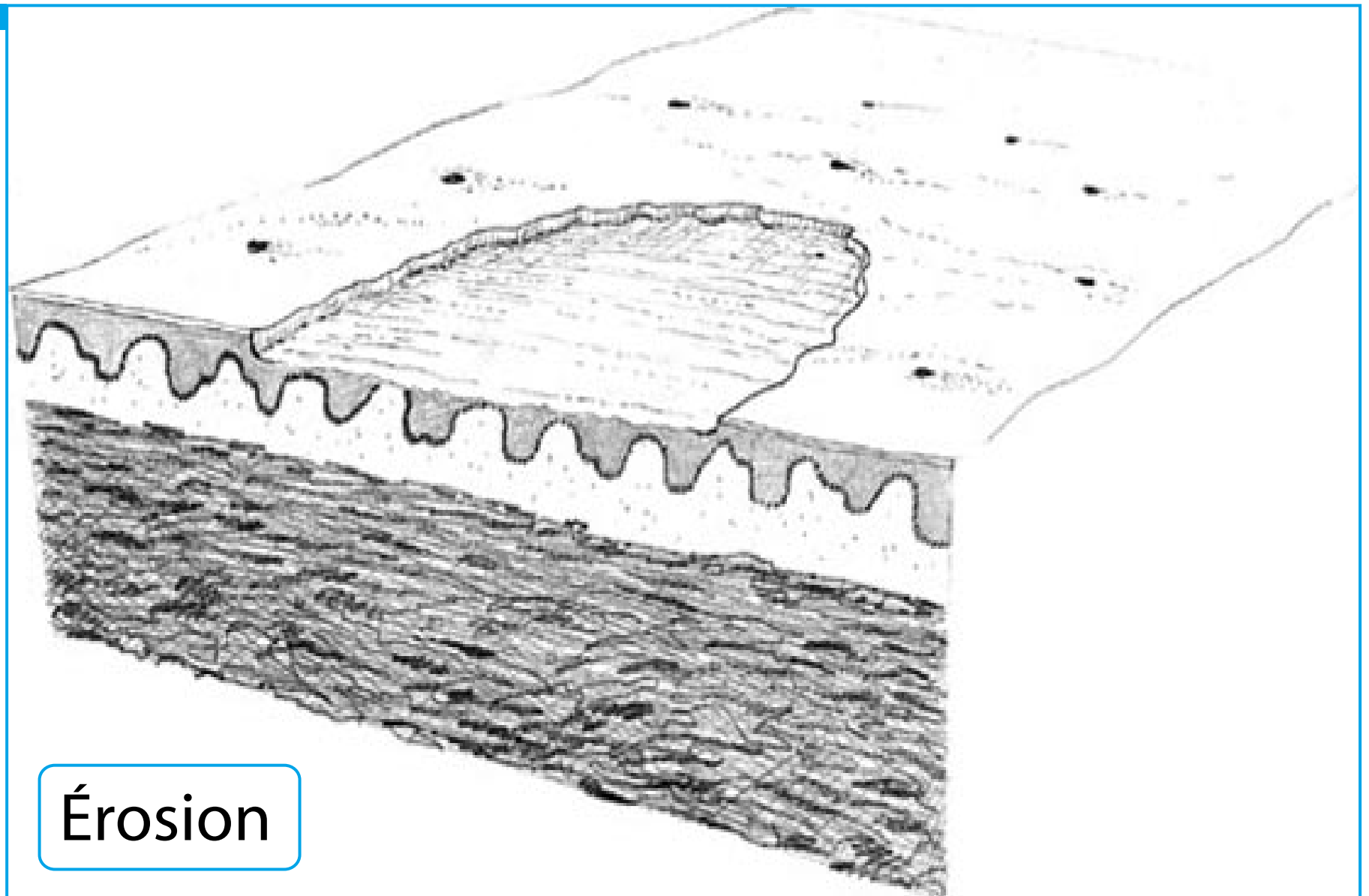
Érosion



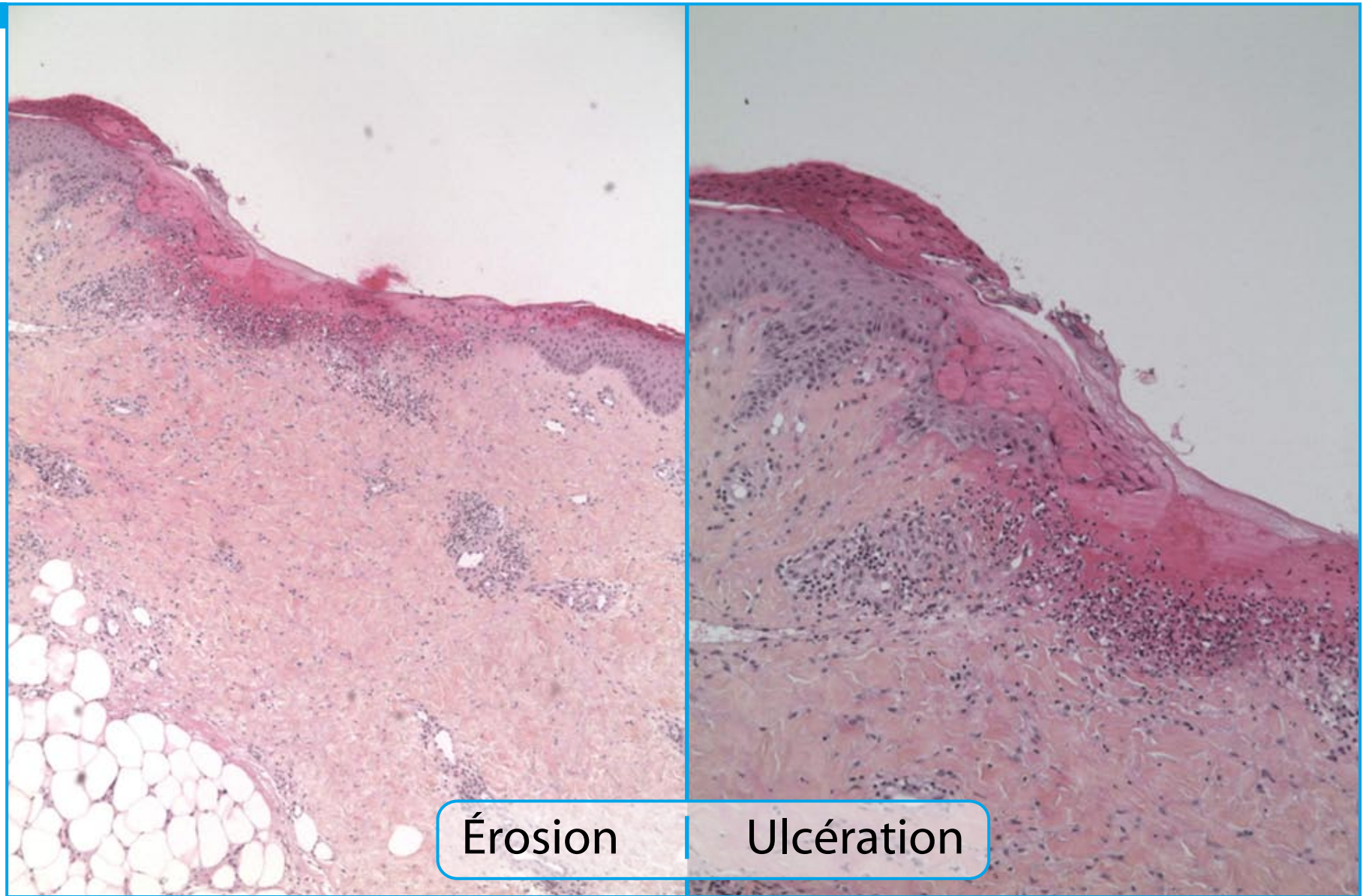
Ulcération

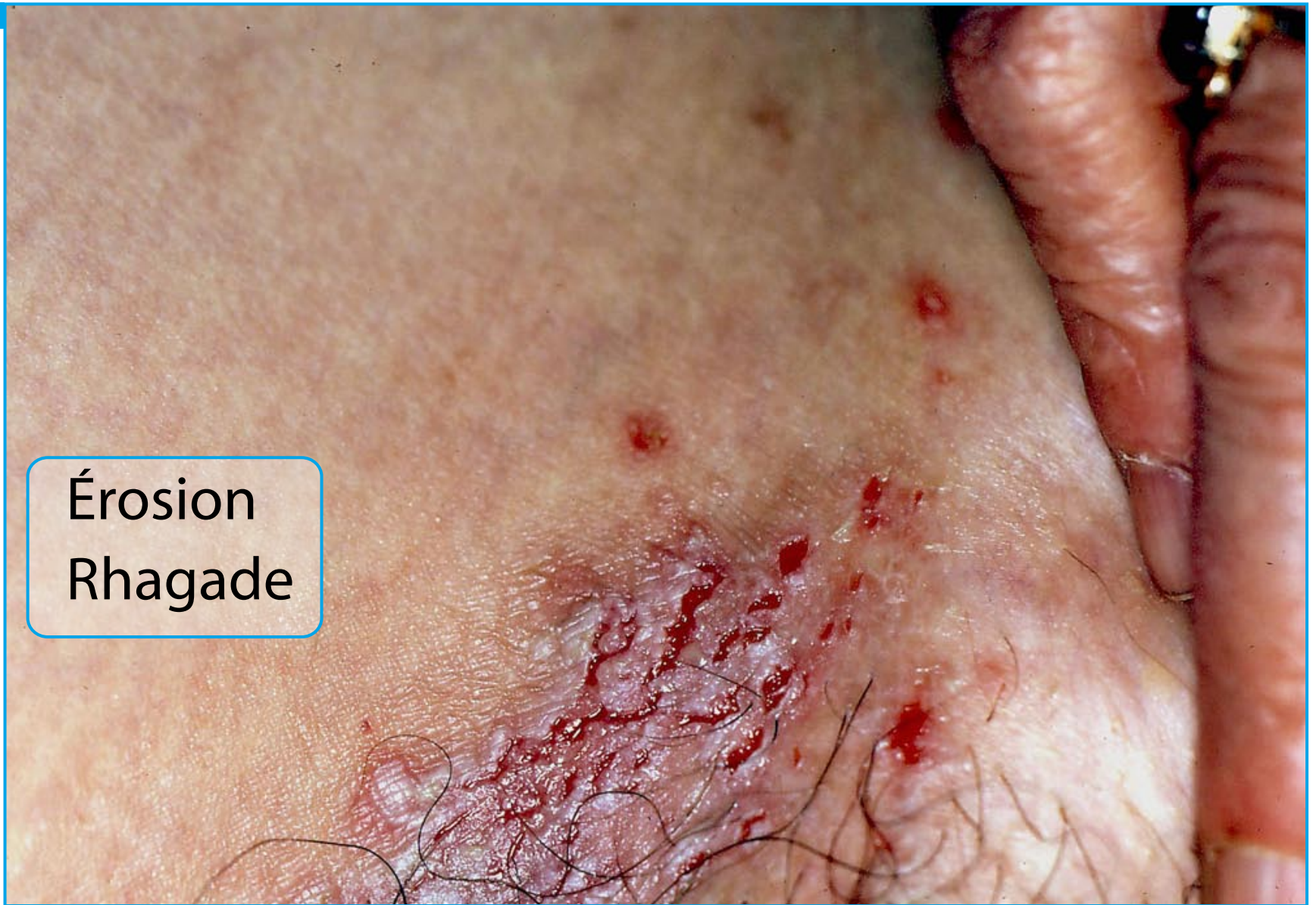

Érosion



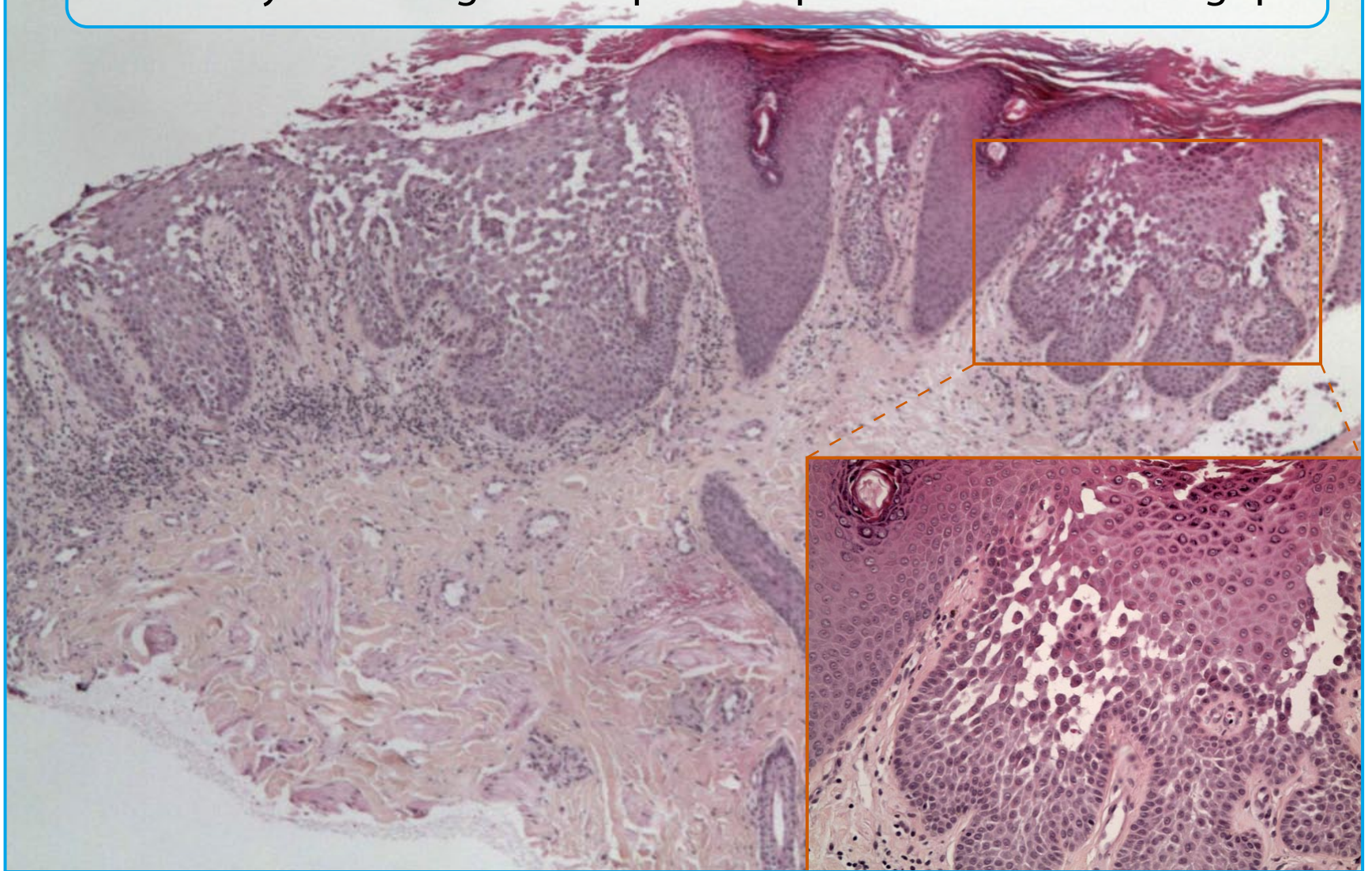
Érosion

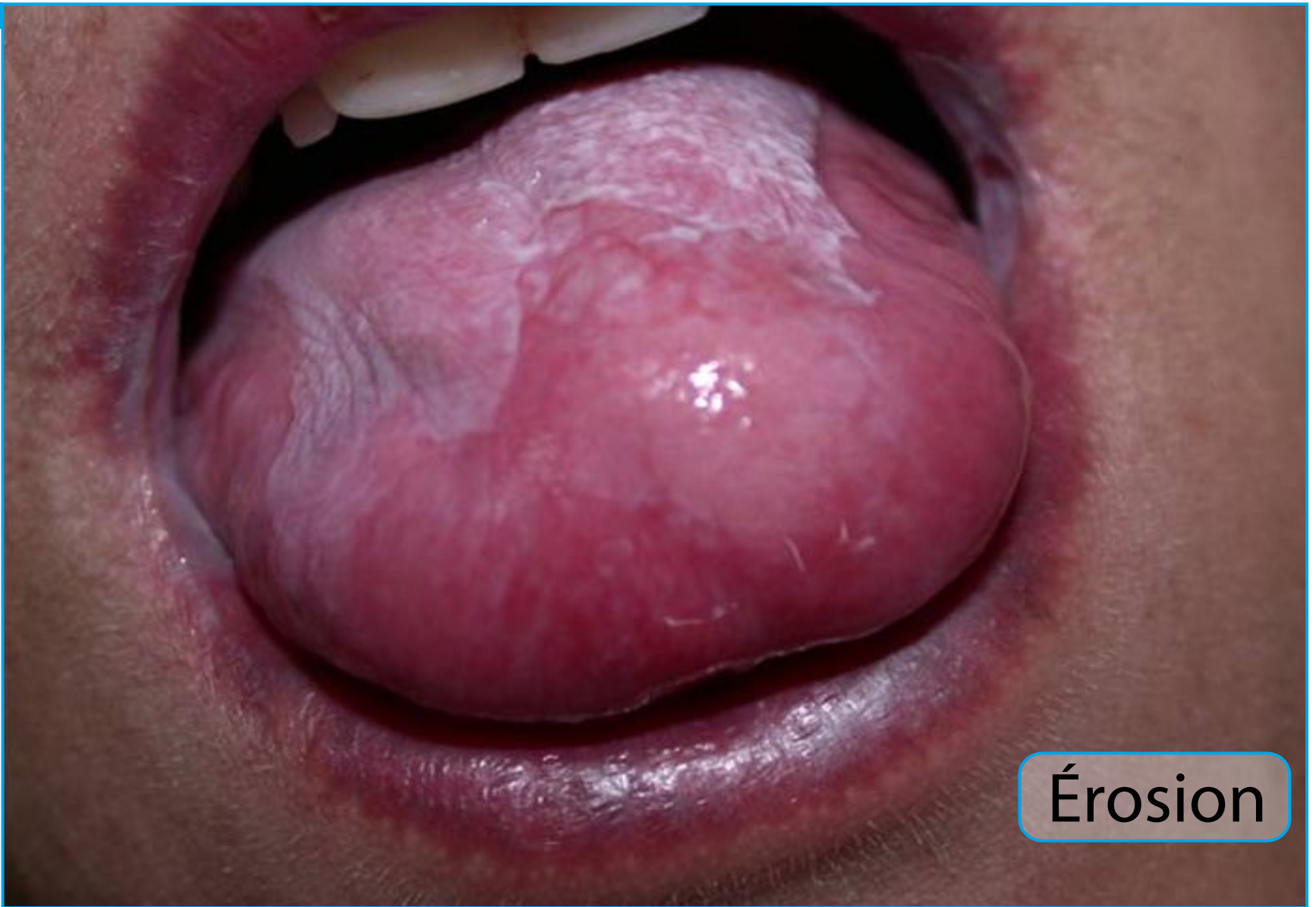



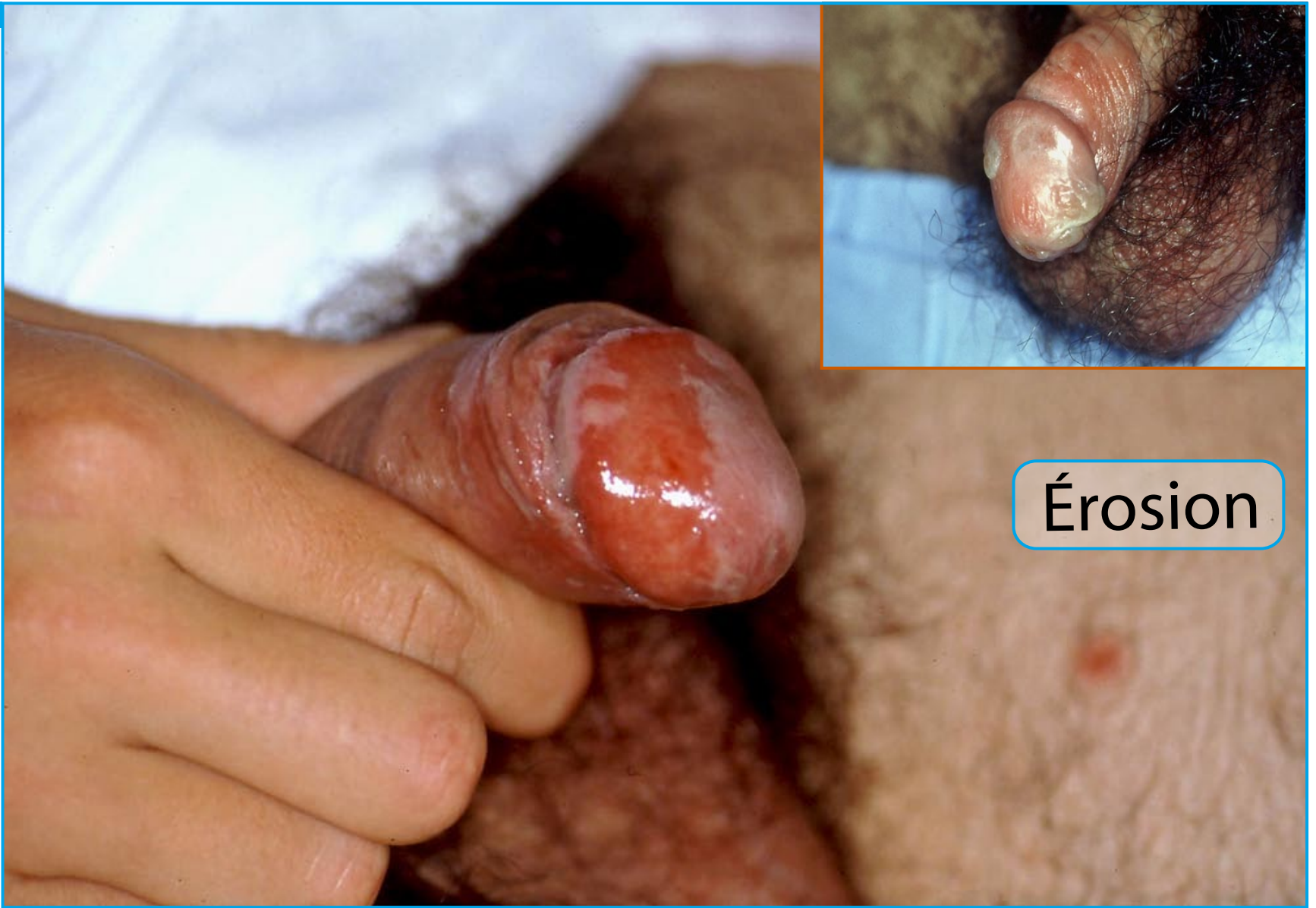Érosion
Rhagade

Acantholyse = clivage intra épidermique à l'examen histologique

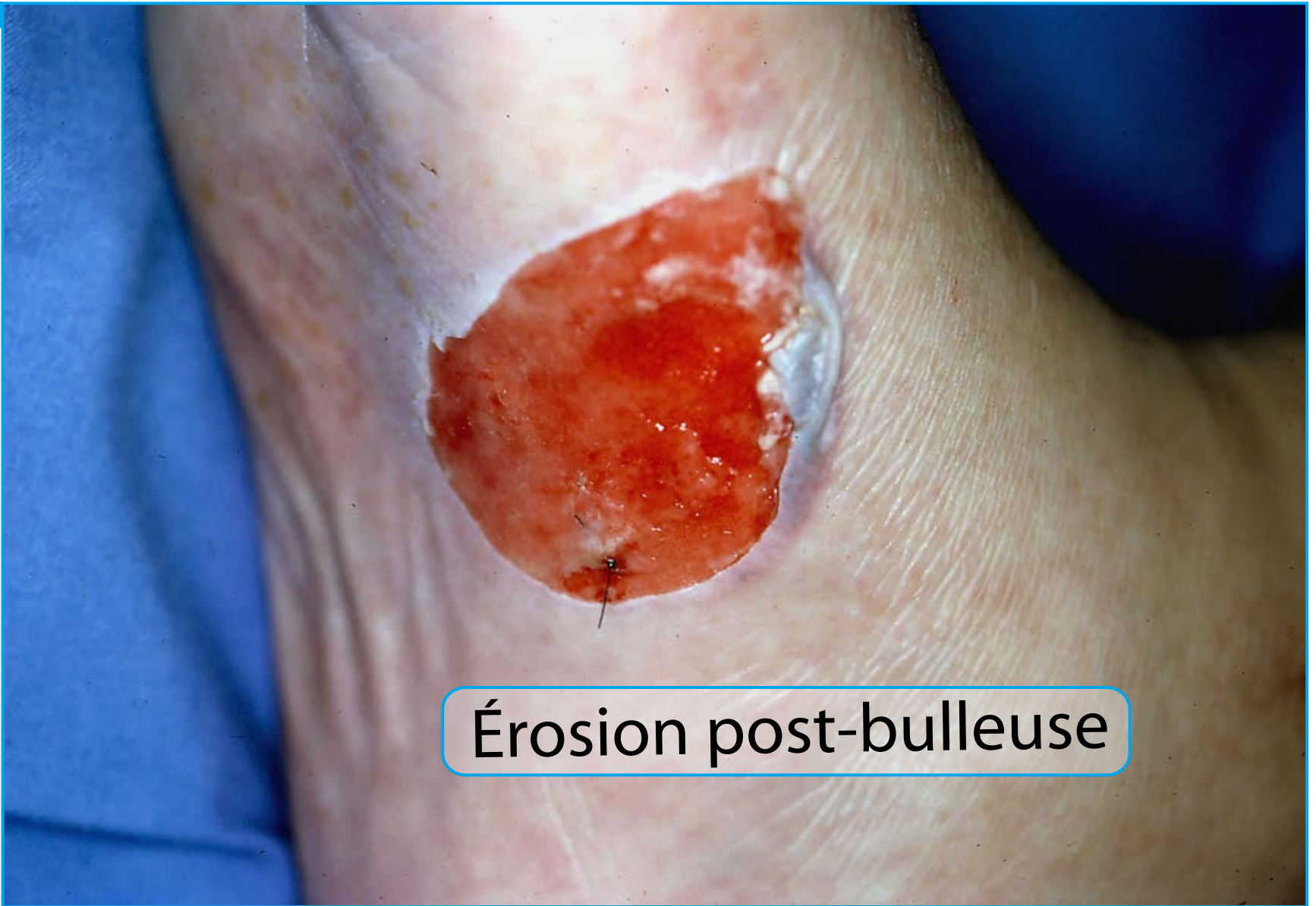



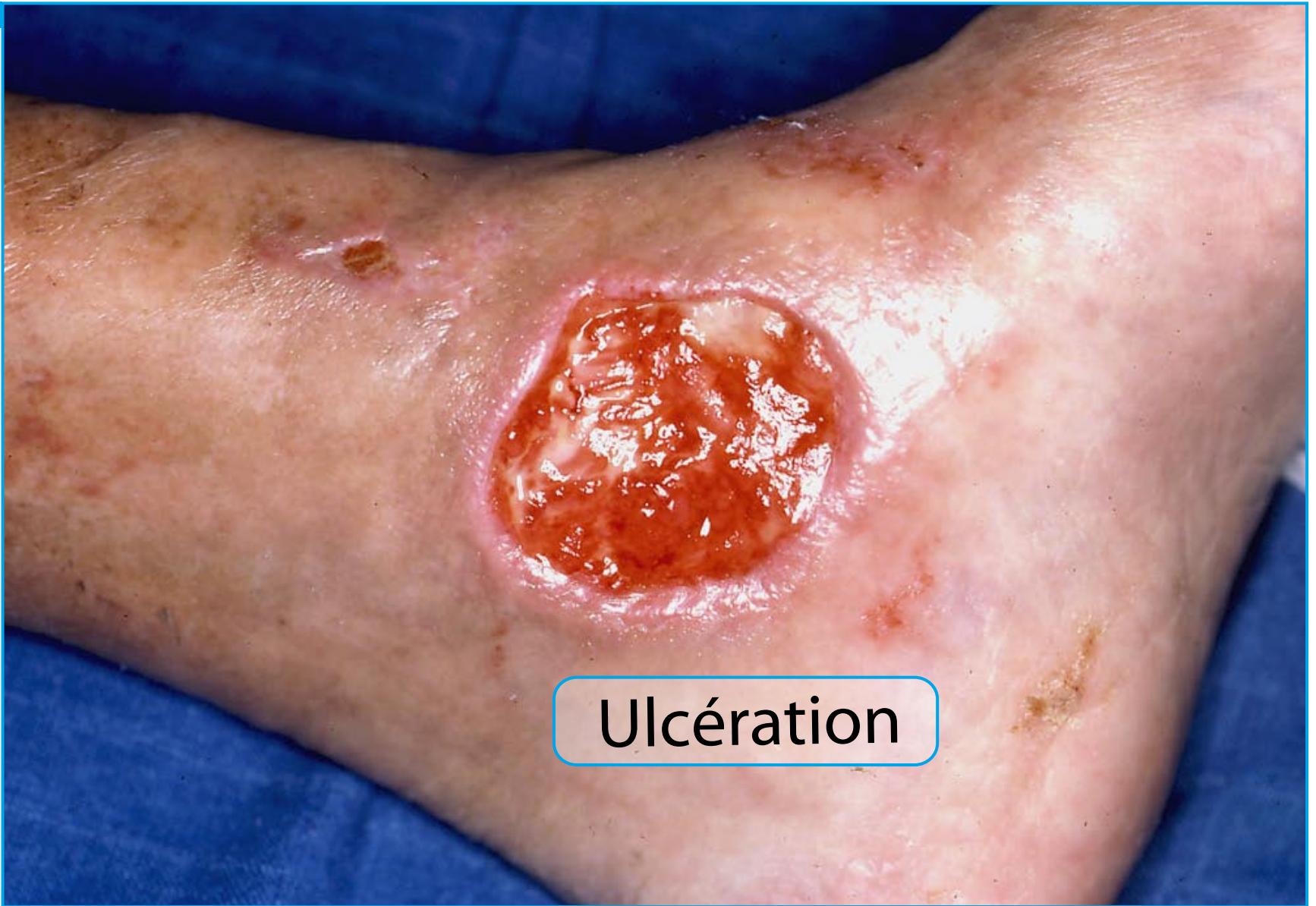Érosion



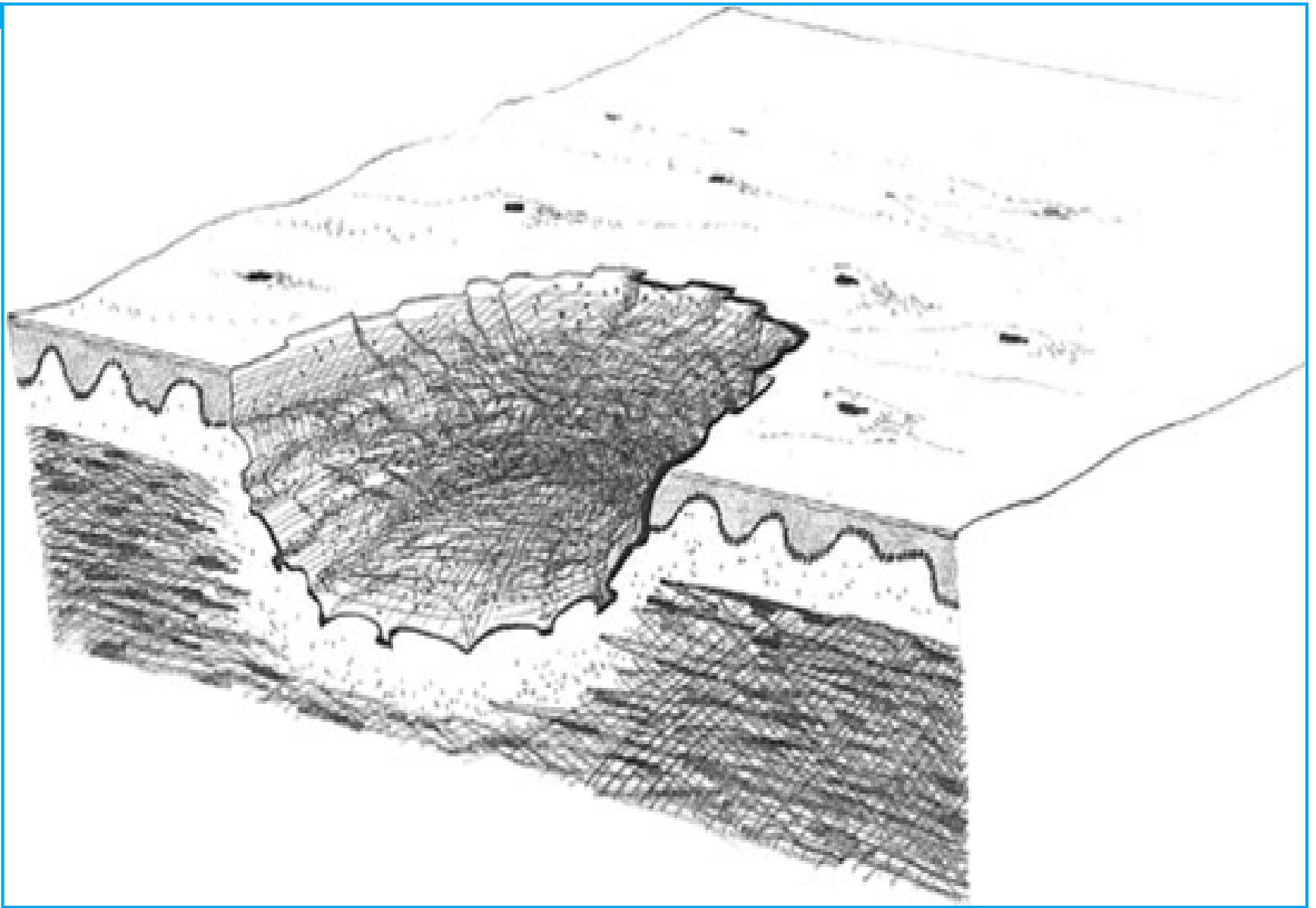
Érosion

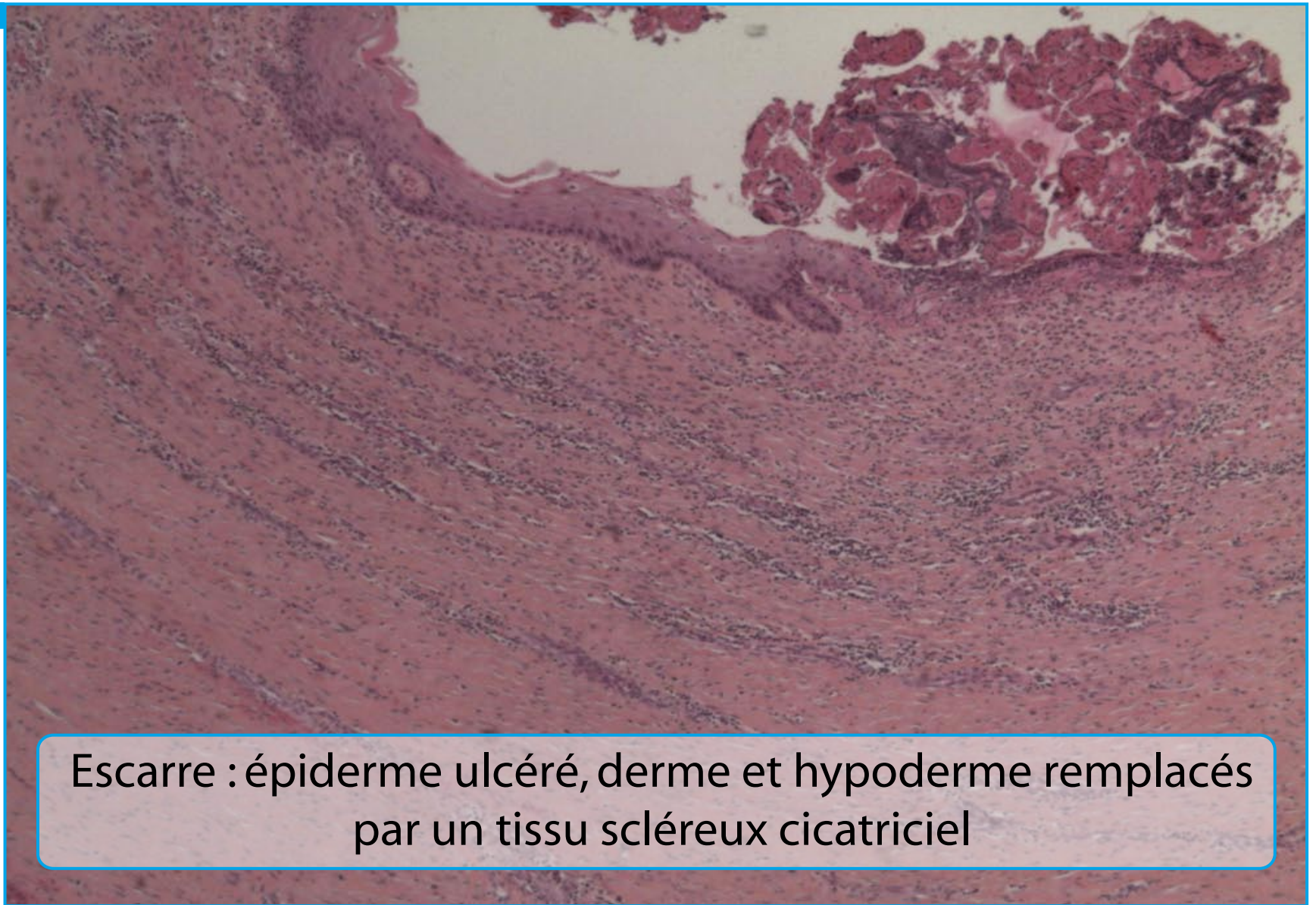

Érosion post-bulleuse



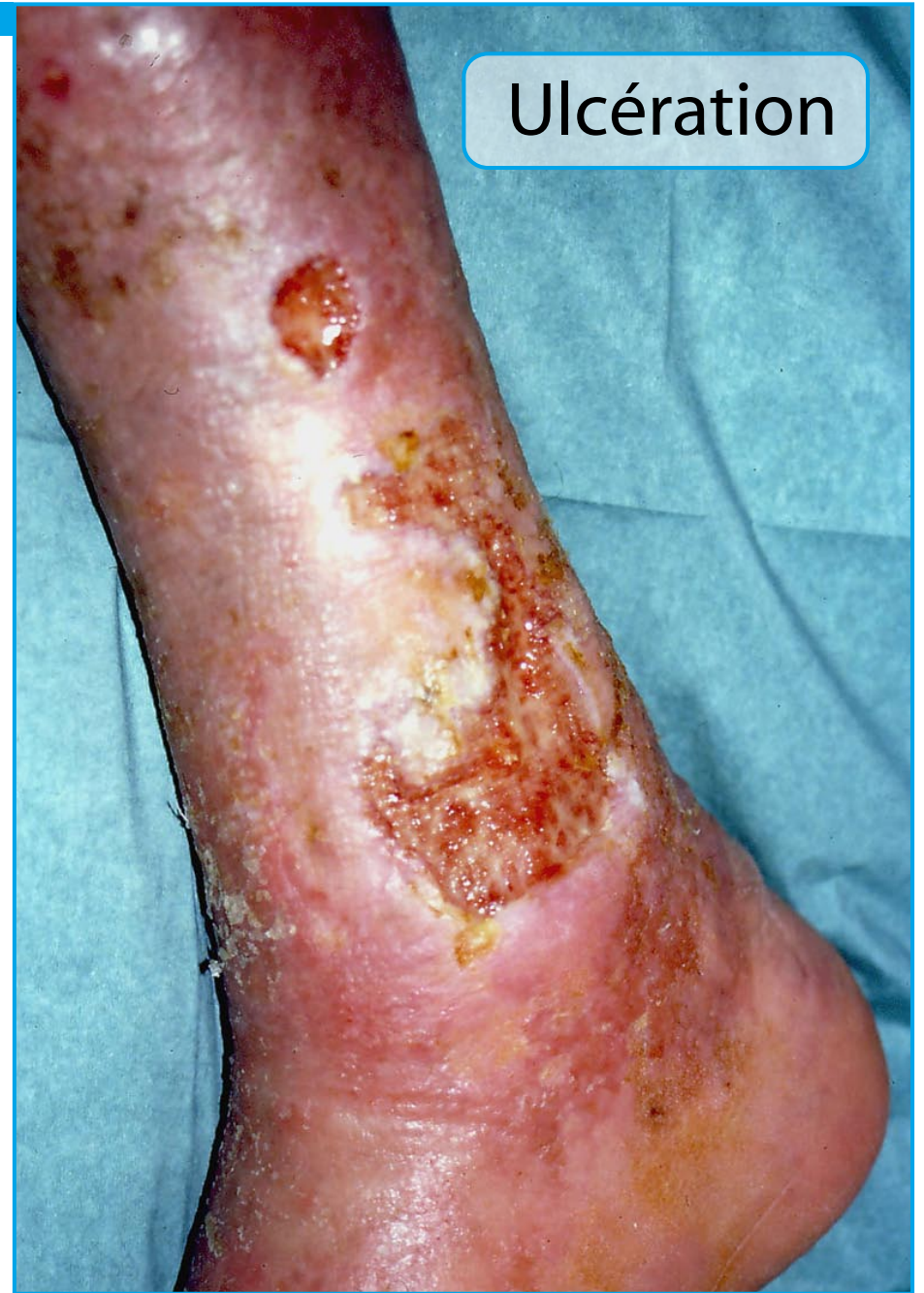Ulcération





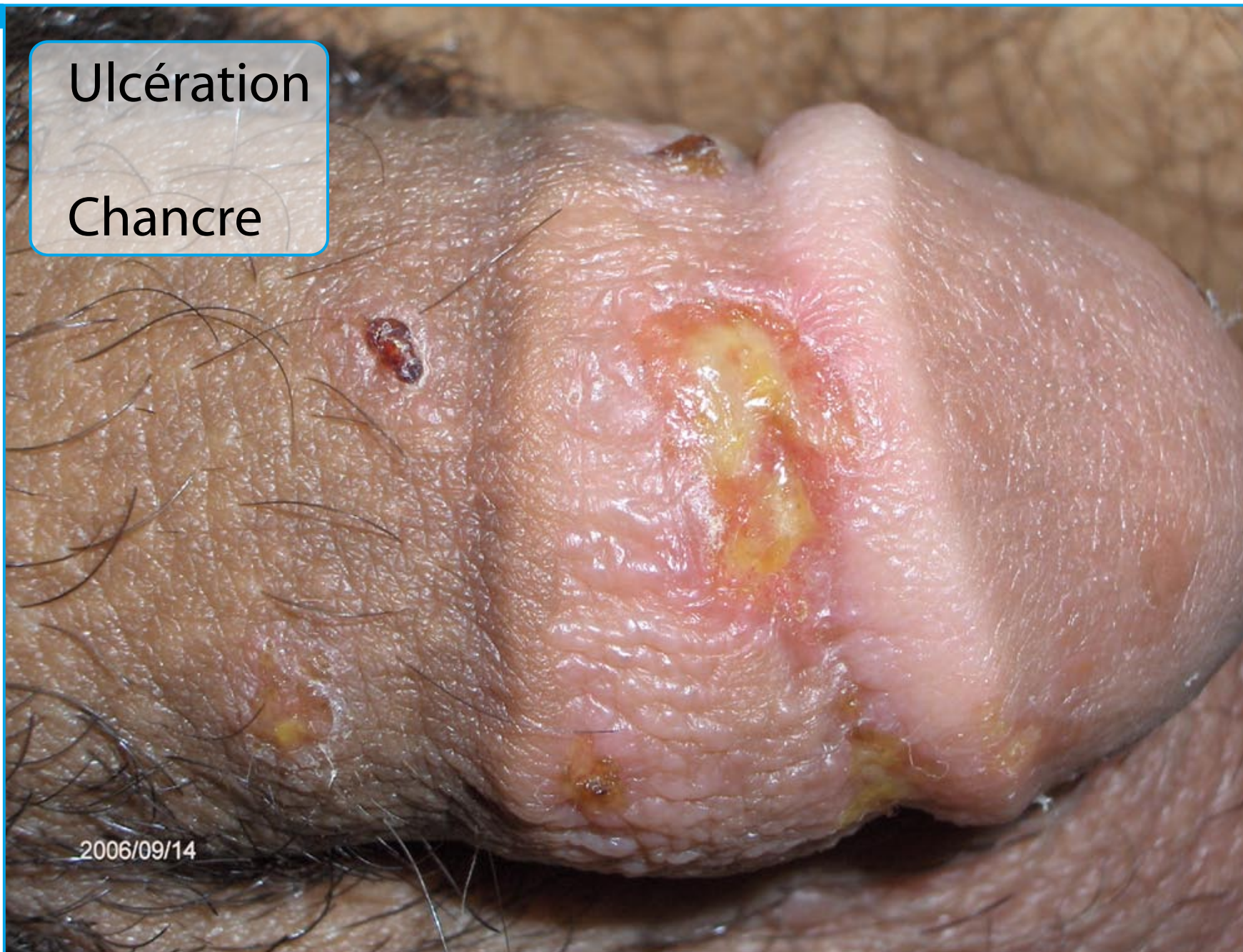
Escarre : épiderme ulcéré, derme et hypoderme remplacés par un tissu scléreux cicatriciel

Ulcération

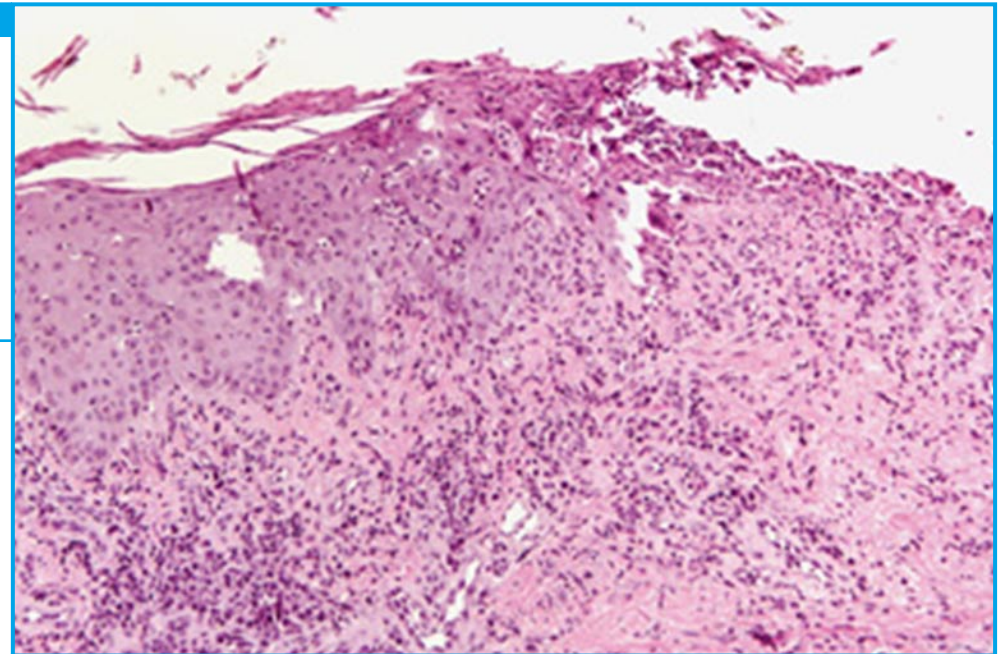


Ulcération

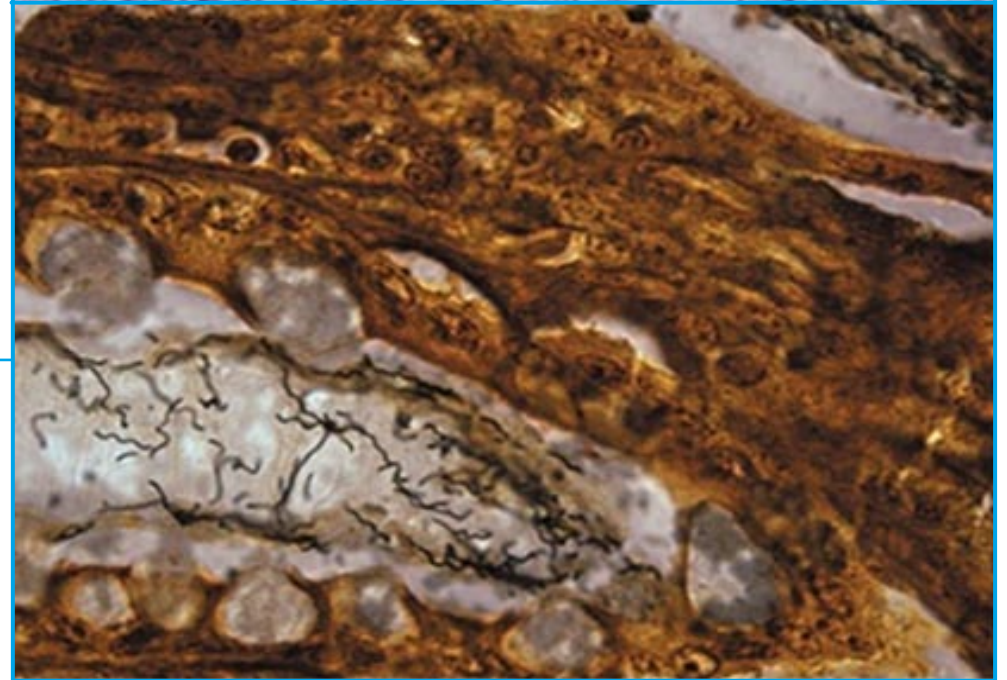
Chancre



■ Ulcération muqueuse



■ Mise en évidence du tréponème (syphilis) par la coloration de Warthin-Starry

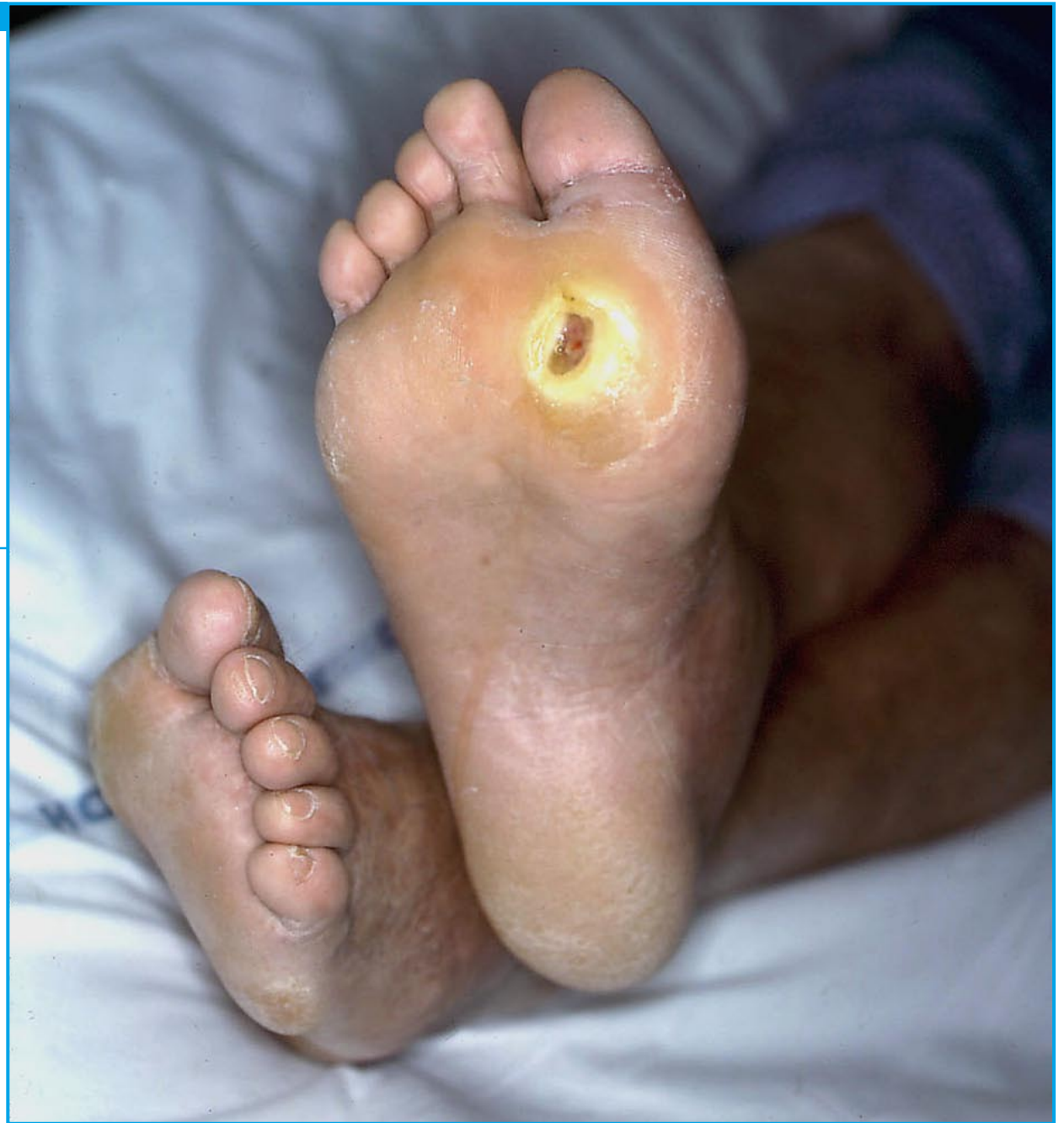

Ulcération

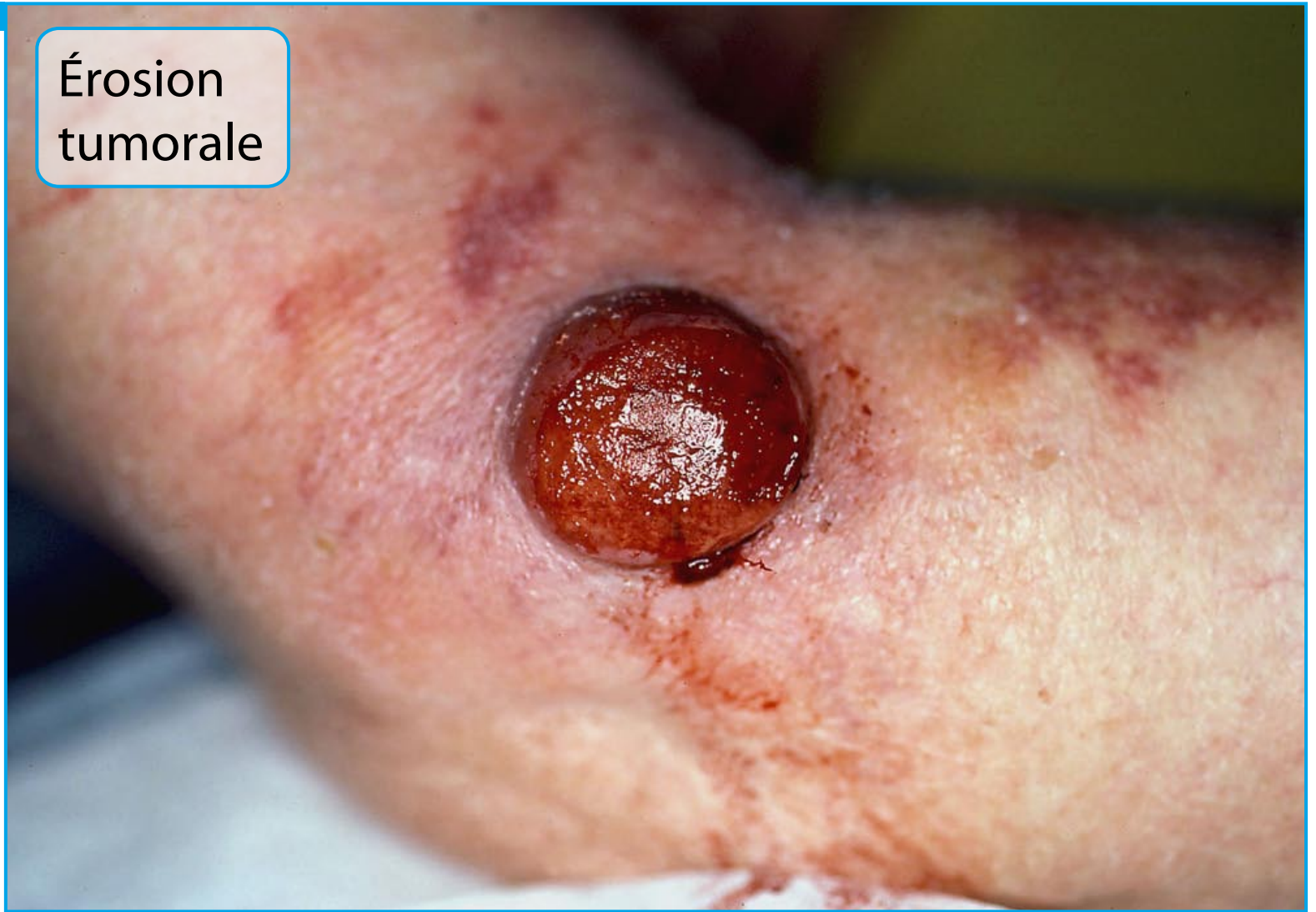Aphte



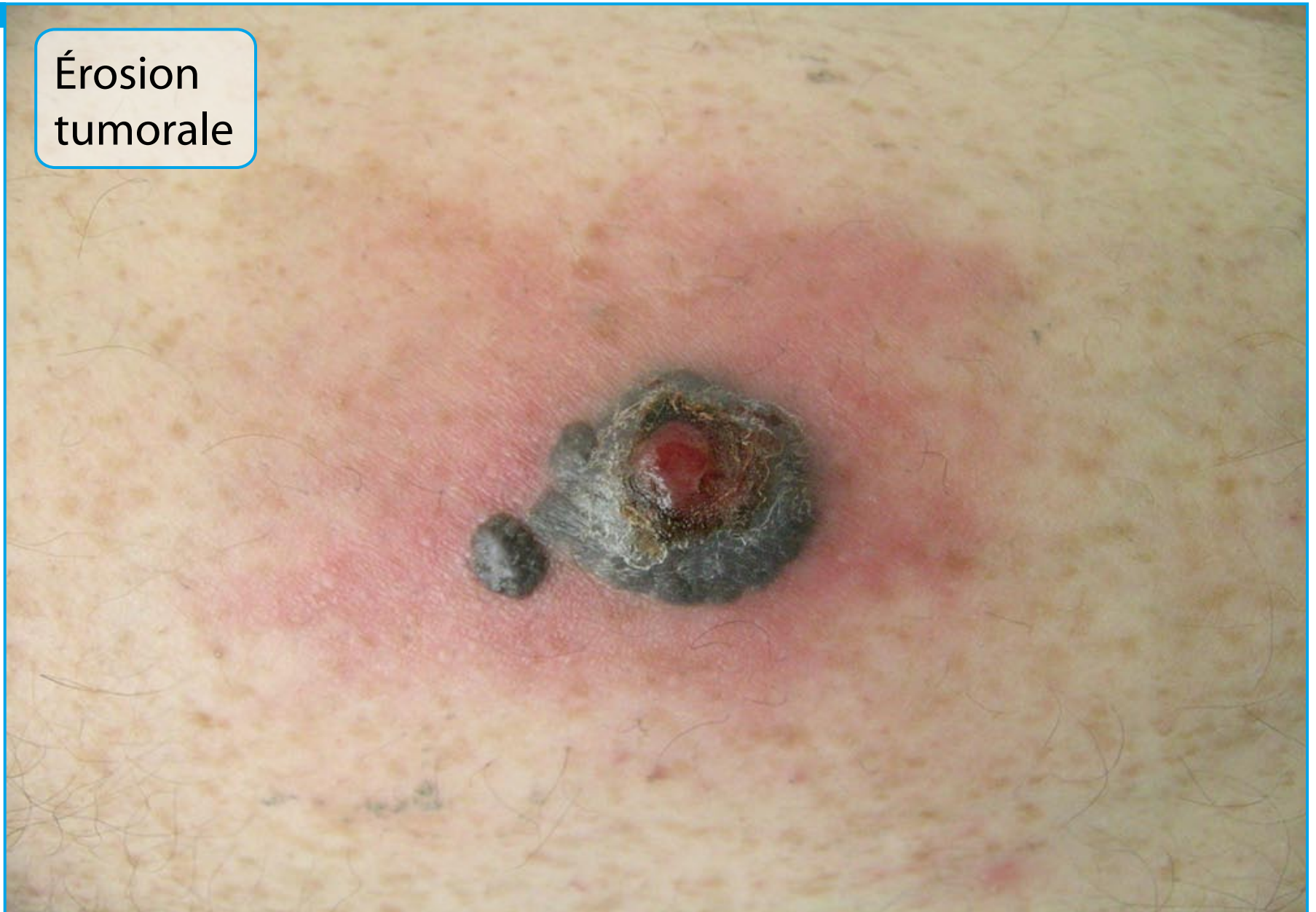■ Ulcération
Mal perforant

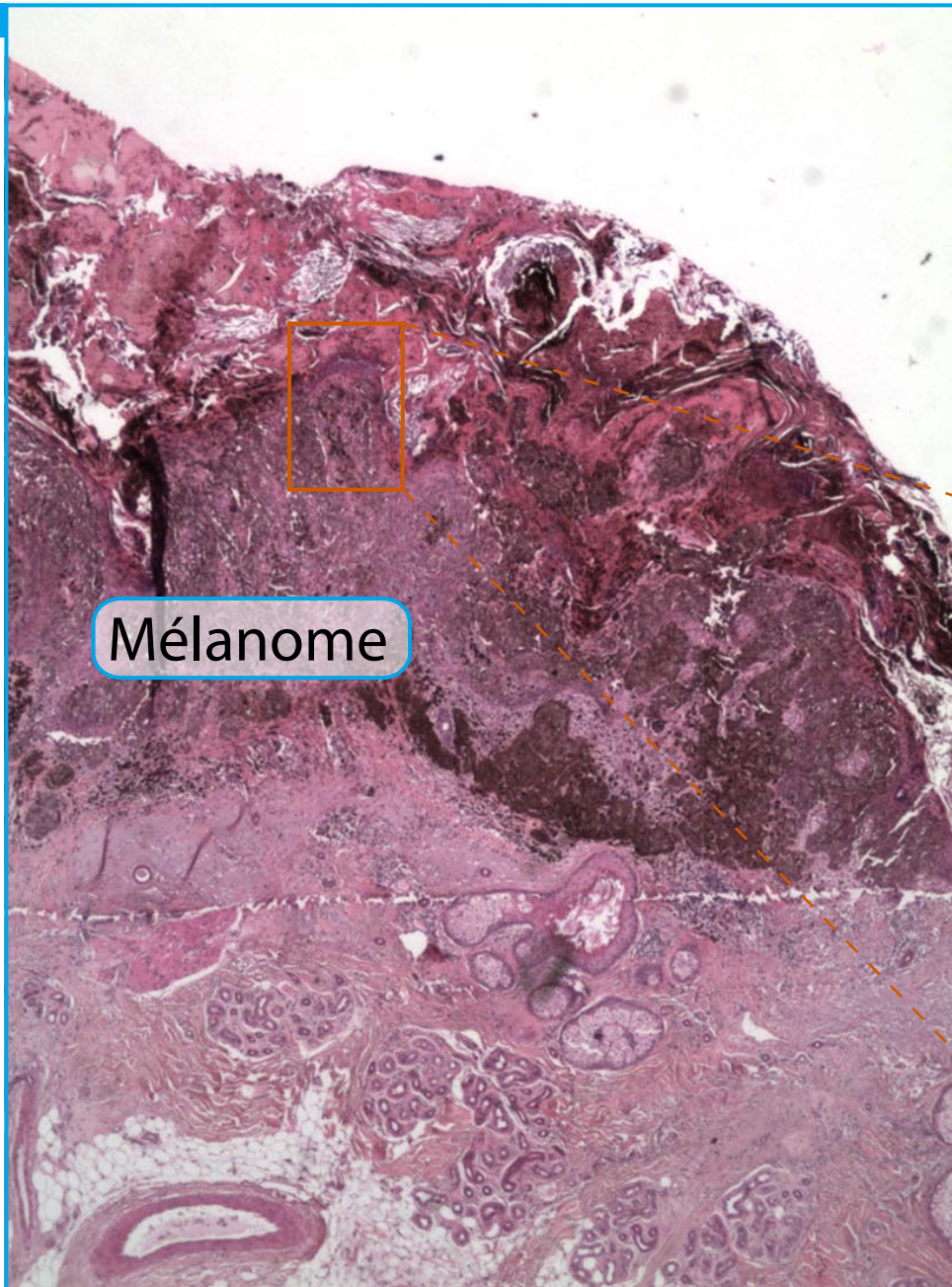


Érosion
tumorale

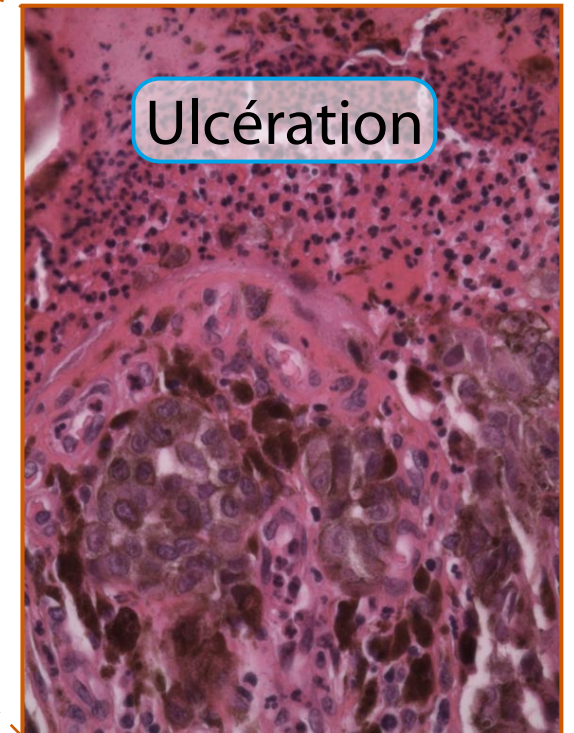

Érosion
tumorale

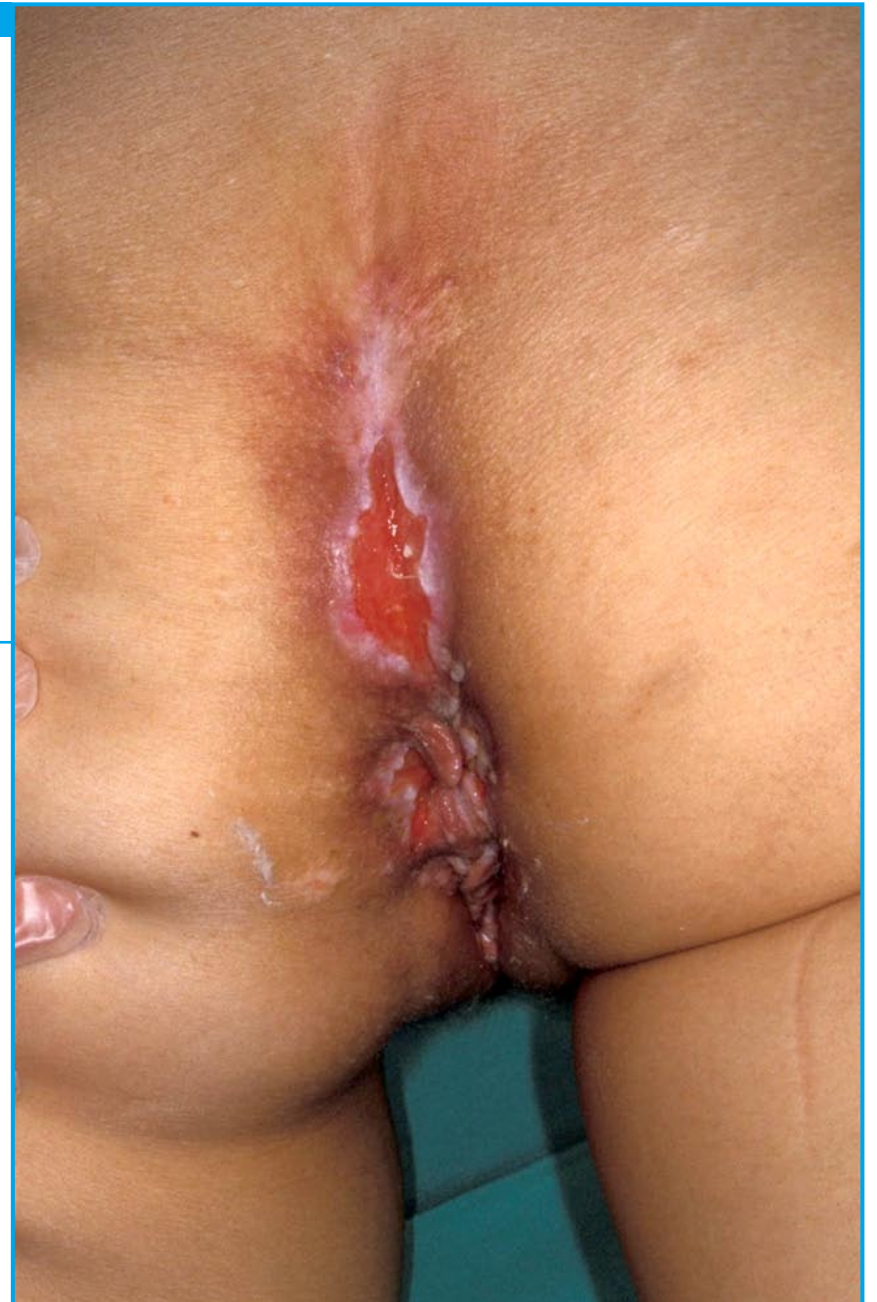




Mélanome ulcéré



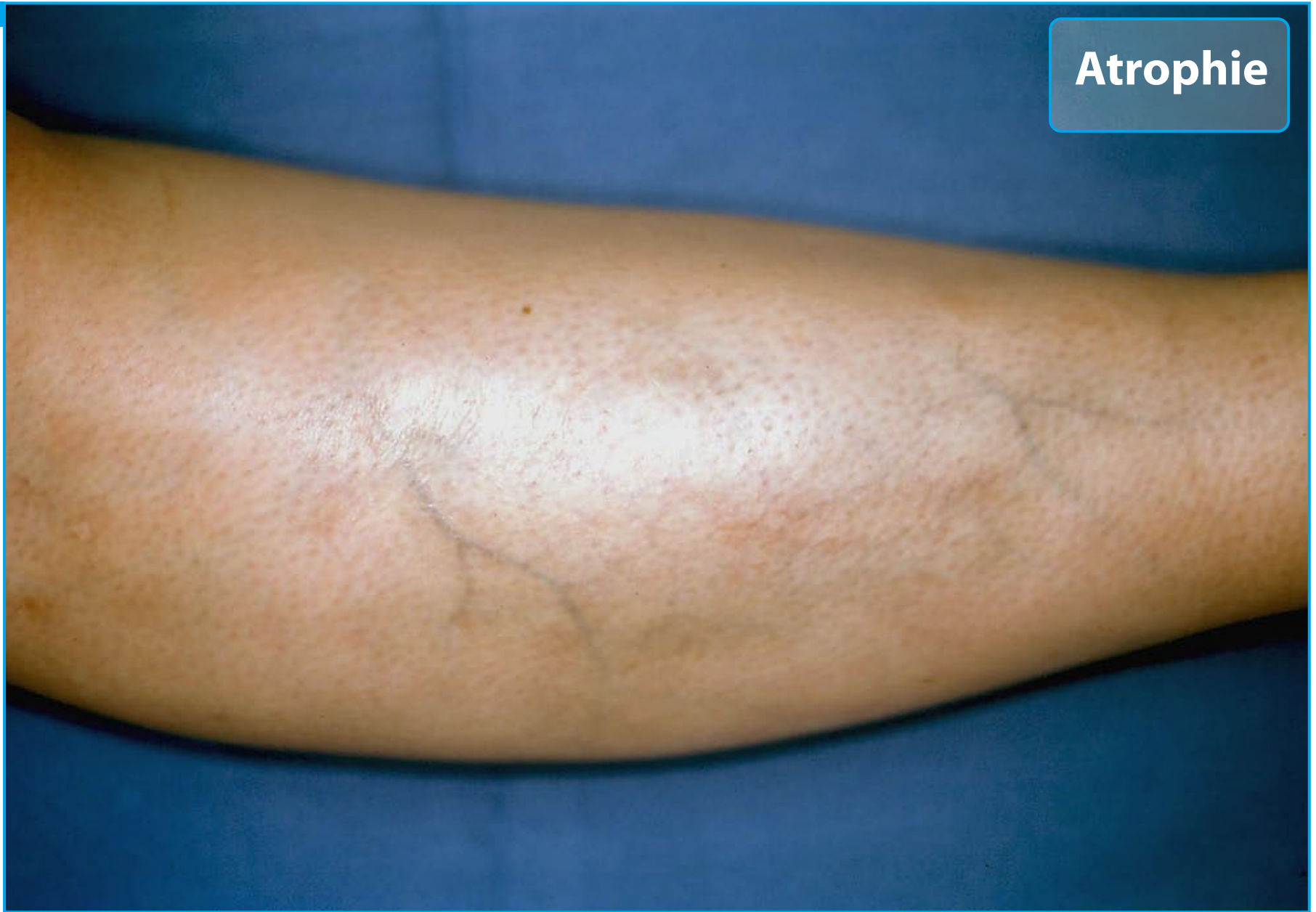■ Érosion infectieuse ▶

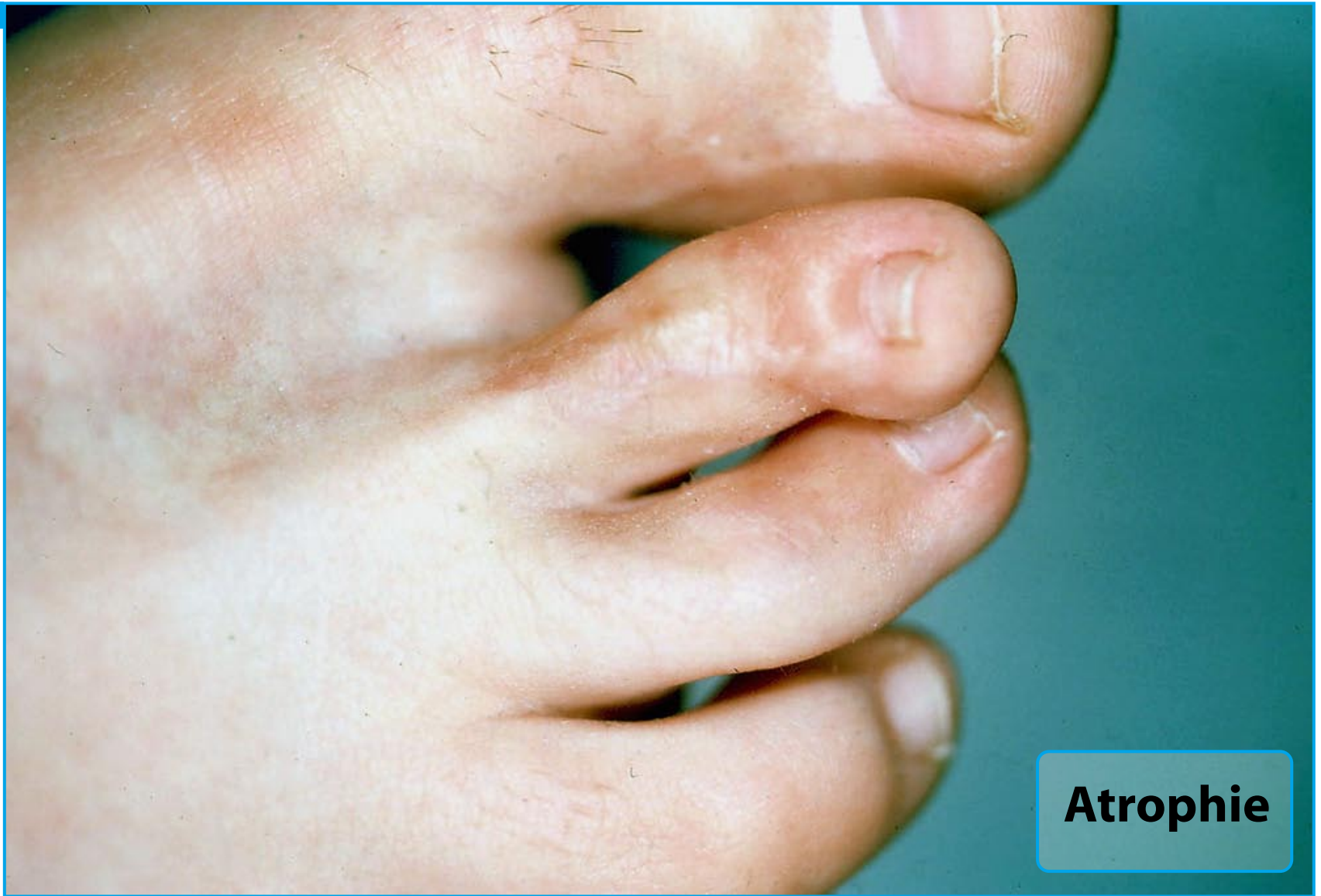



Atrophie cutanée

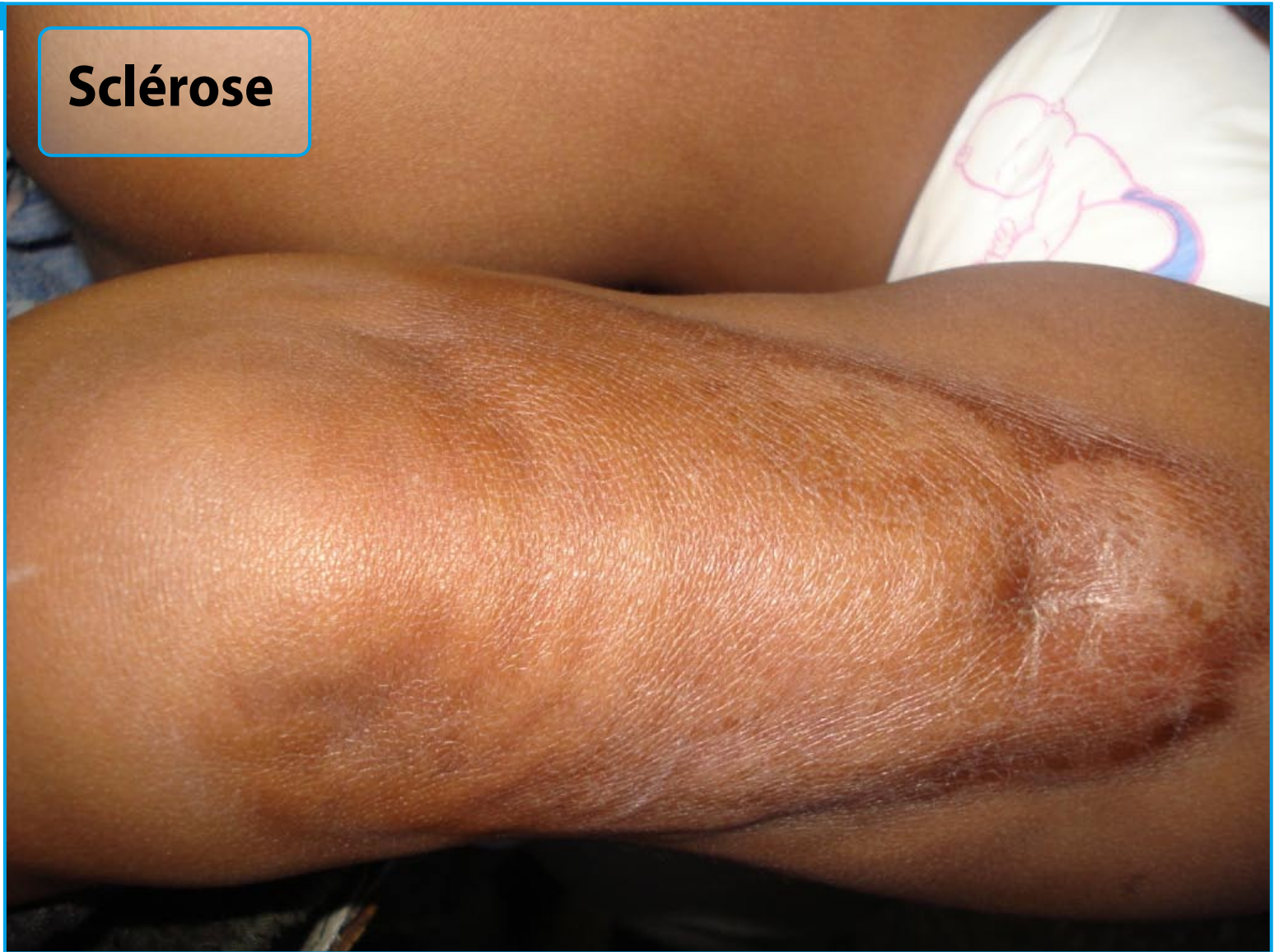Atrophie

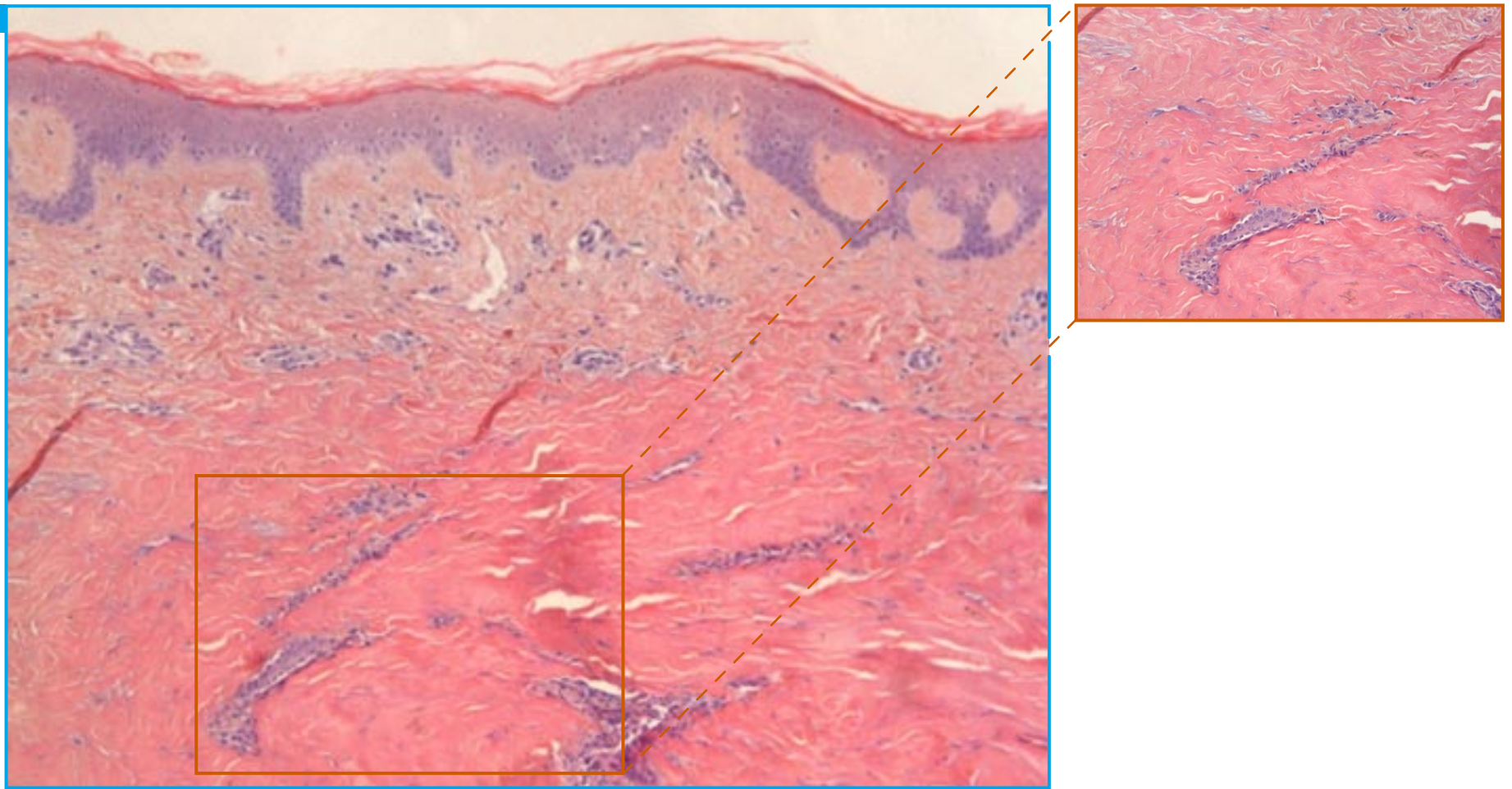




Atrophie

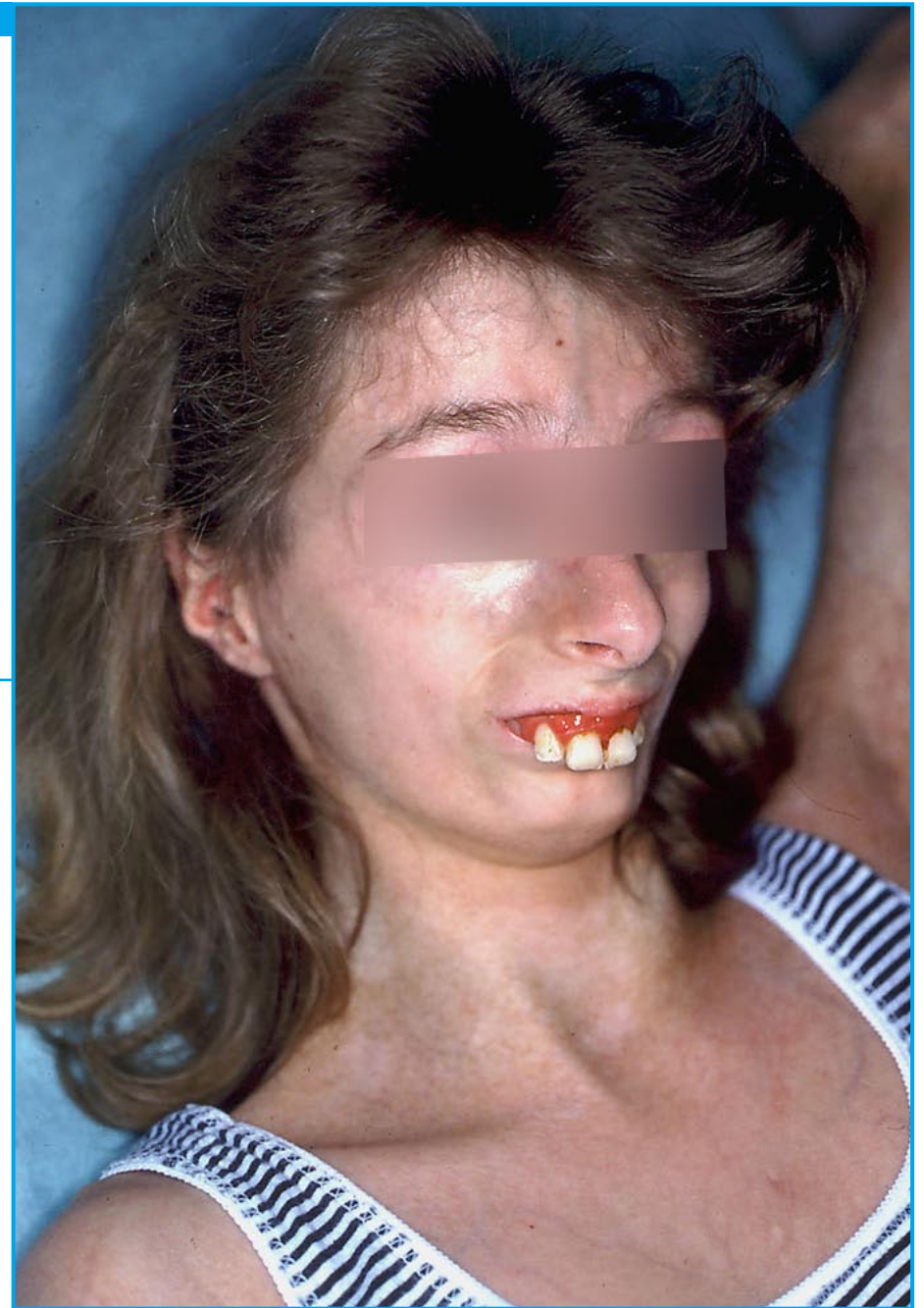Sclérose



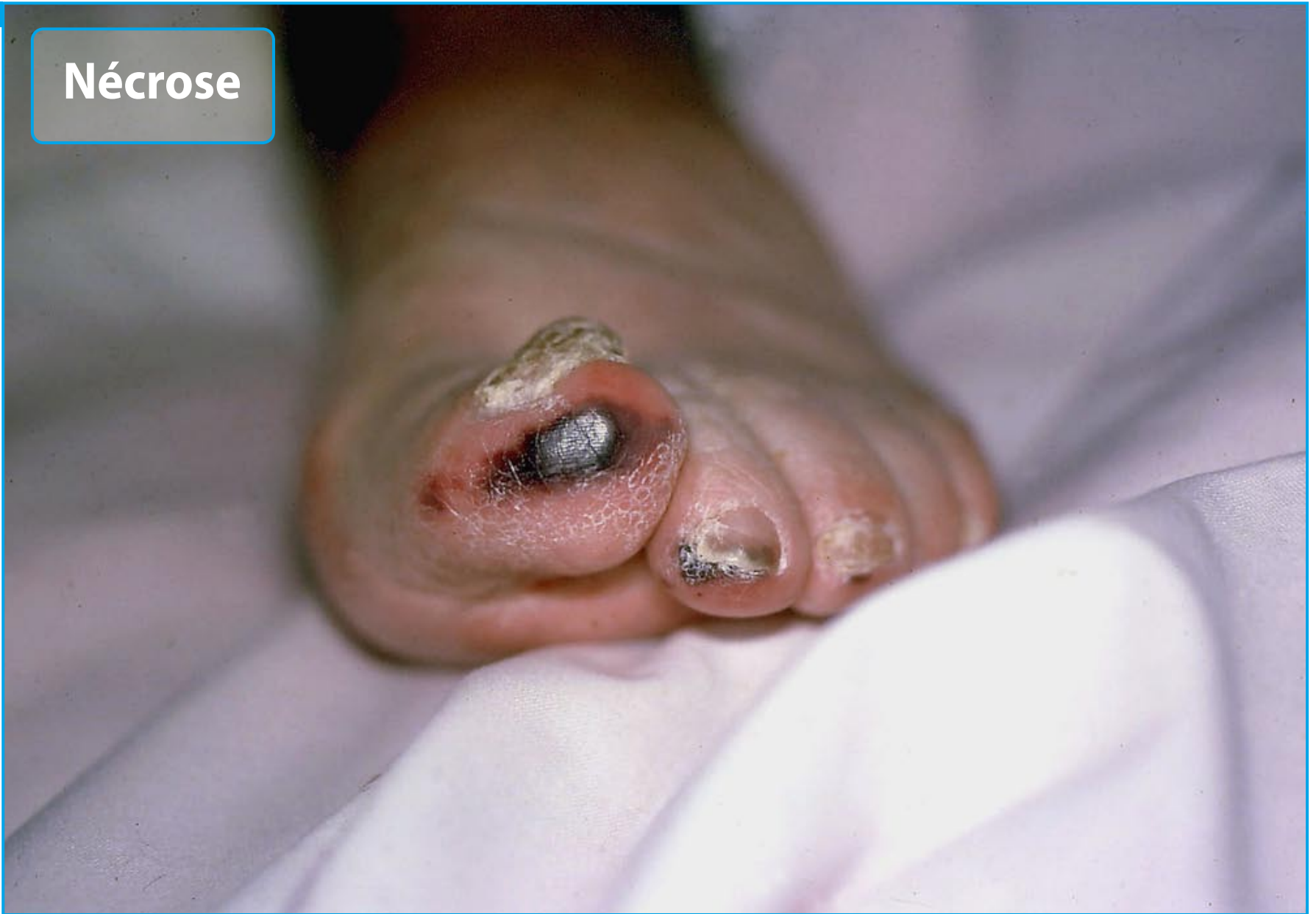

■ Sclérose dense du collagène dermique

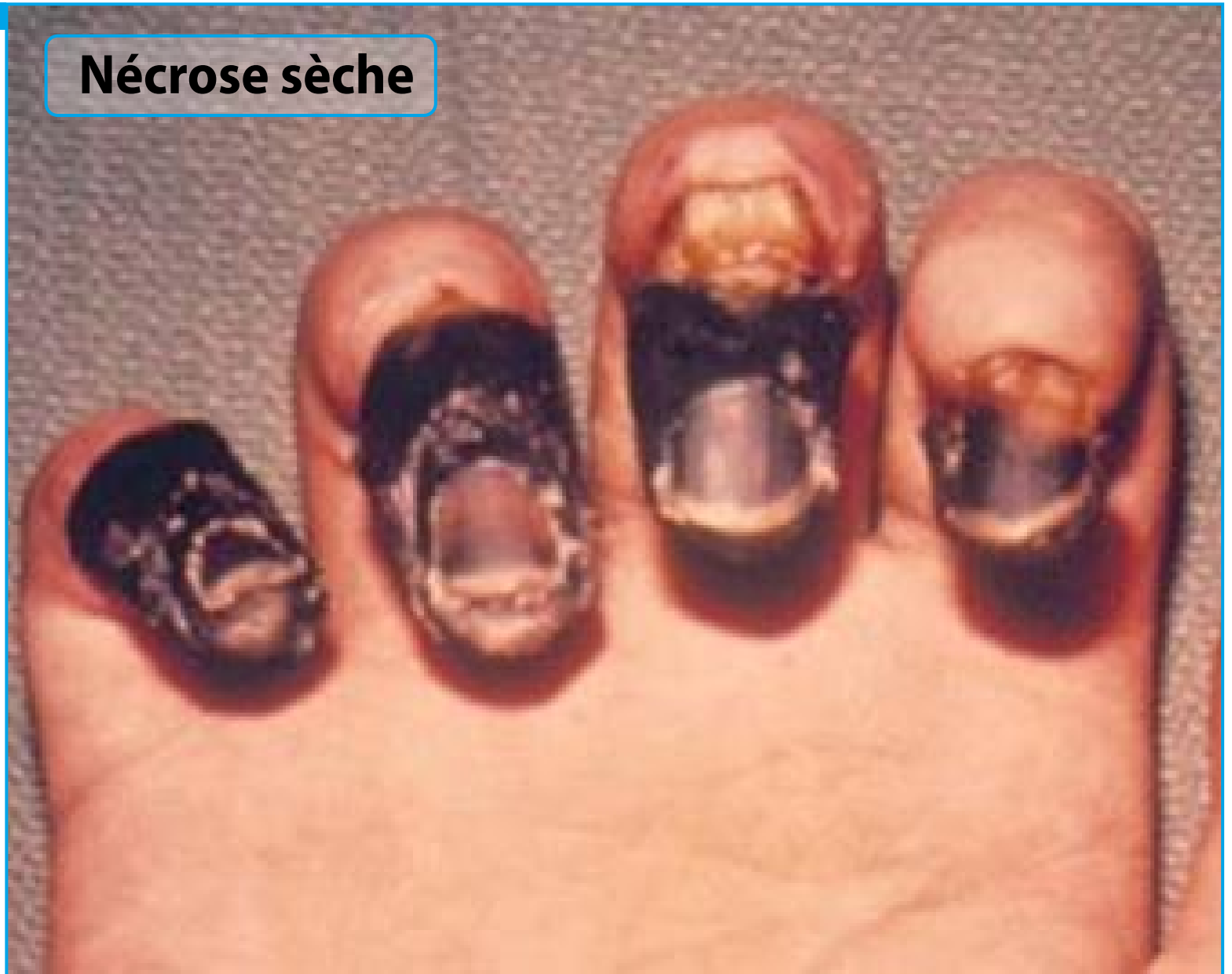Atrophie
Sclérose

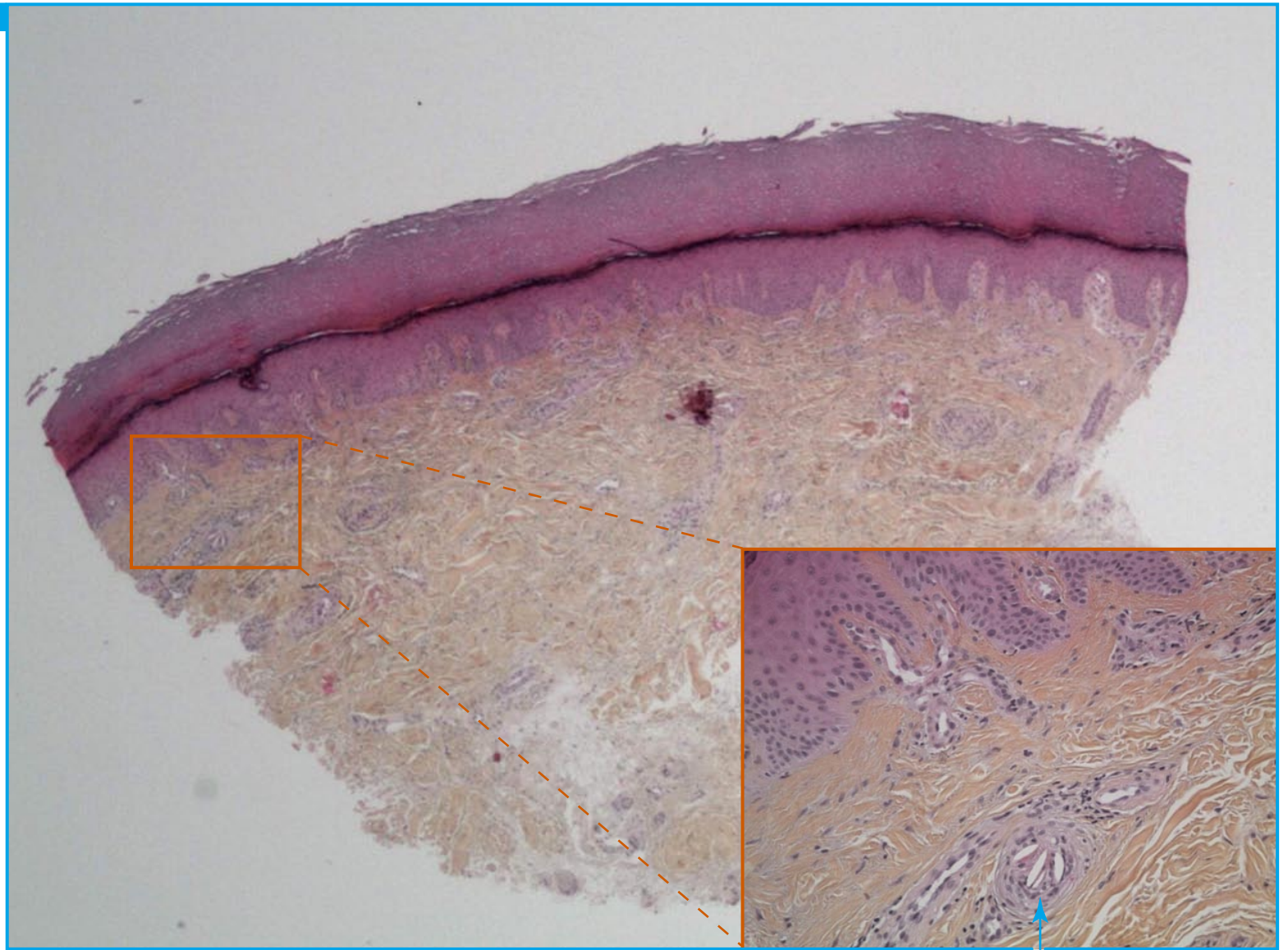


Nécrose

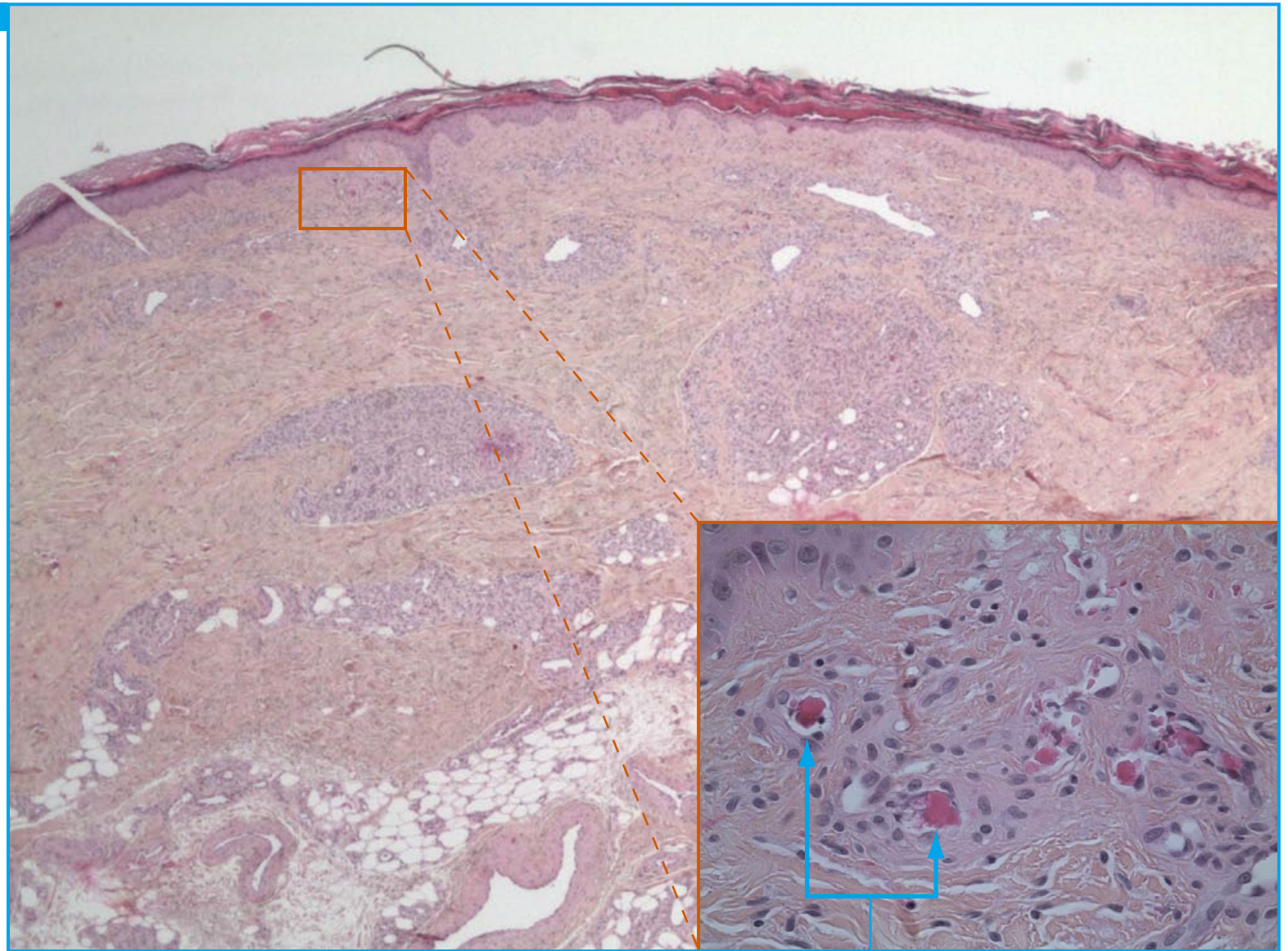


Nécrose sèche

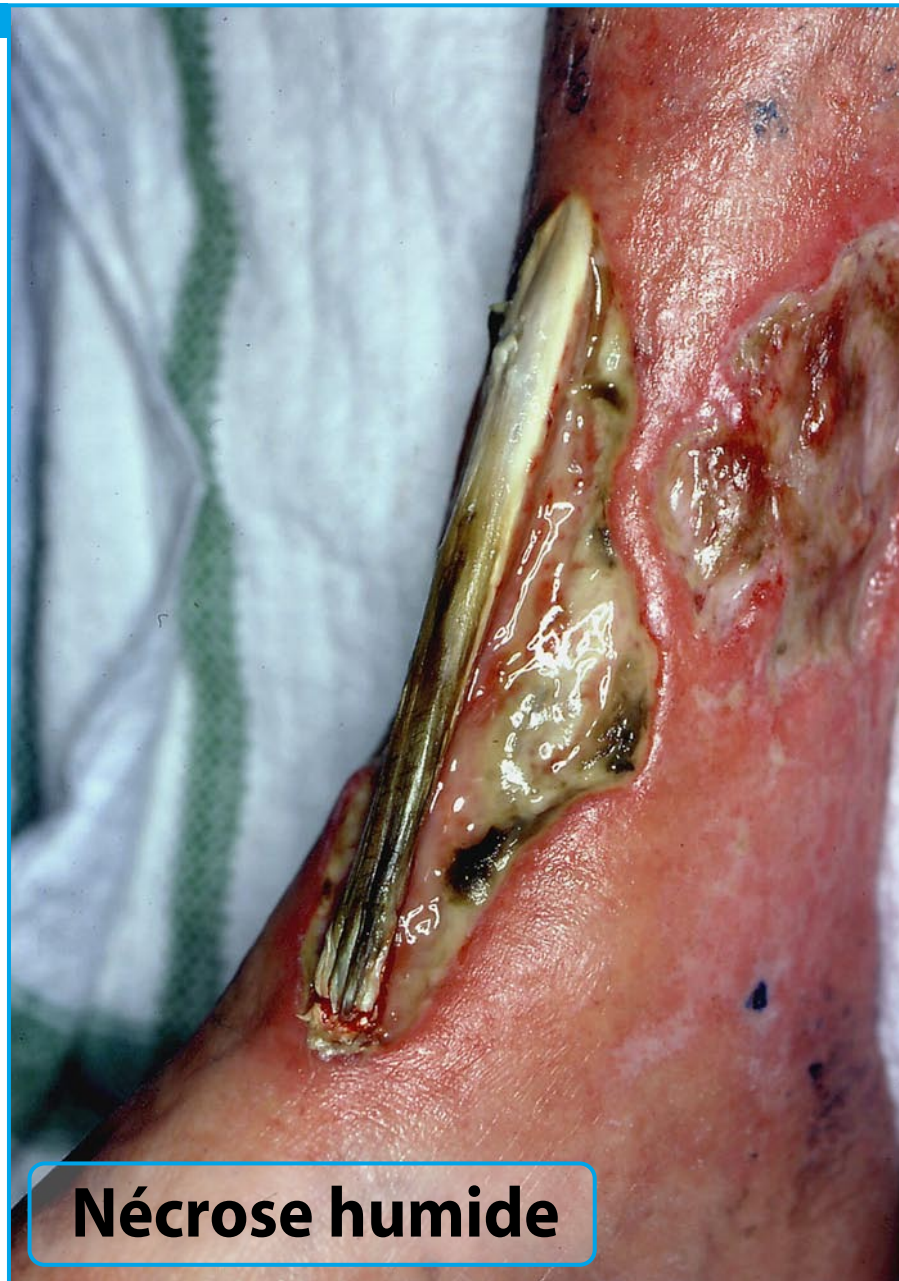



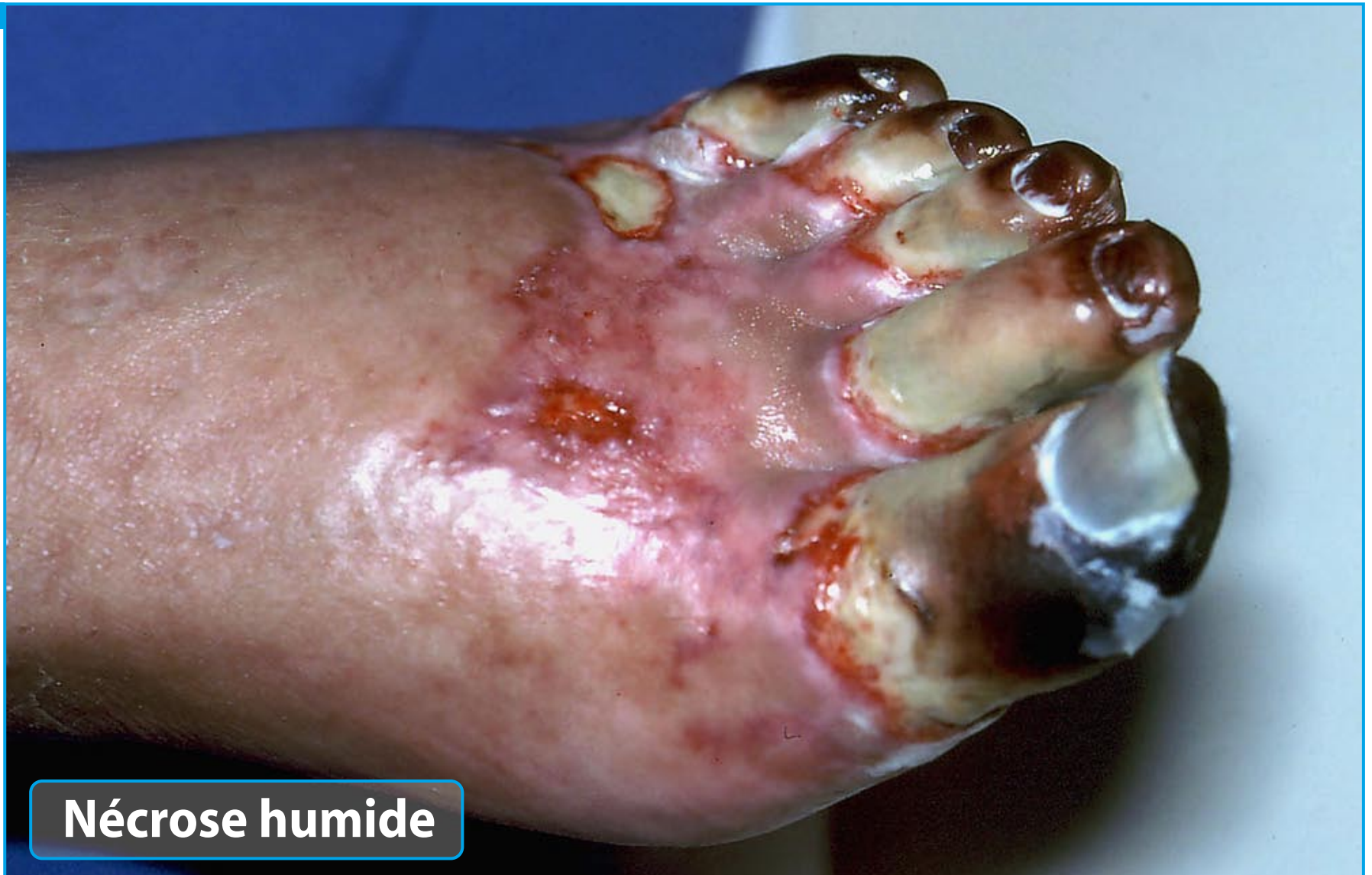- Cristaux de cholestérol lanacéolés dans les lumières capillaires



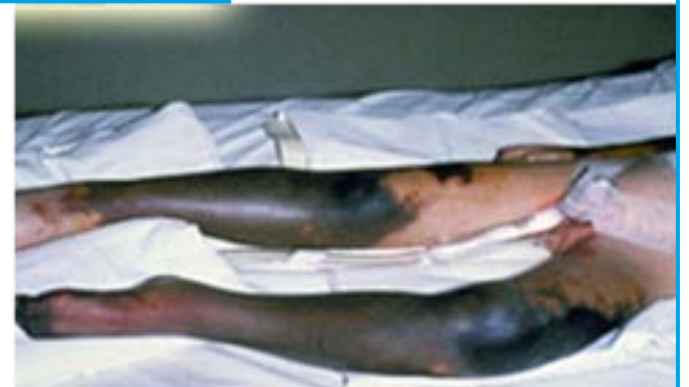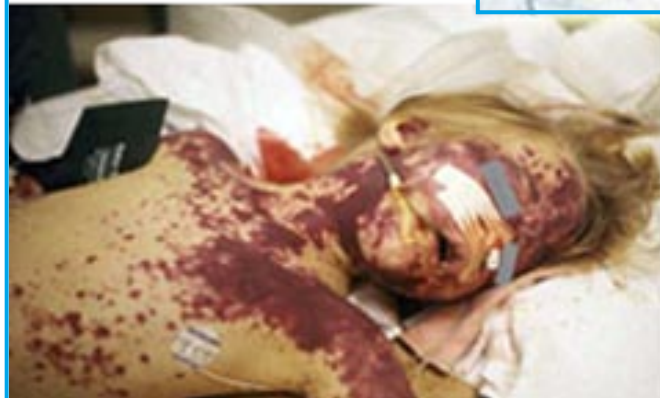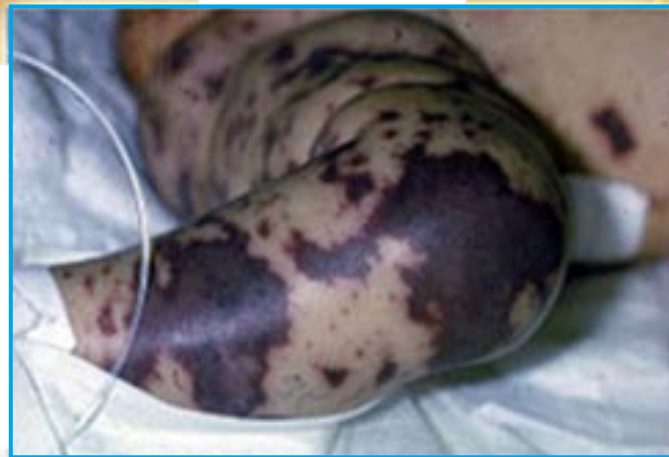
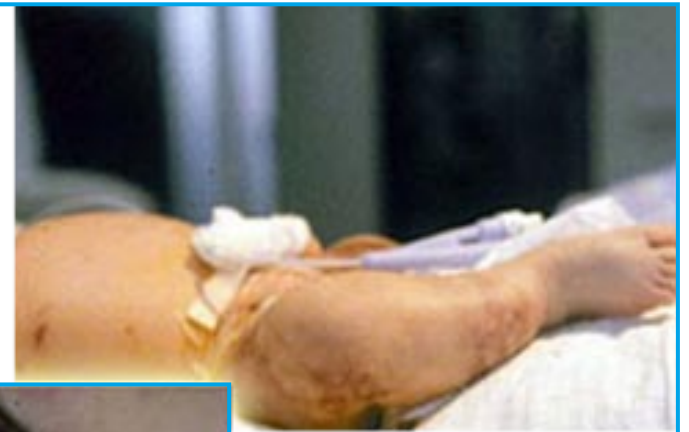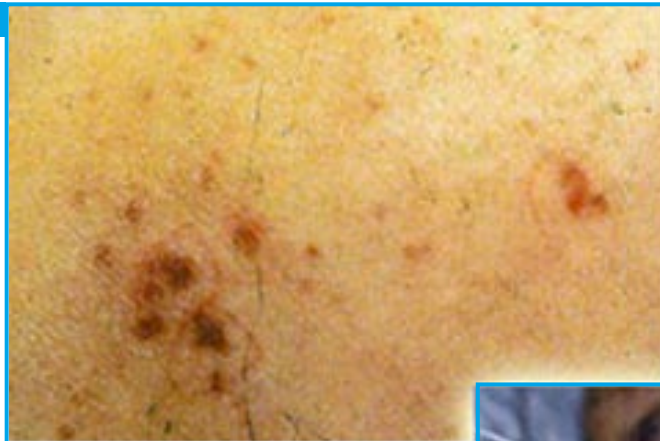- Capillaires obstrués par une immunoglobuline ayant des propriétés particulières appelée **cryoglobuline**



Nécrose humide



Nécrose humide



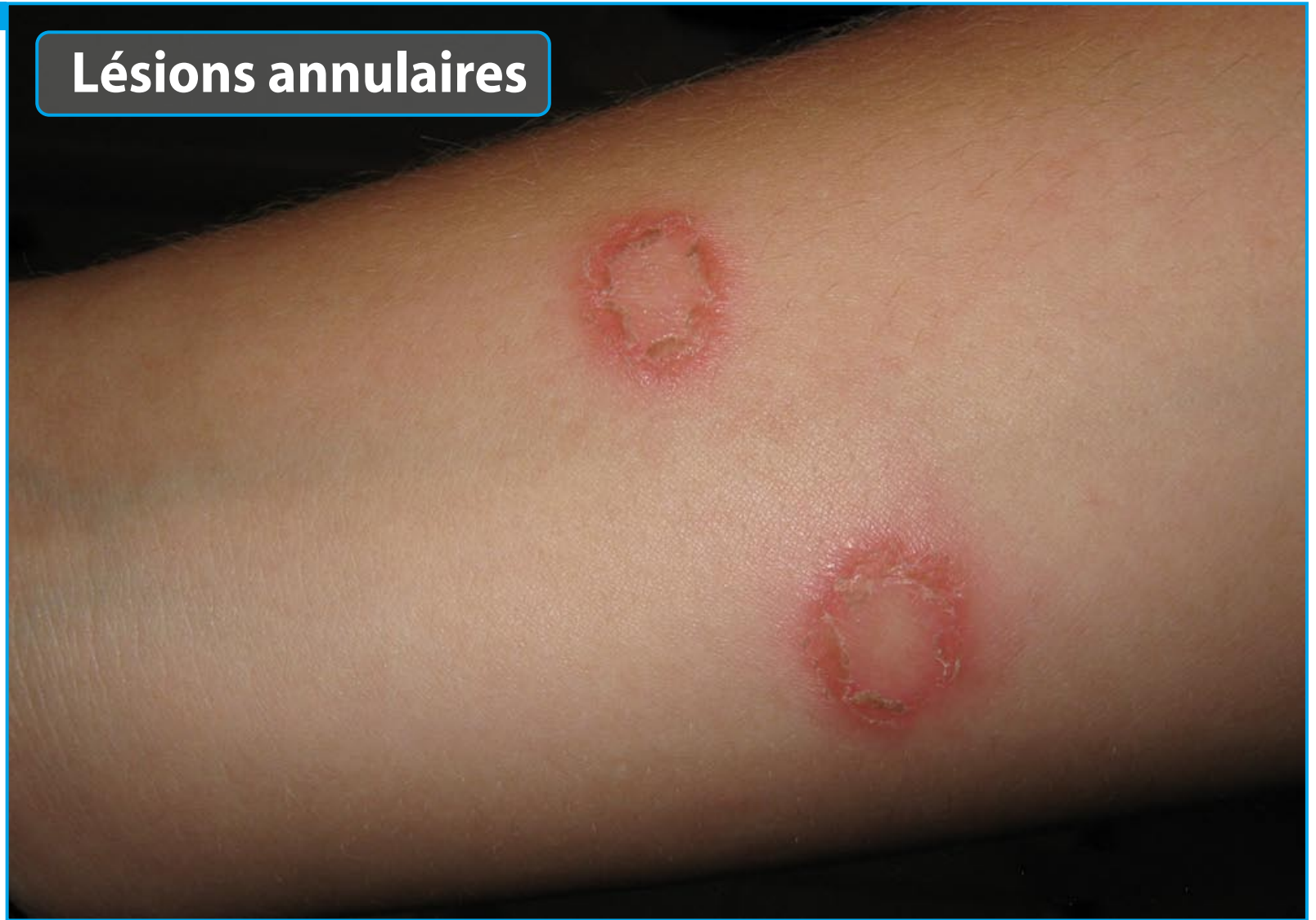■ Nécrose cutanée d'origine infectieuse

Lésions dermatologiques remarquables

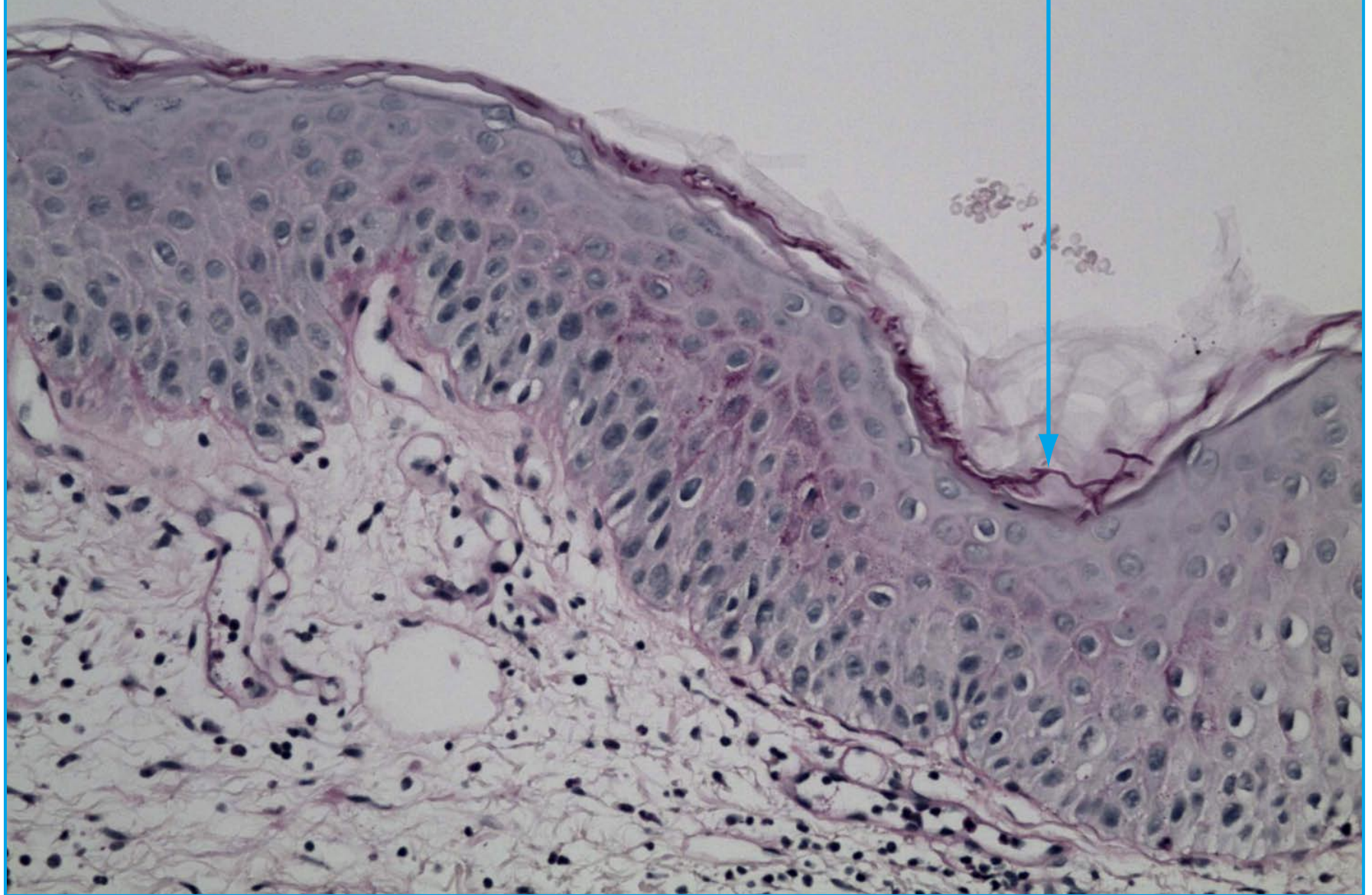
■ Dr. Anne Croué

■ Pr. Ludovic Martin

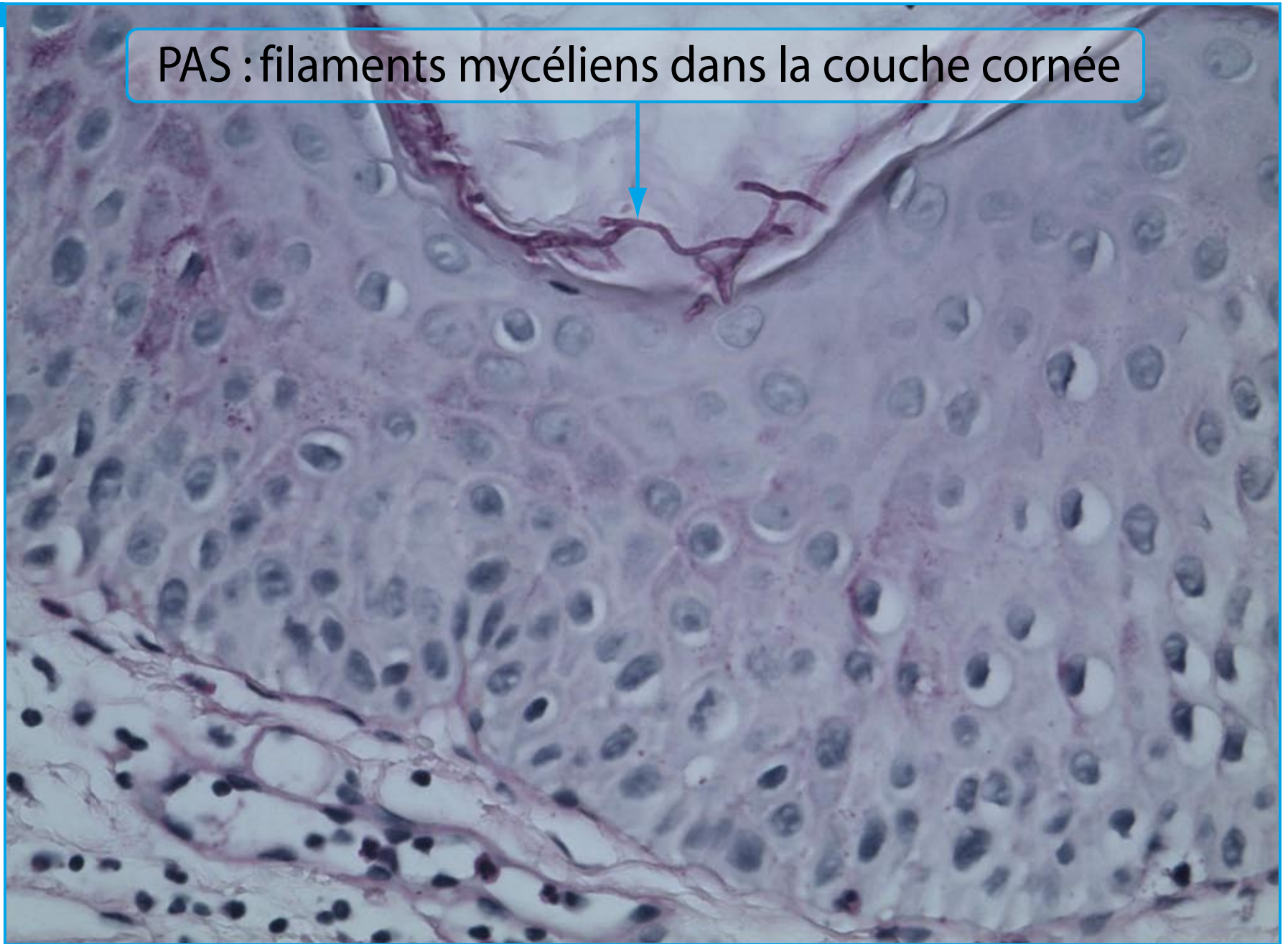
Lésions annulaires



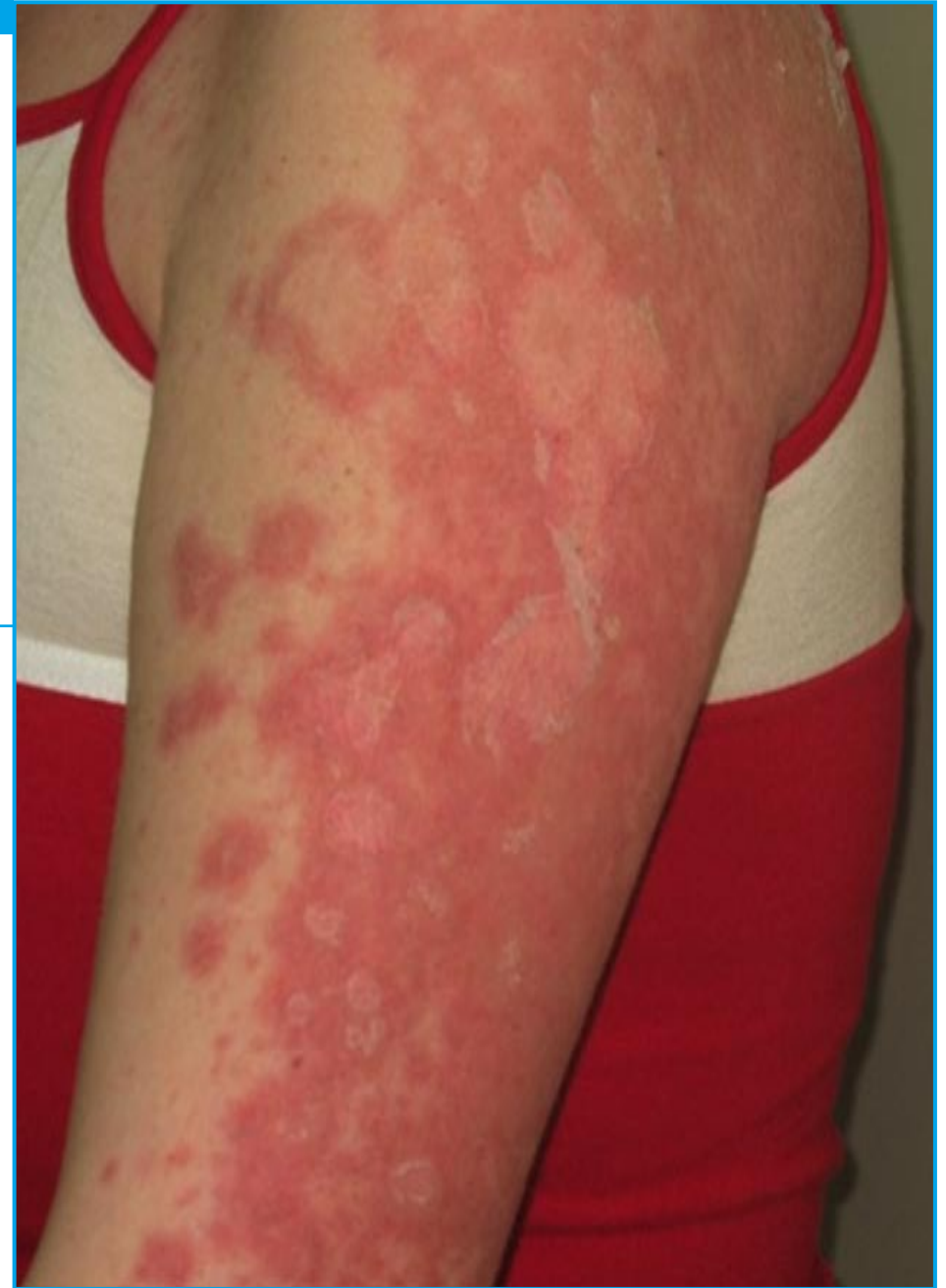PAS : filaments mycéliens dans la couche cornée



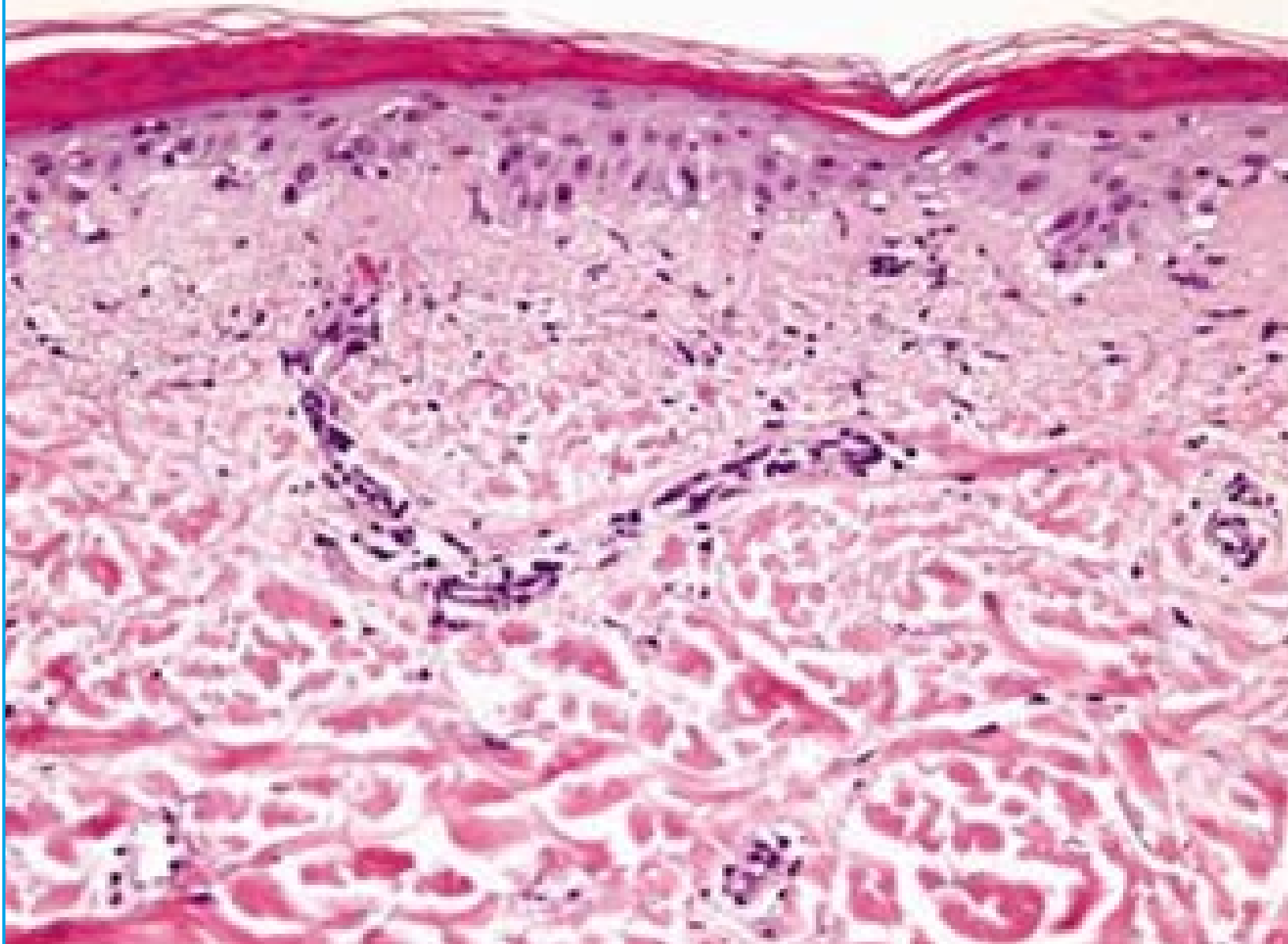
PAS : filaments mycéliens dans la couche cornée

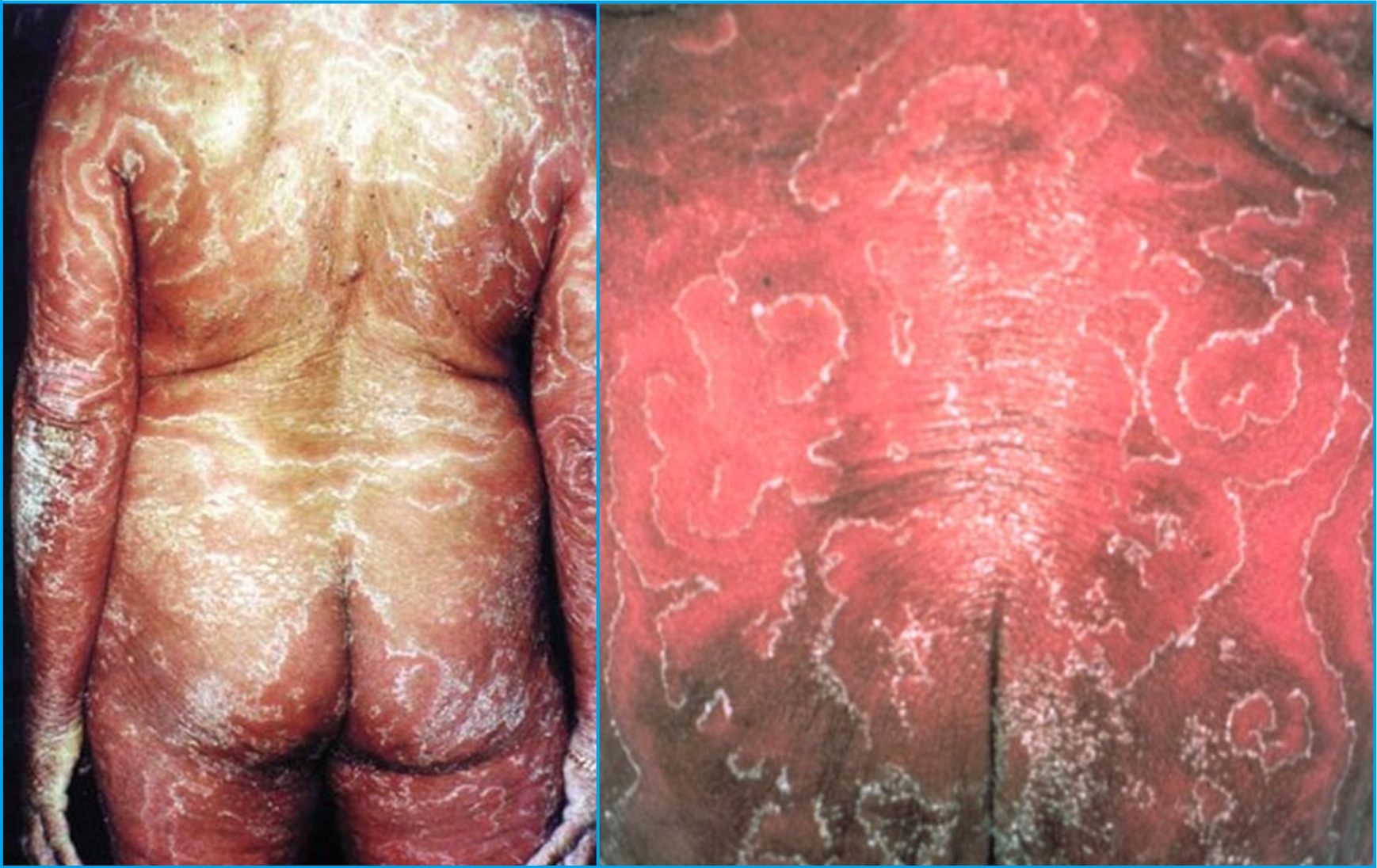

■ Lésions annulaires polycycliques

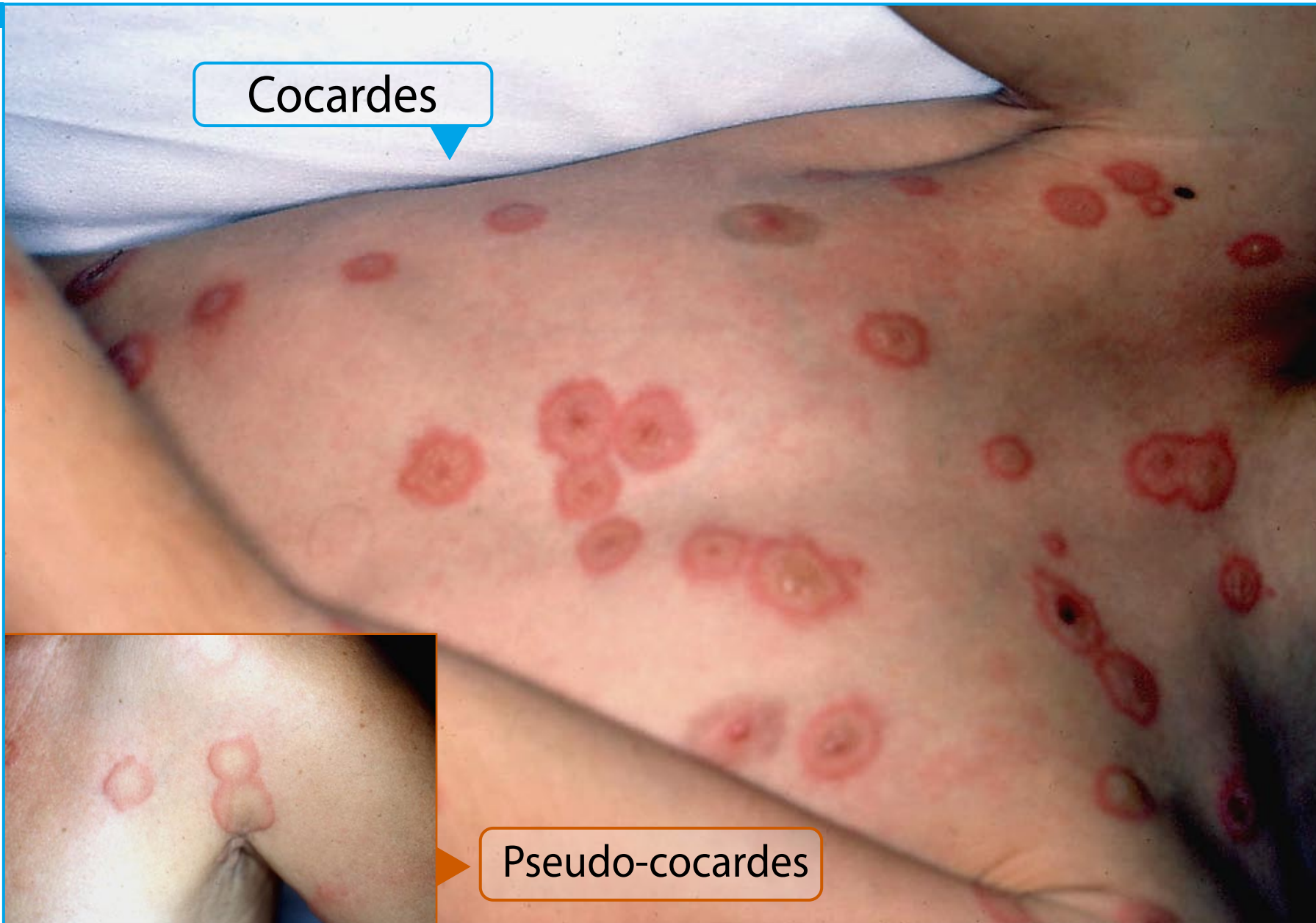

Dermite de l'interface : altération des kératinocytes de la couche basale

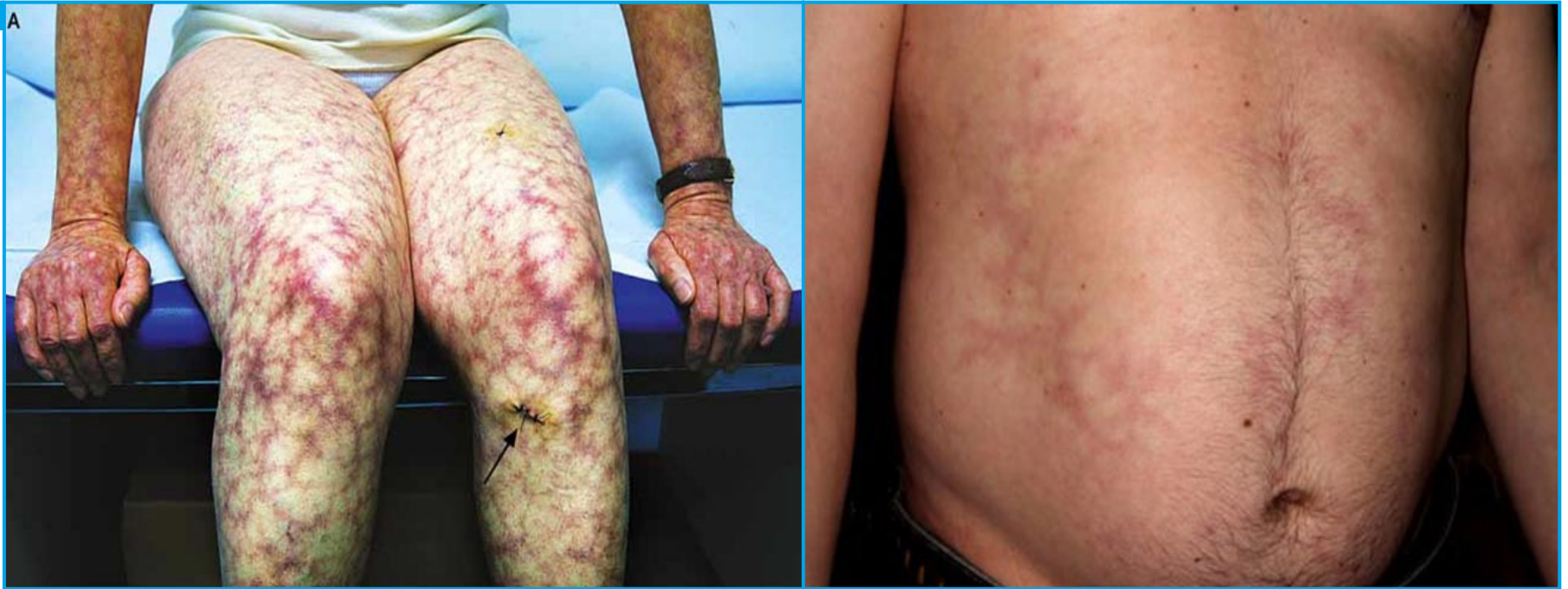



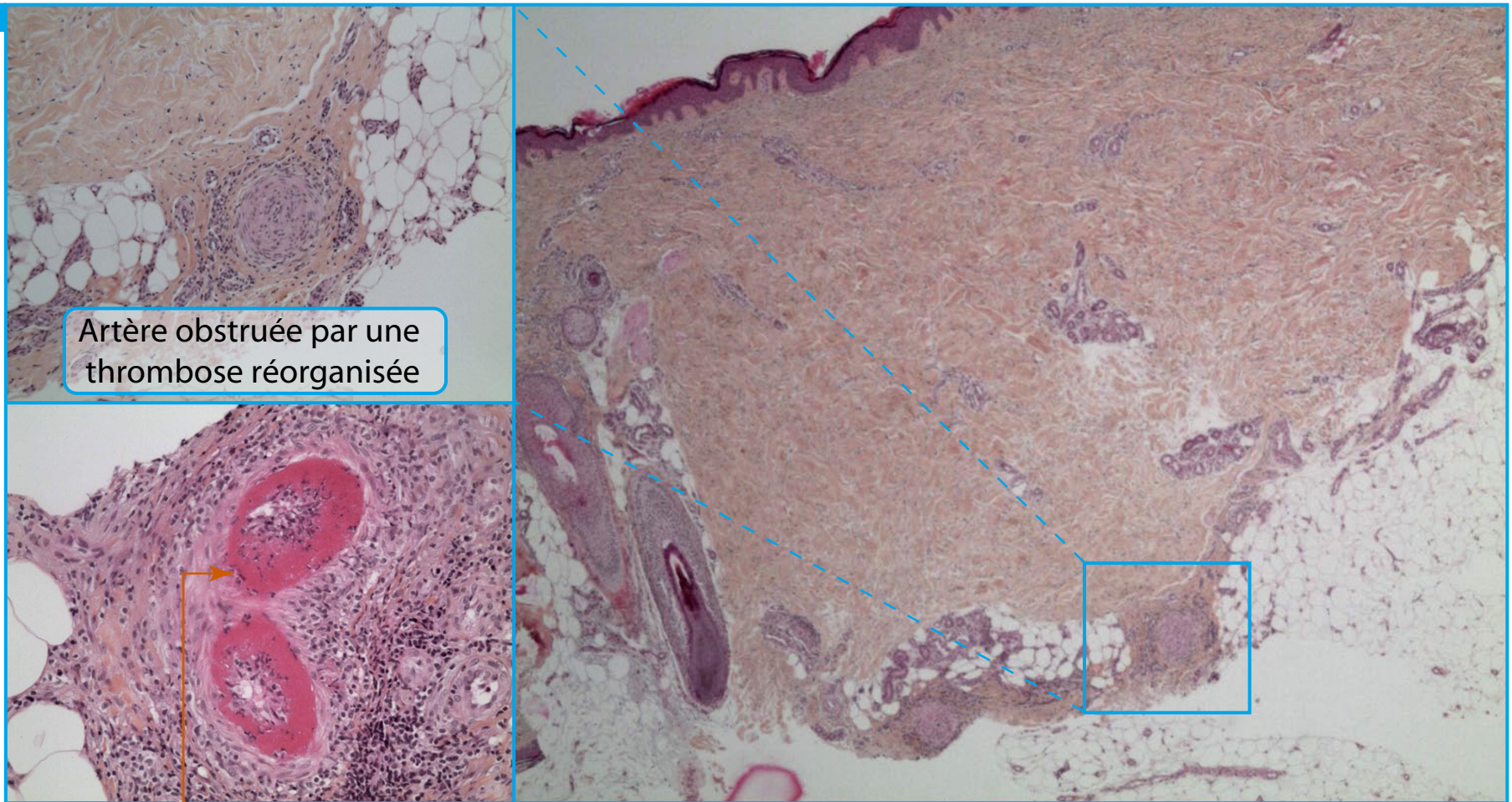
Cocardes



Pseudo-cocardes

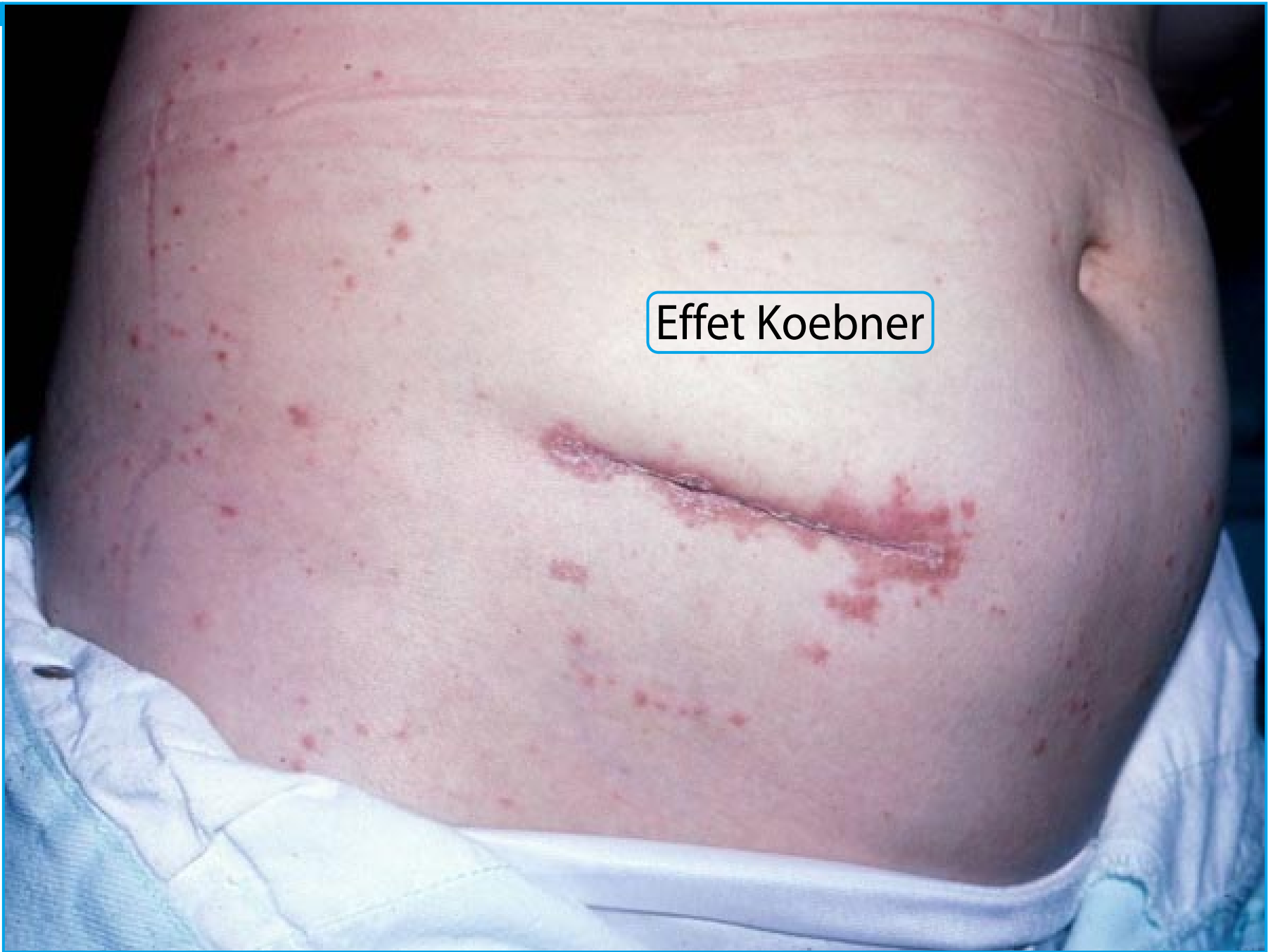

Livedo

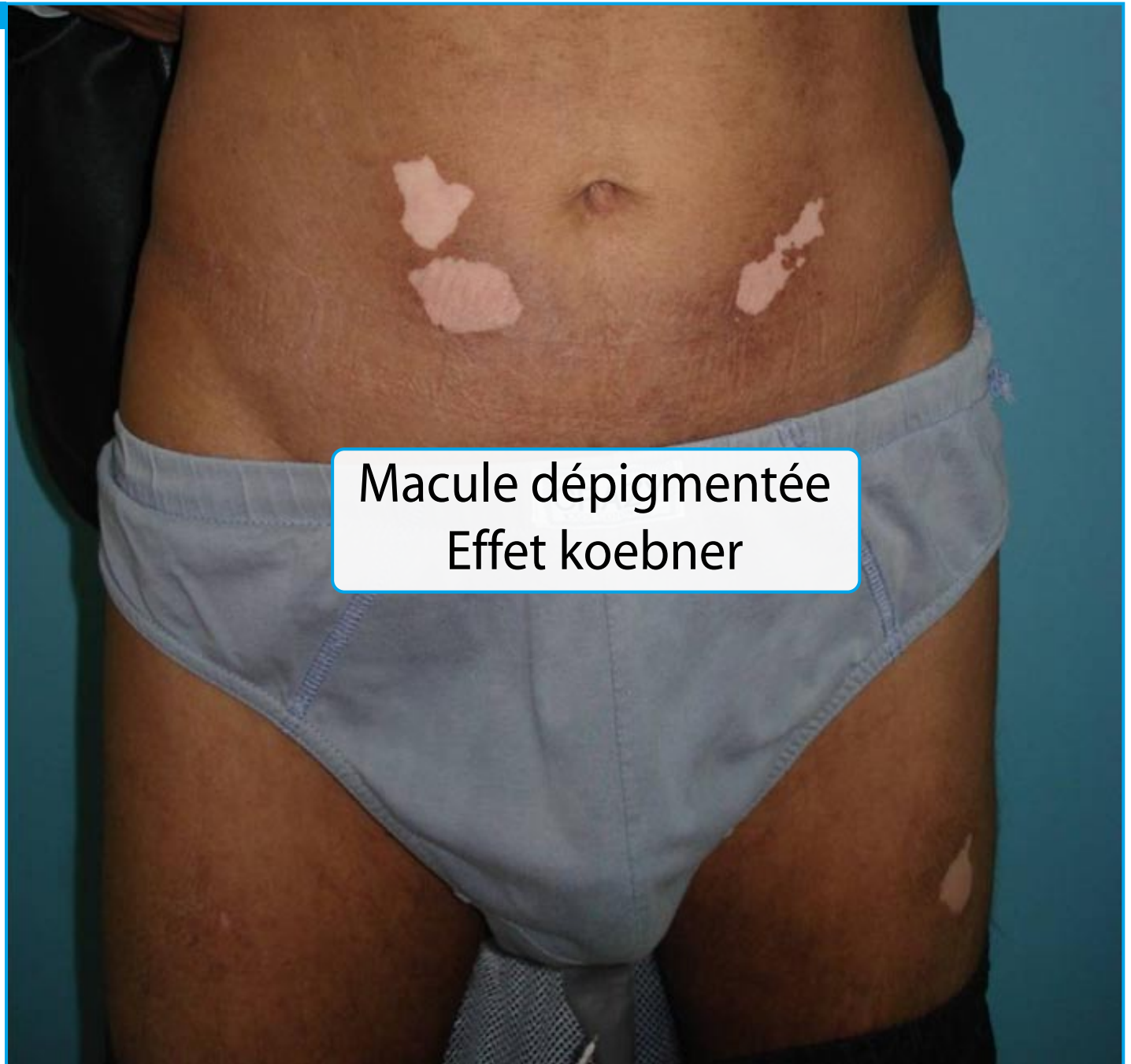

Artère obstruée par une thrombose réorganisée

Nécrose fibrinoïde de la paroi d'une artériole
Vascularite nécrosante



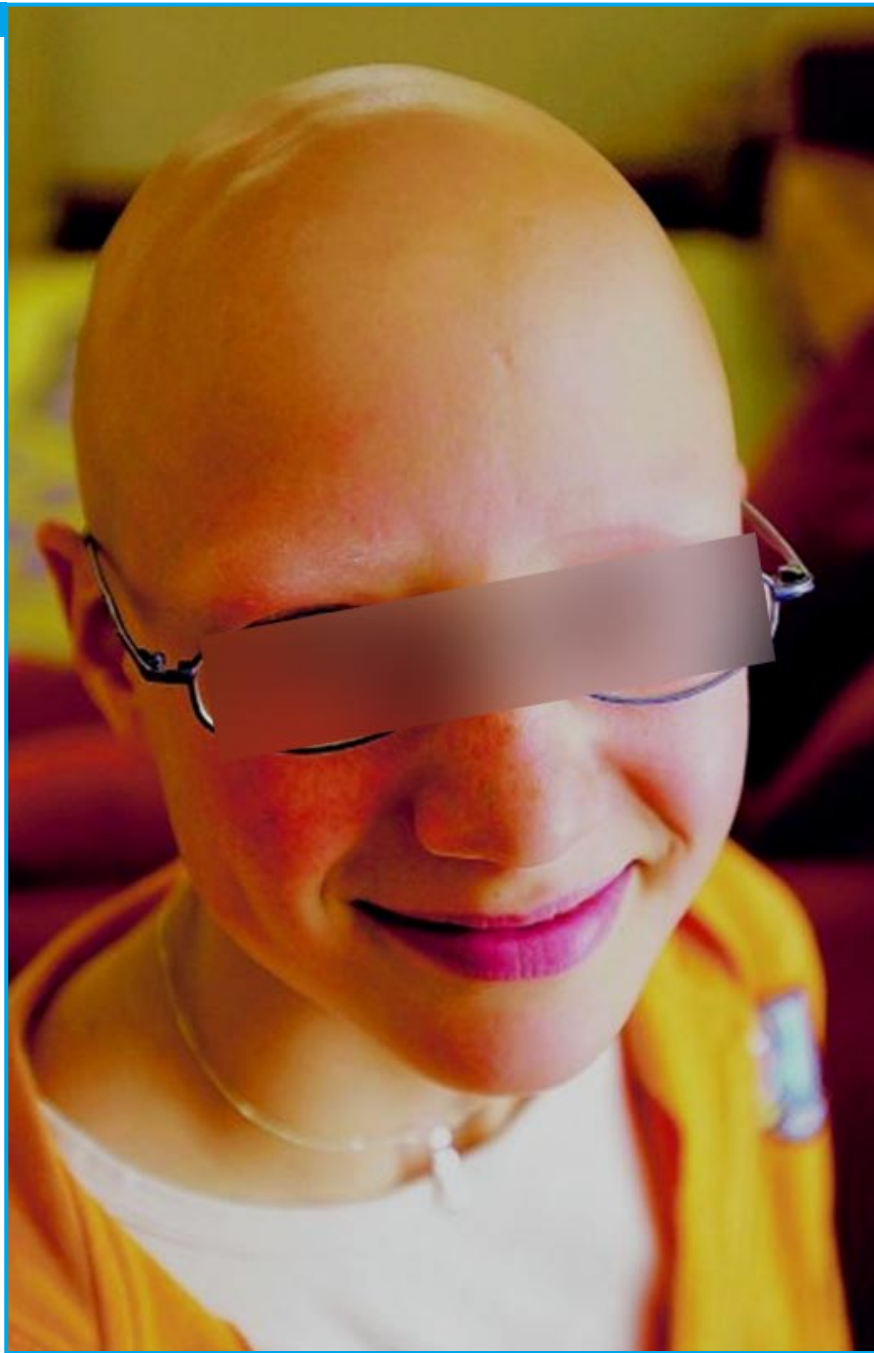Effet Koebner



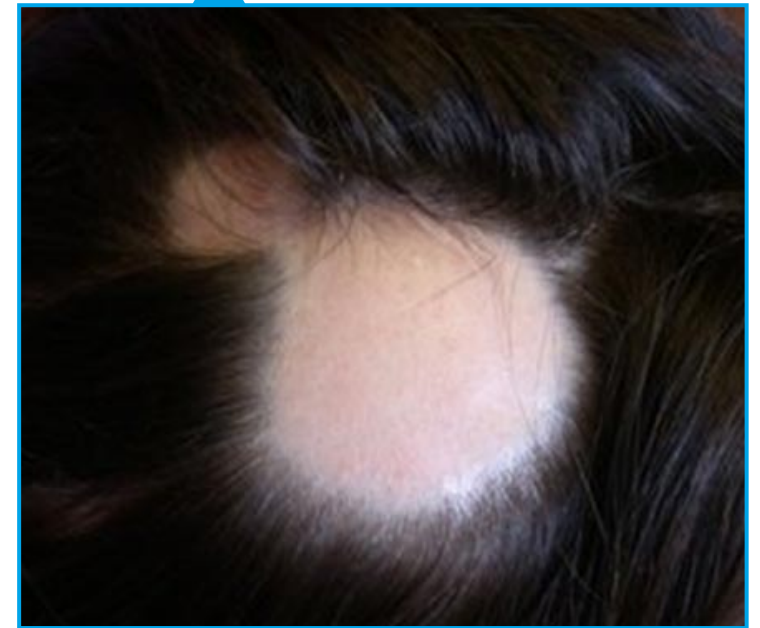Topographie dermatologique

■ Dr. Anne Croué

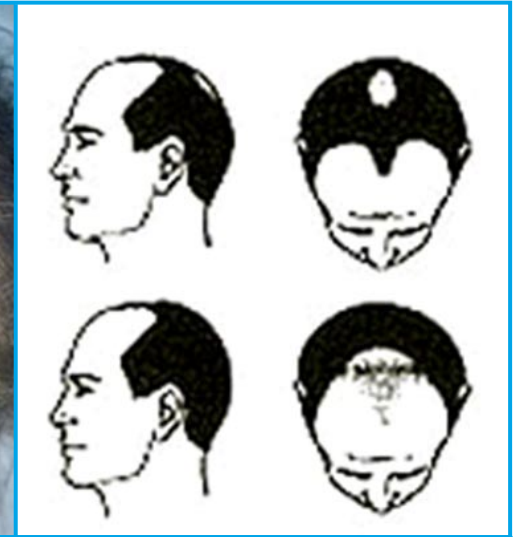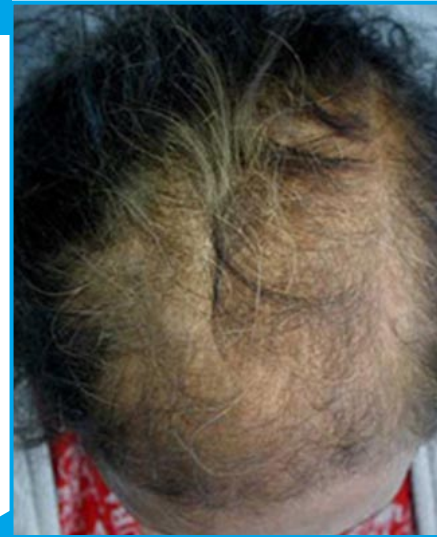■ Pr. Ludovic Martin



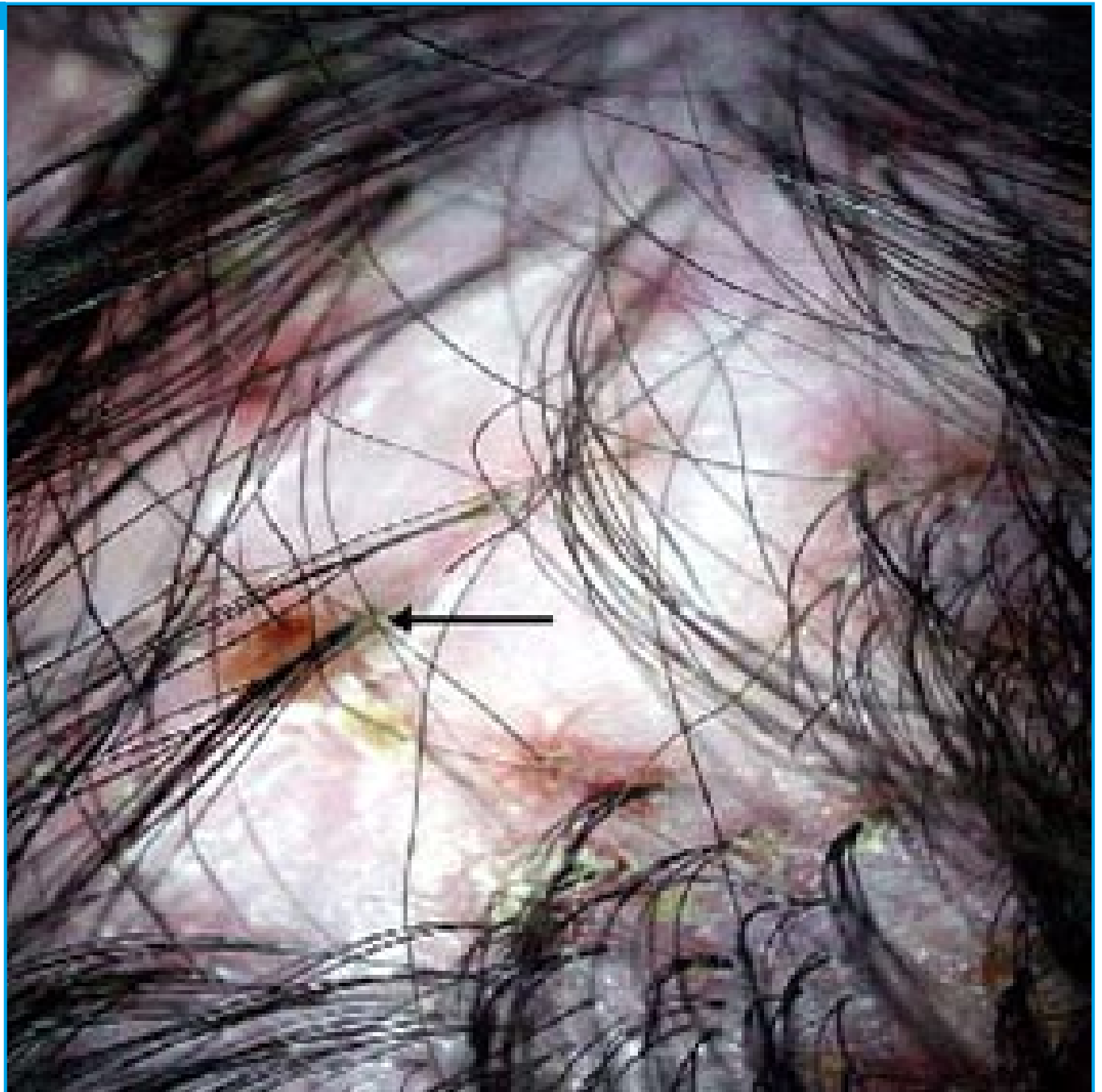Alopécie



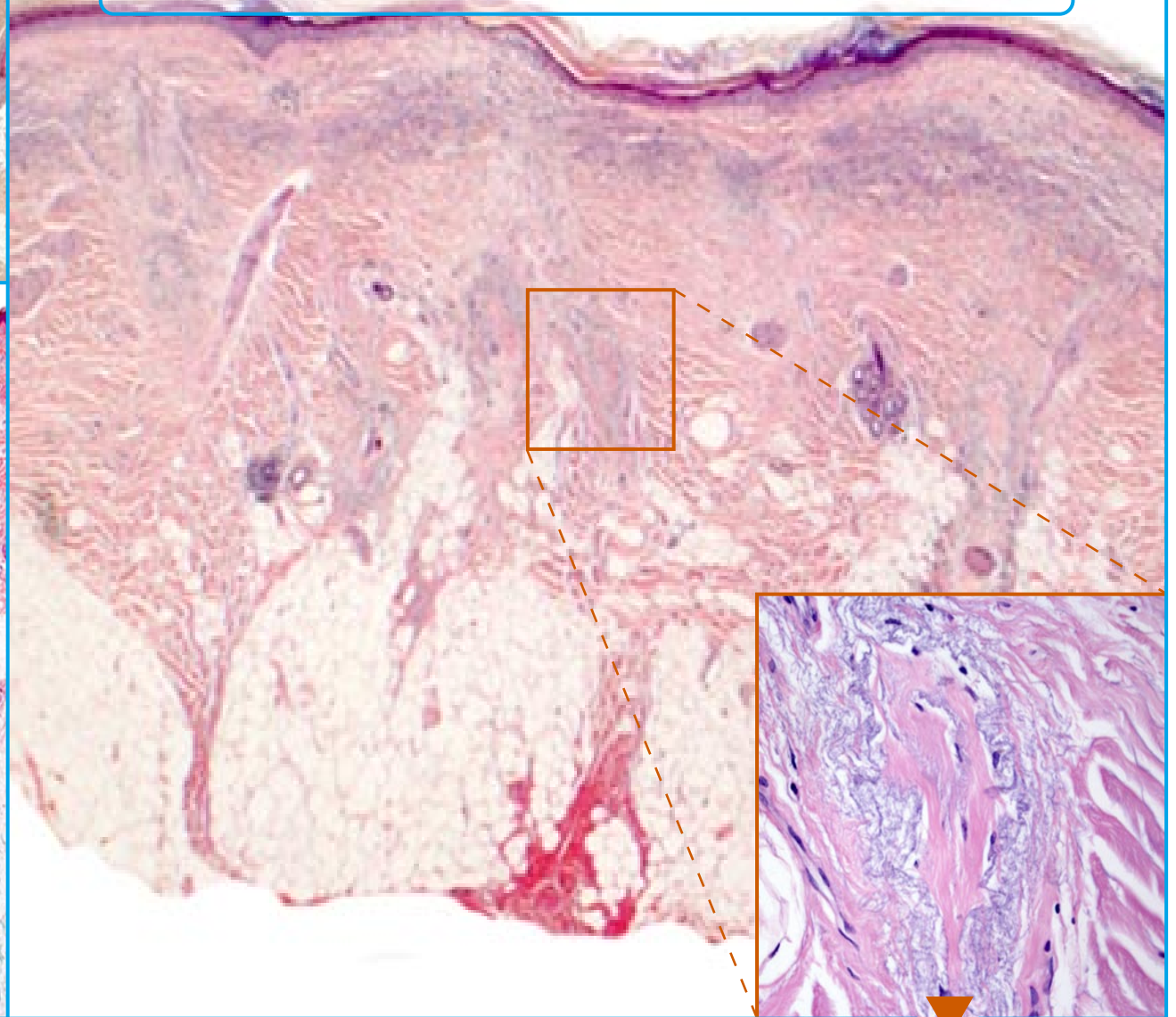
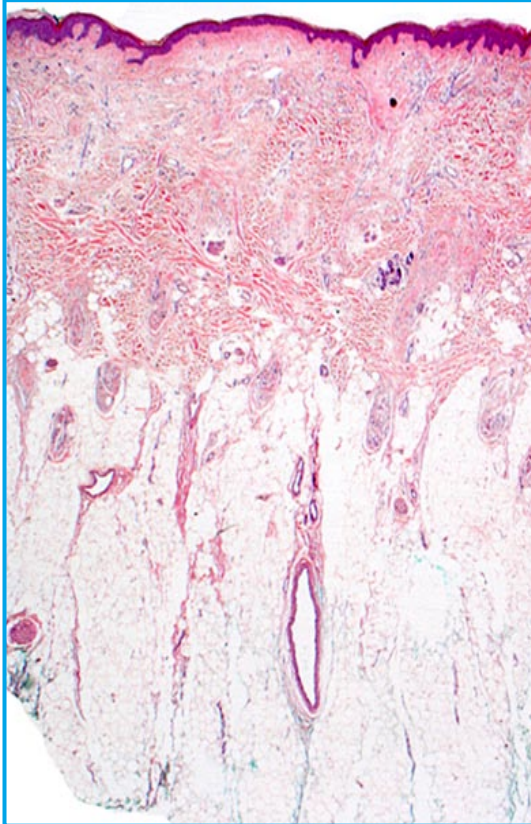
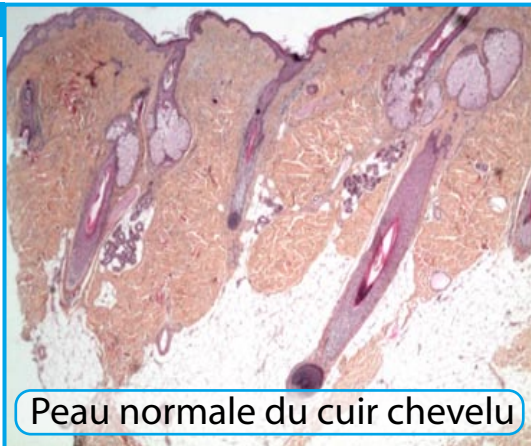
■ Alopécie androgénique

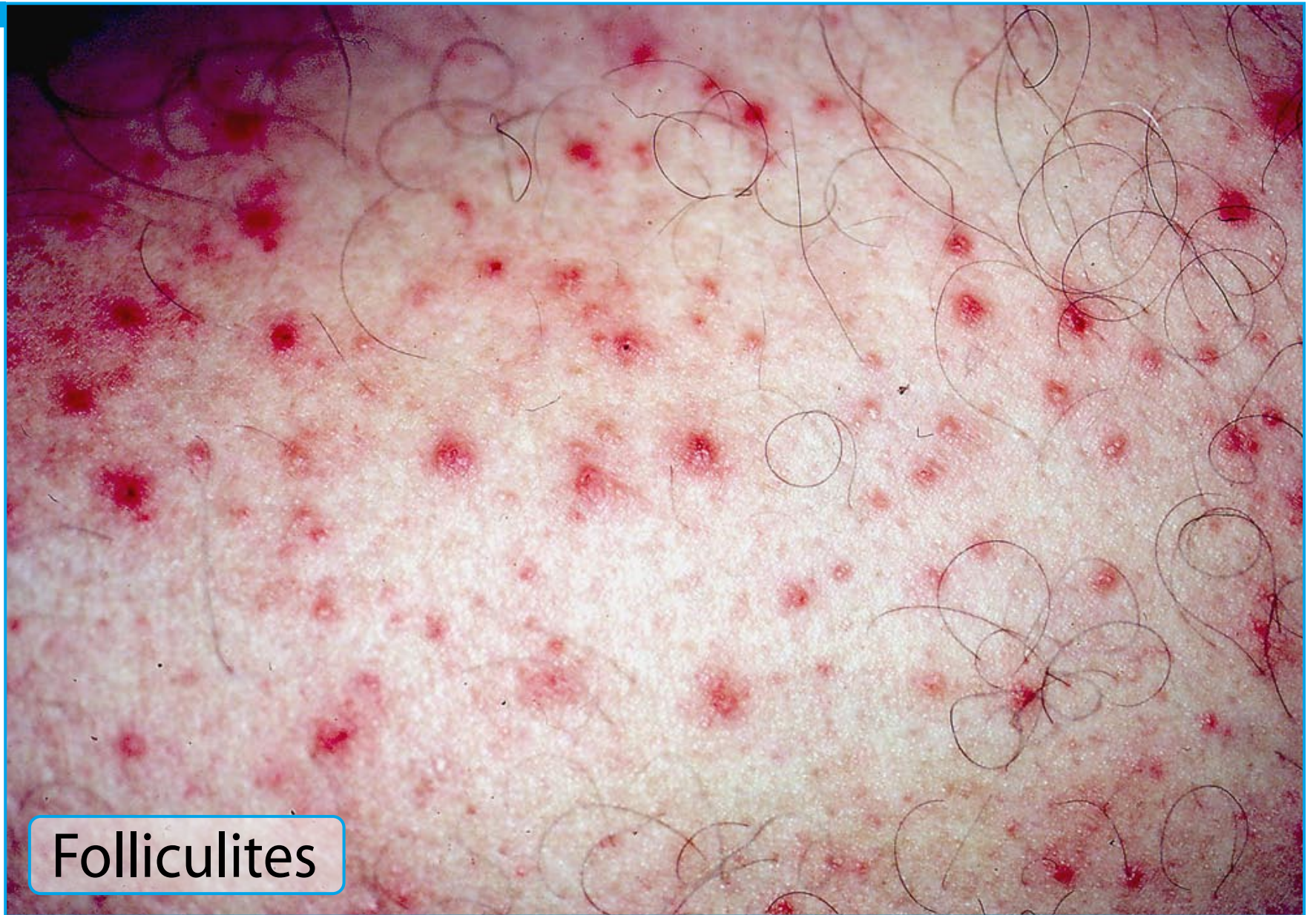

■ Alopécie cicatricielle

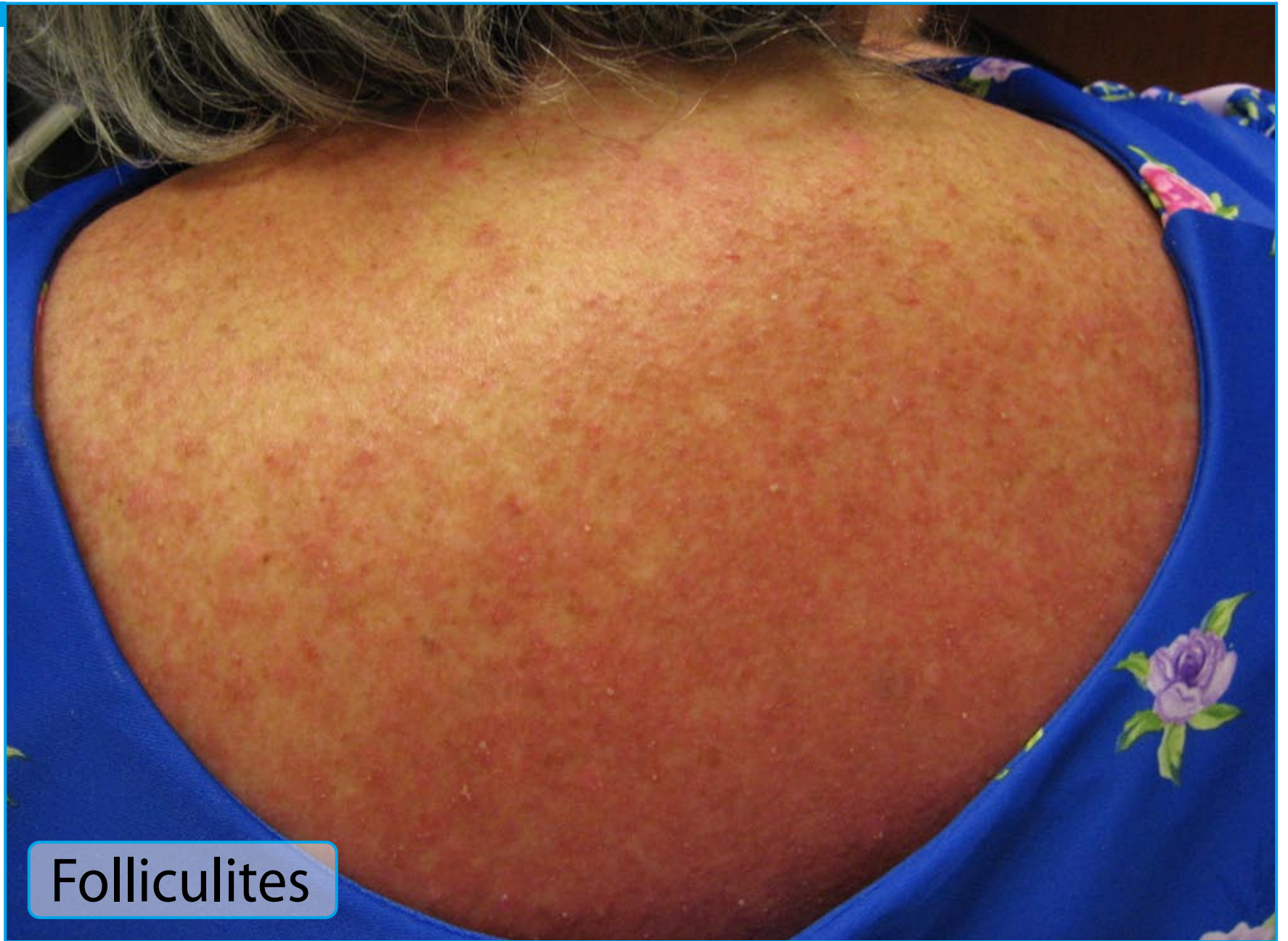

Disparition des follicules pilo-sébacés



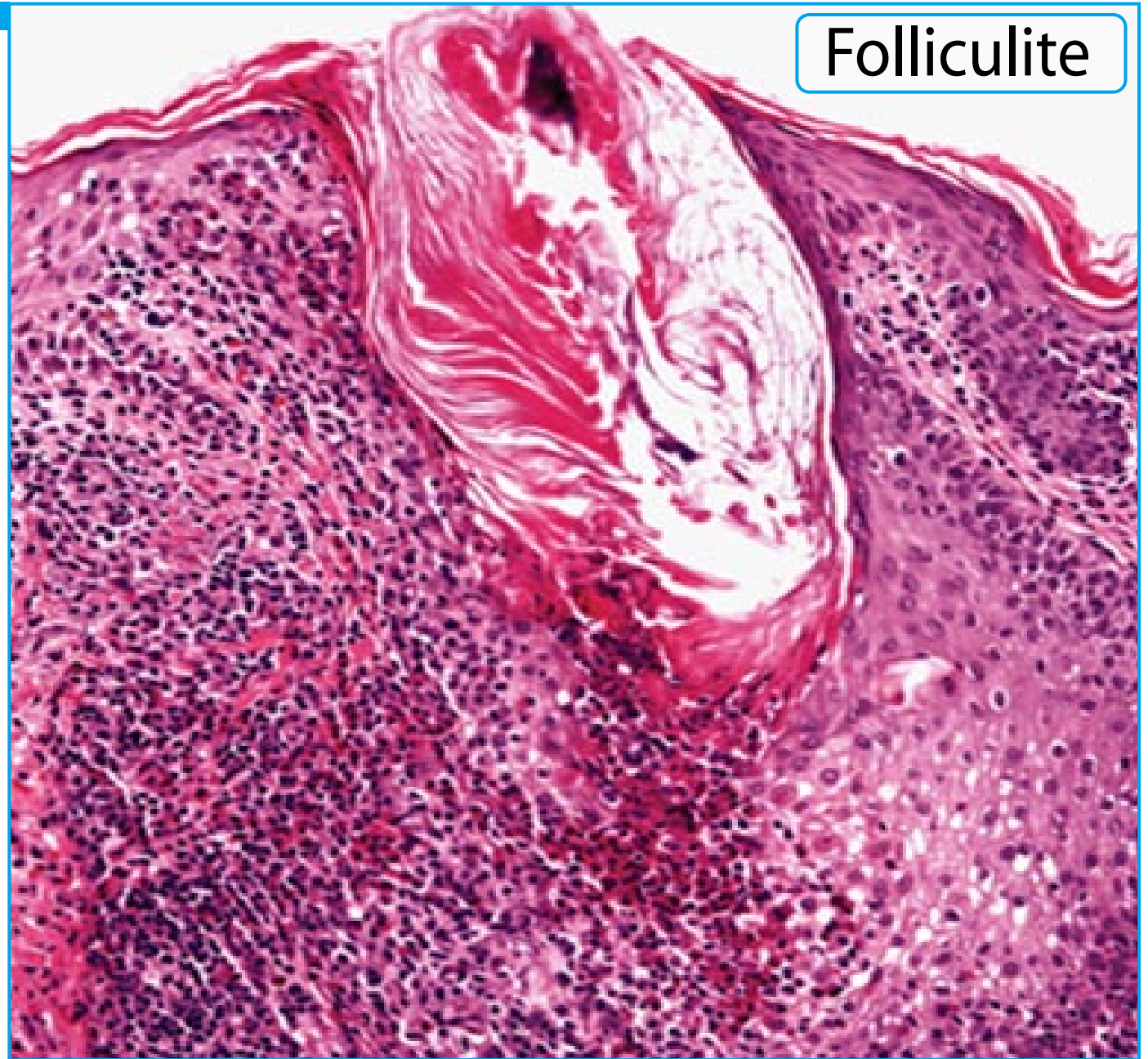


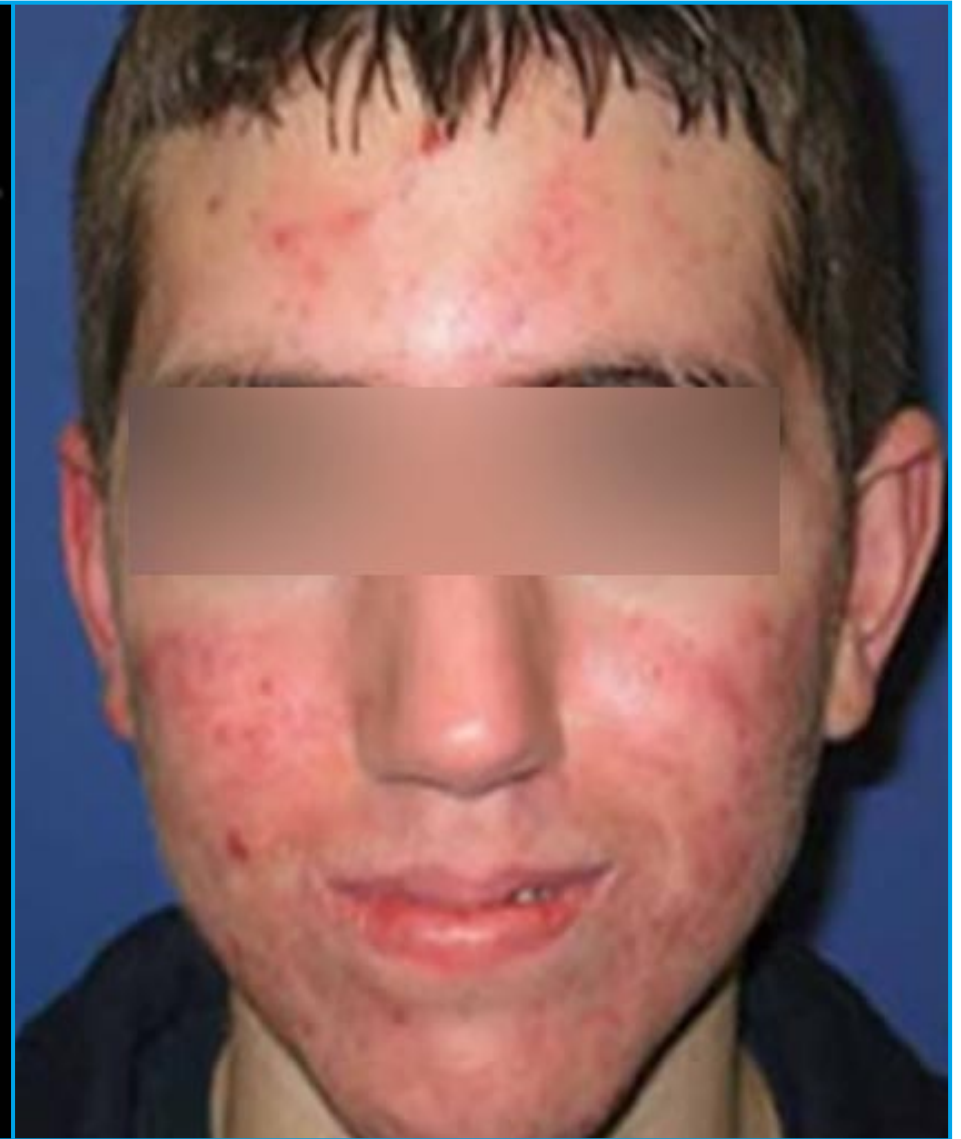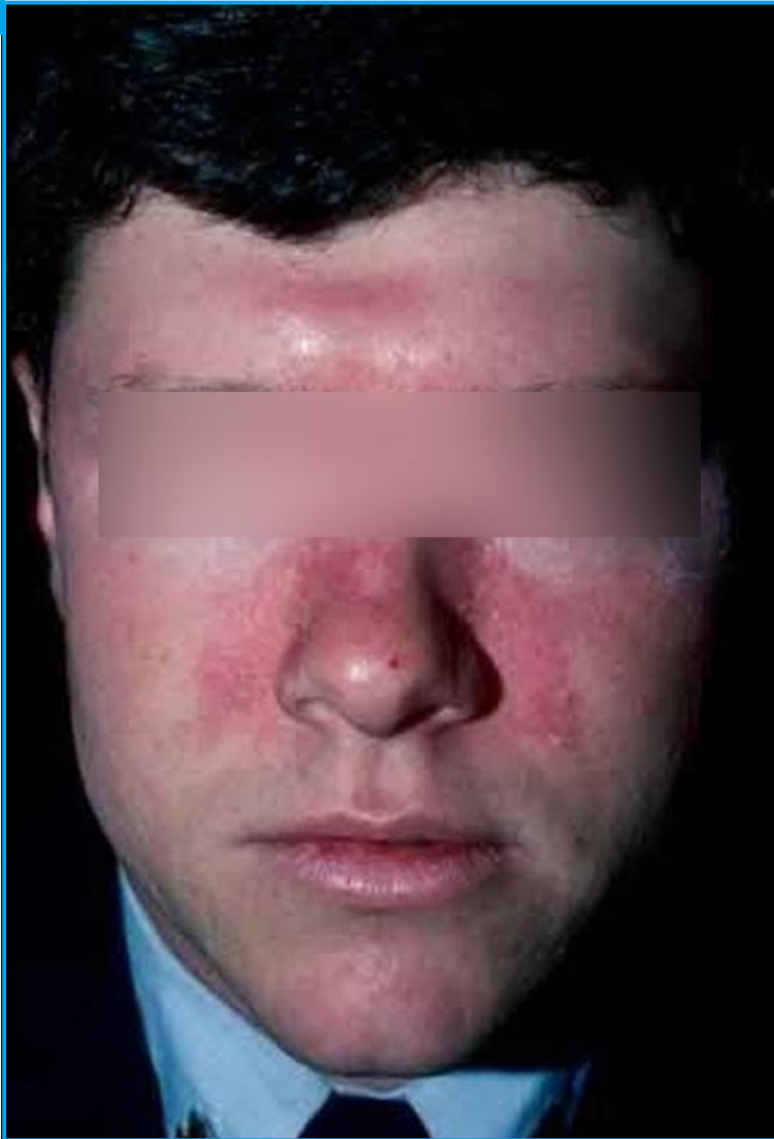Folliculites



Folliculites

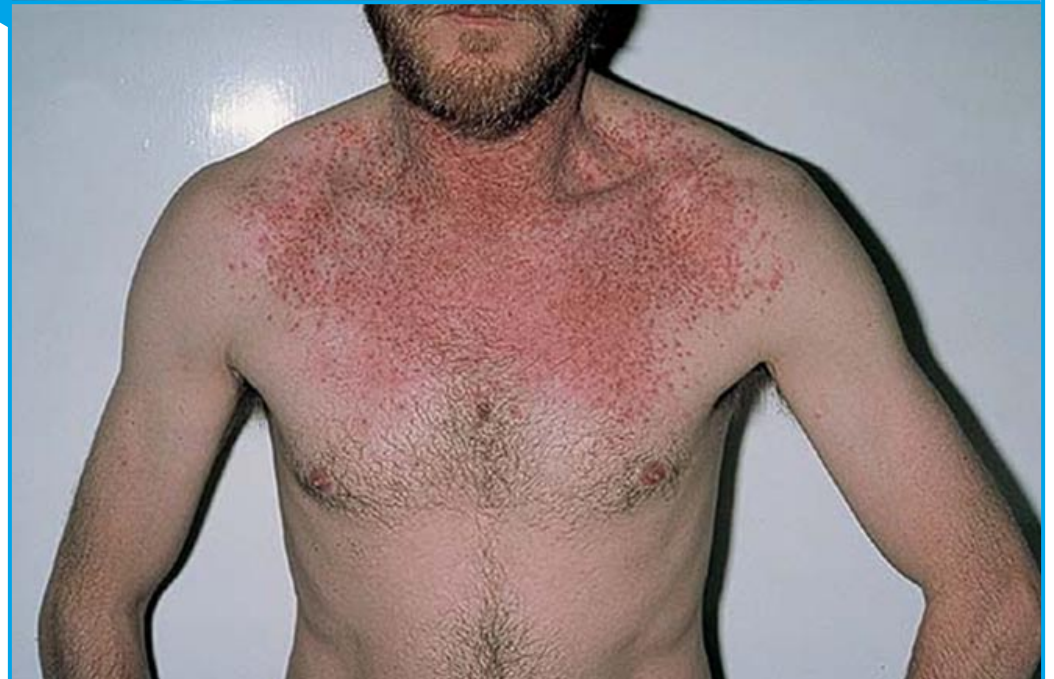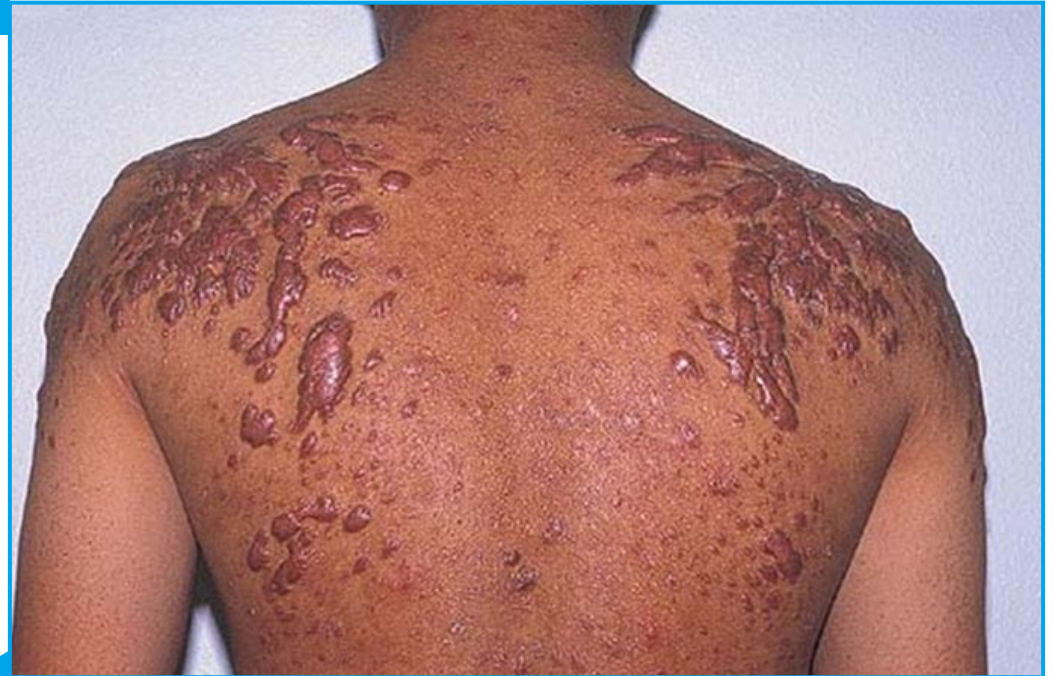Folliculite





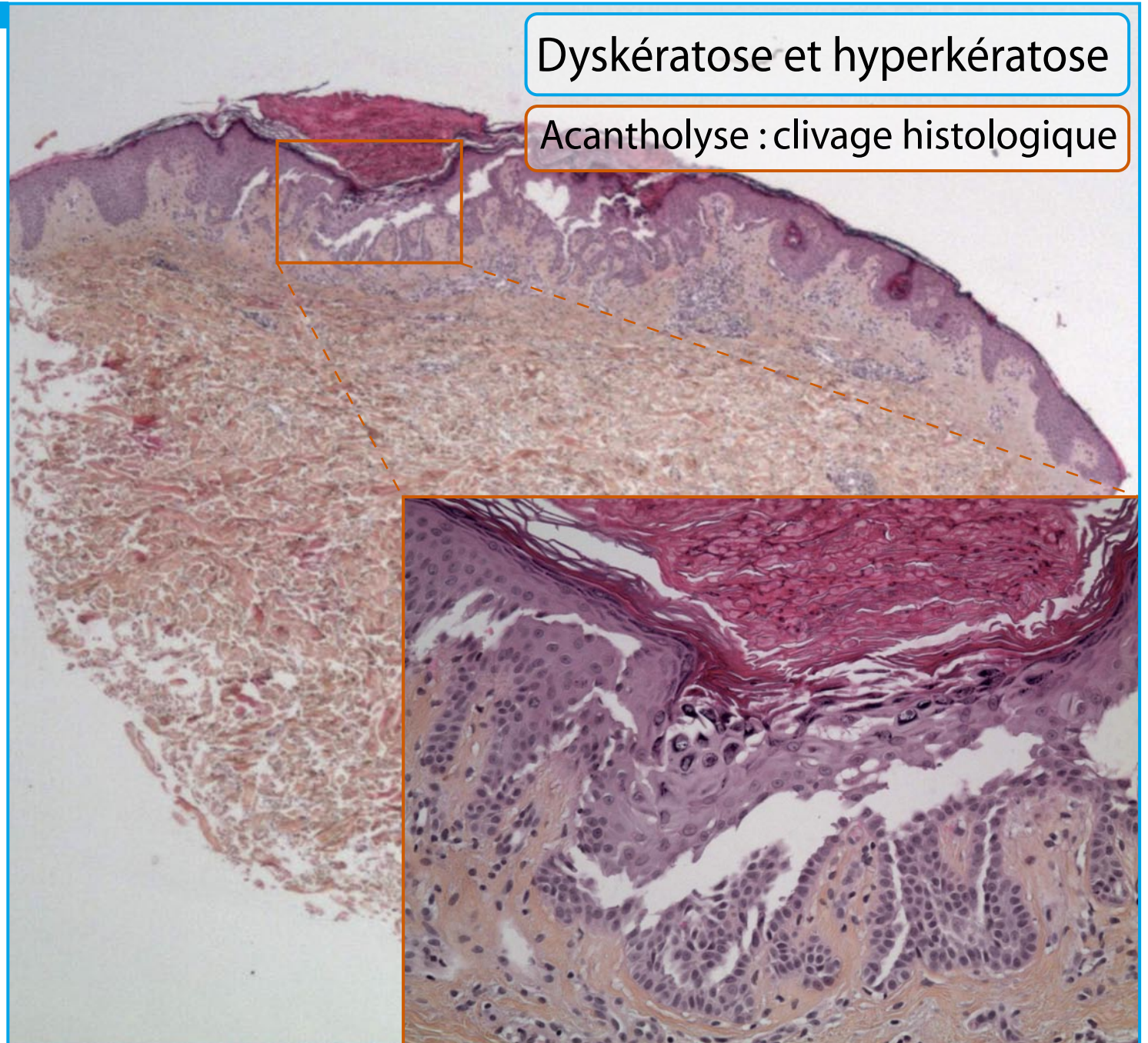
■ Régions séborrhéiques _____

■ Régions séborrhéiques

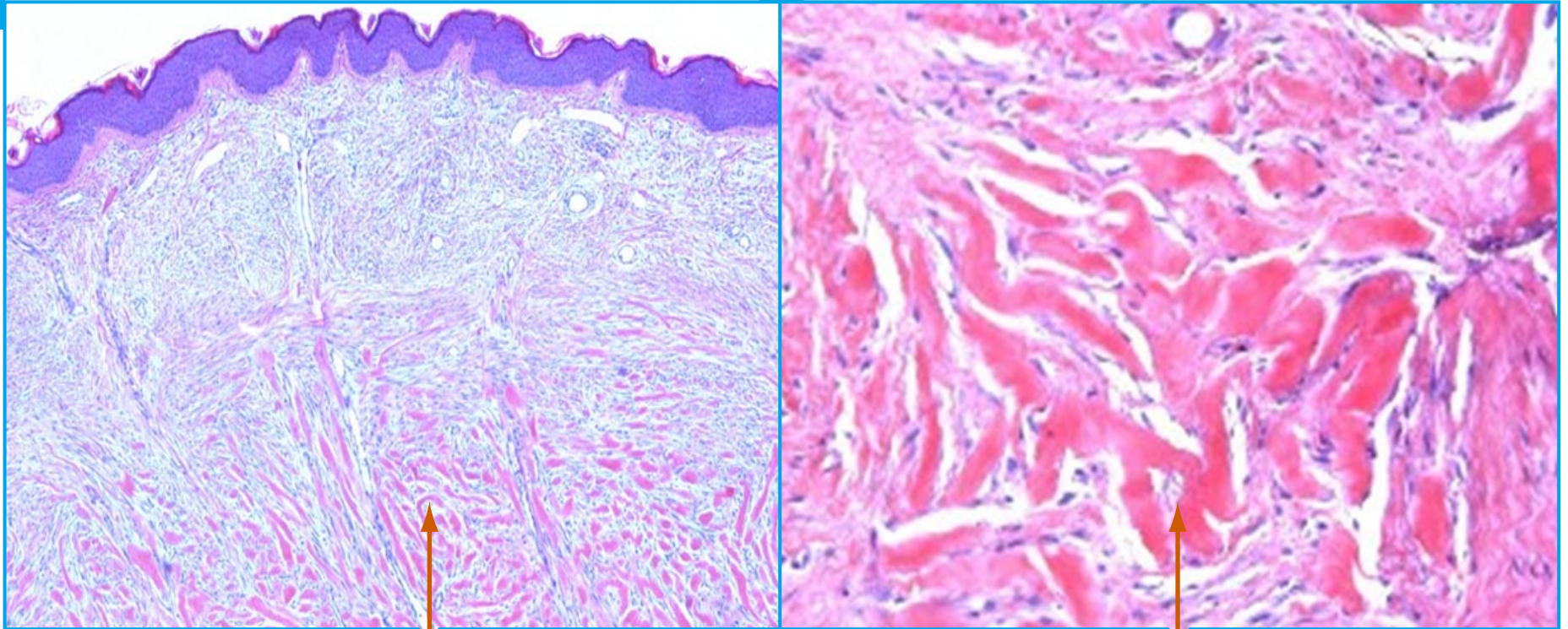


Dyskératose et hyperkératose

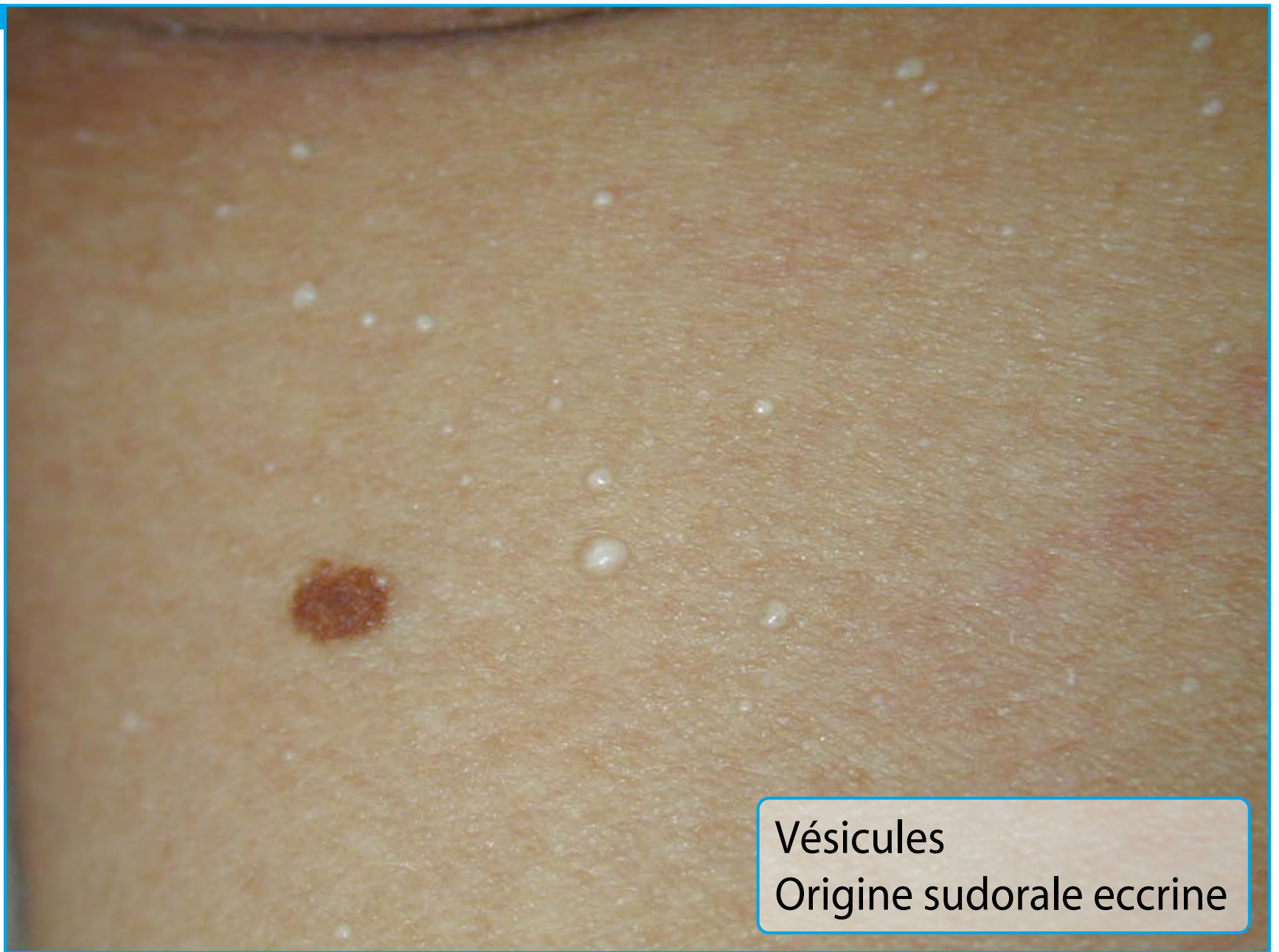Acantholyse : clivage histologique



Chéloïde

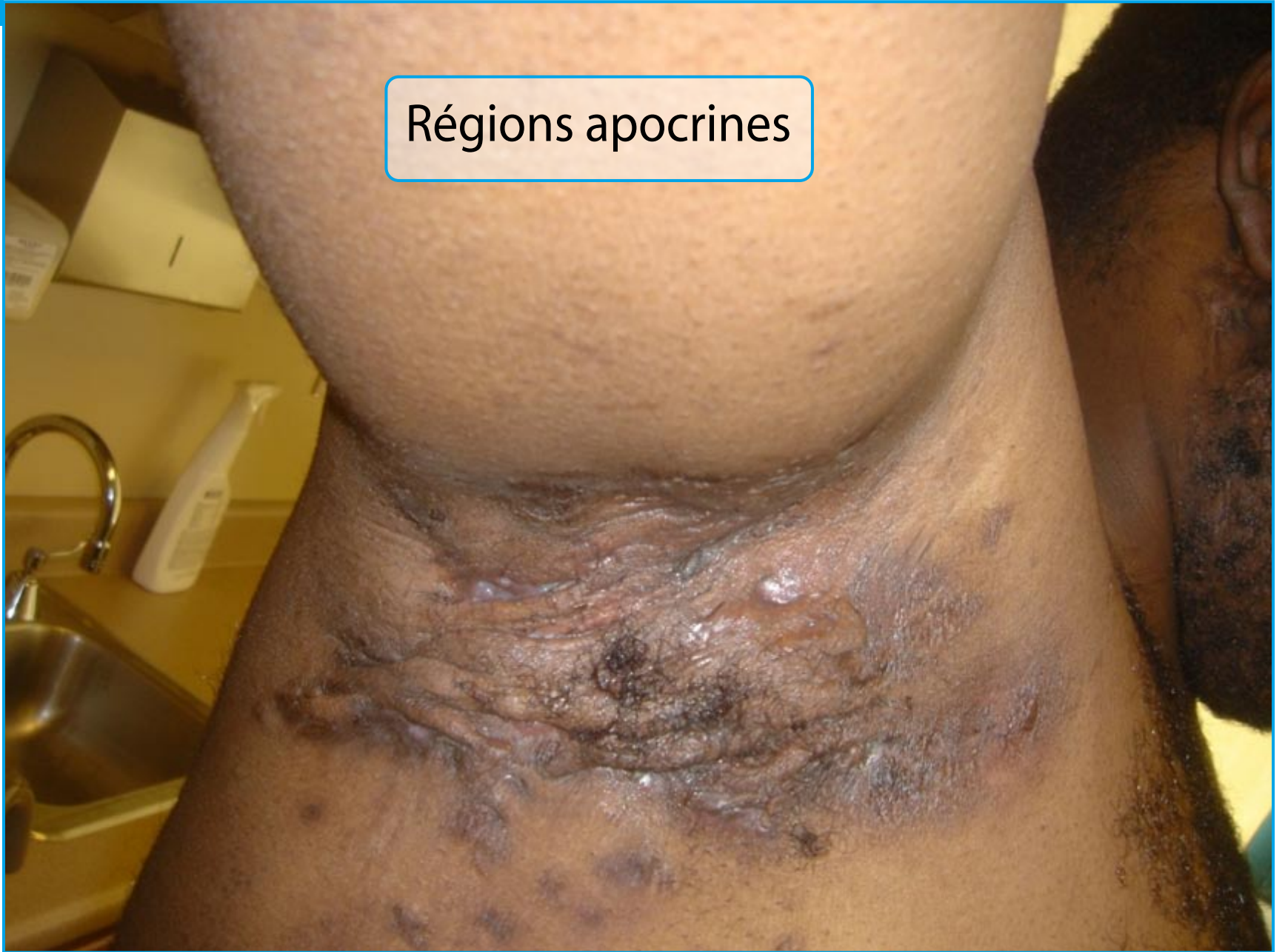

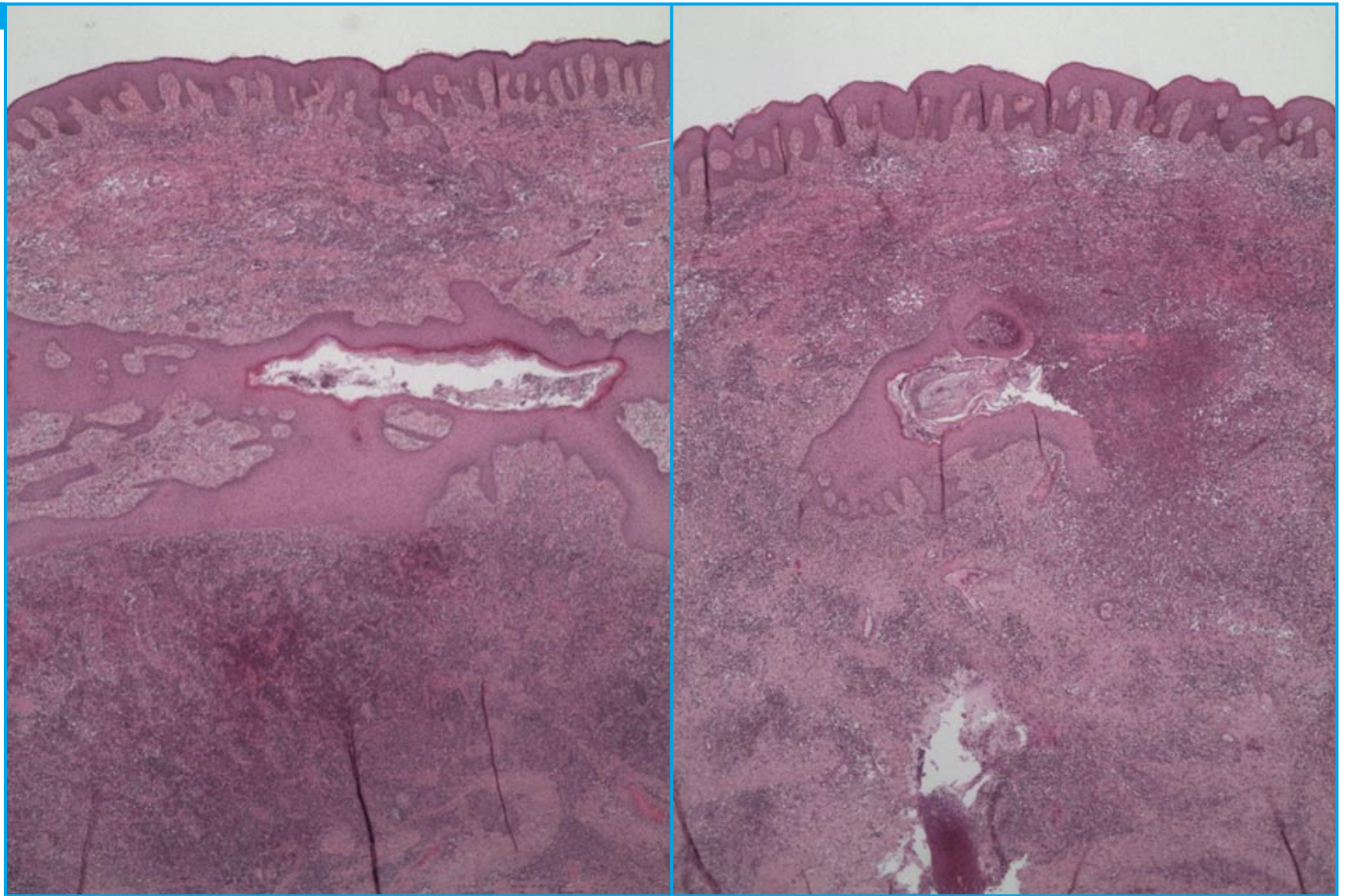
Faisceaux de collagène hyalins
intra dermiques



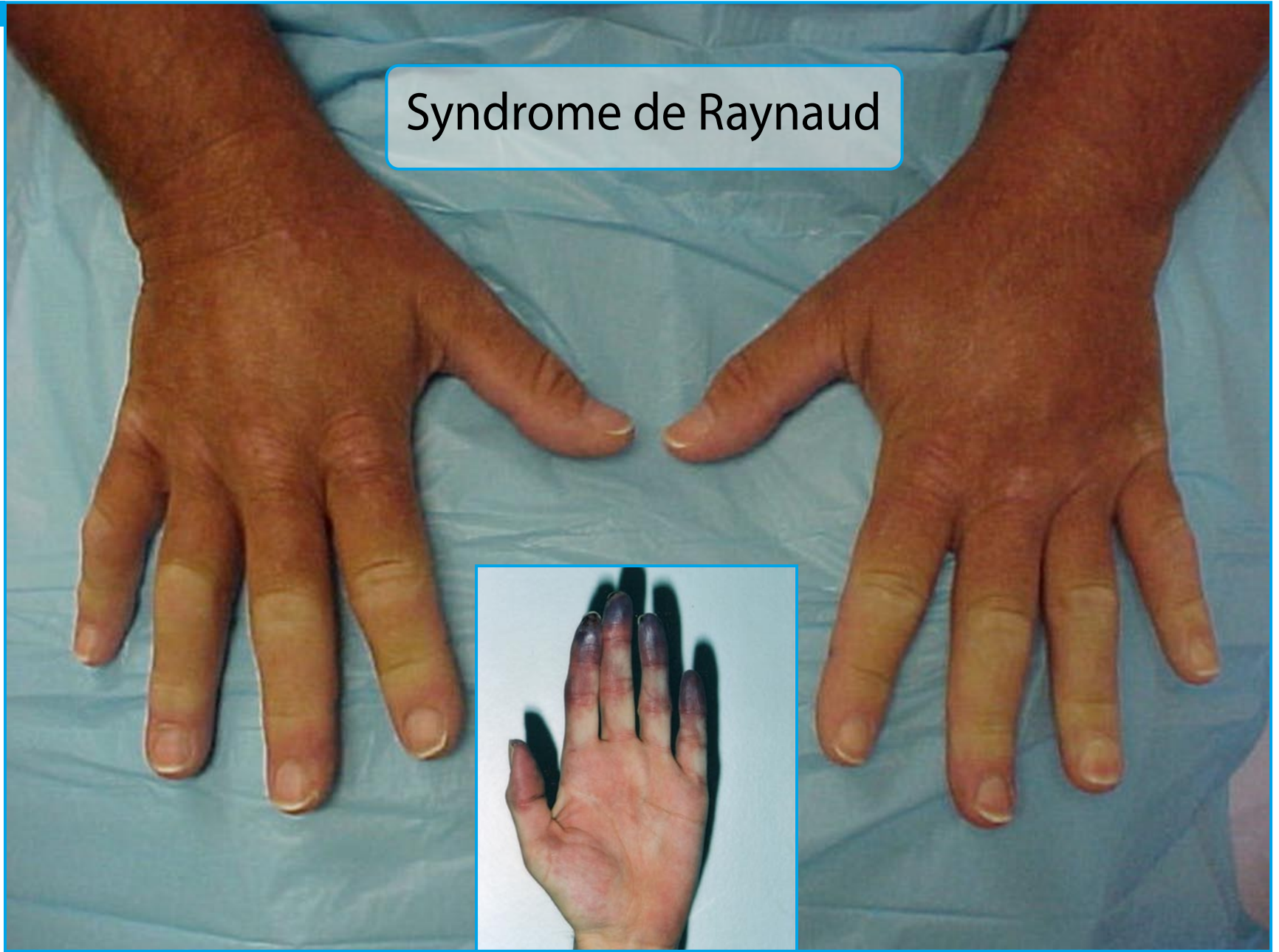Vésicules
Origine sudorale eccrine

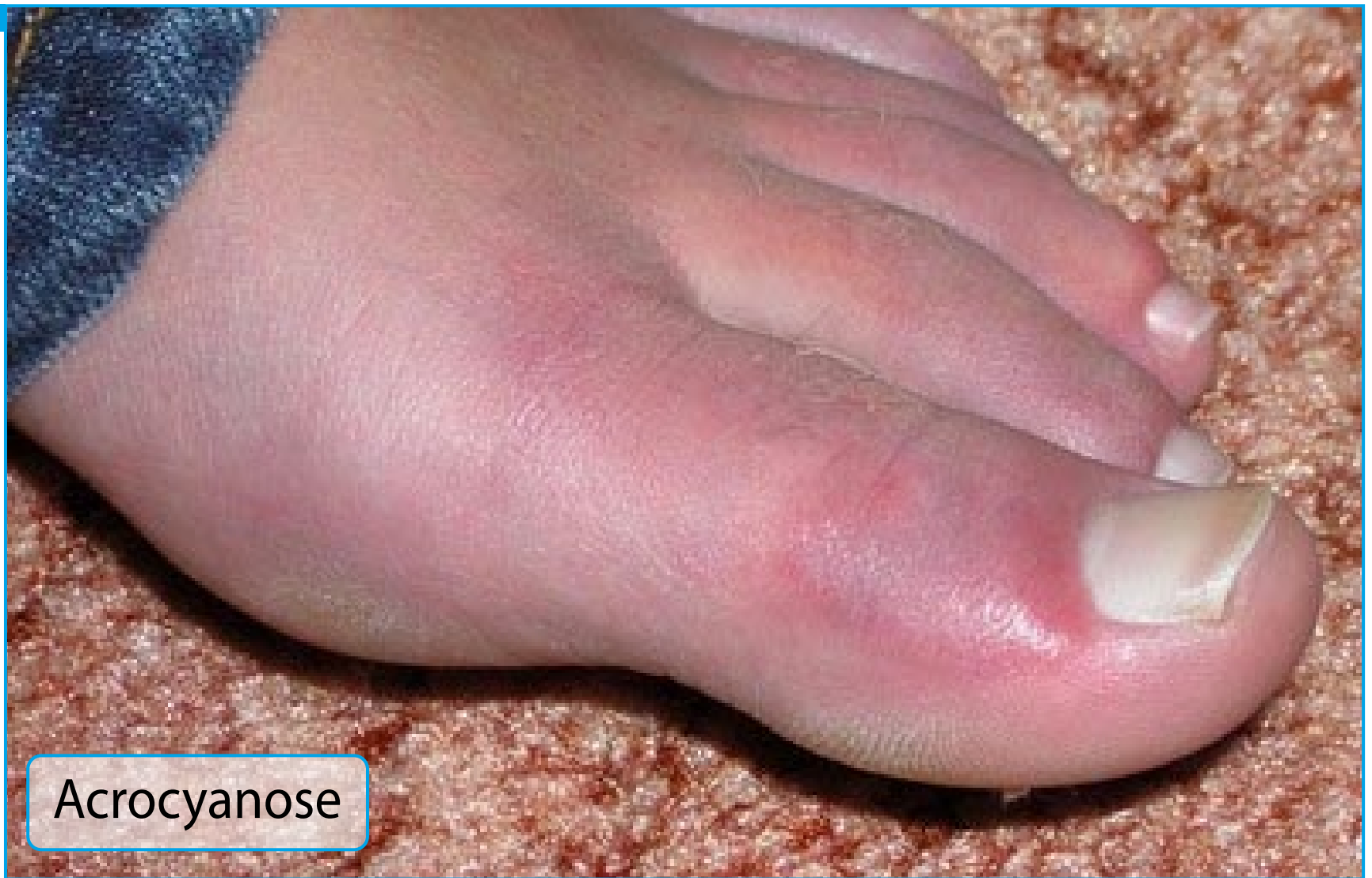Régions apocrines

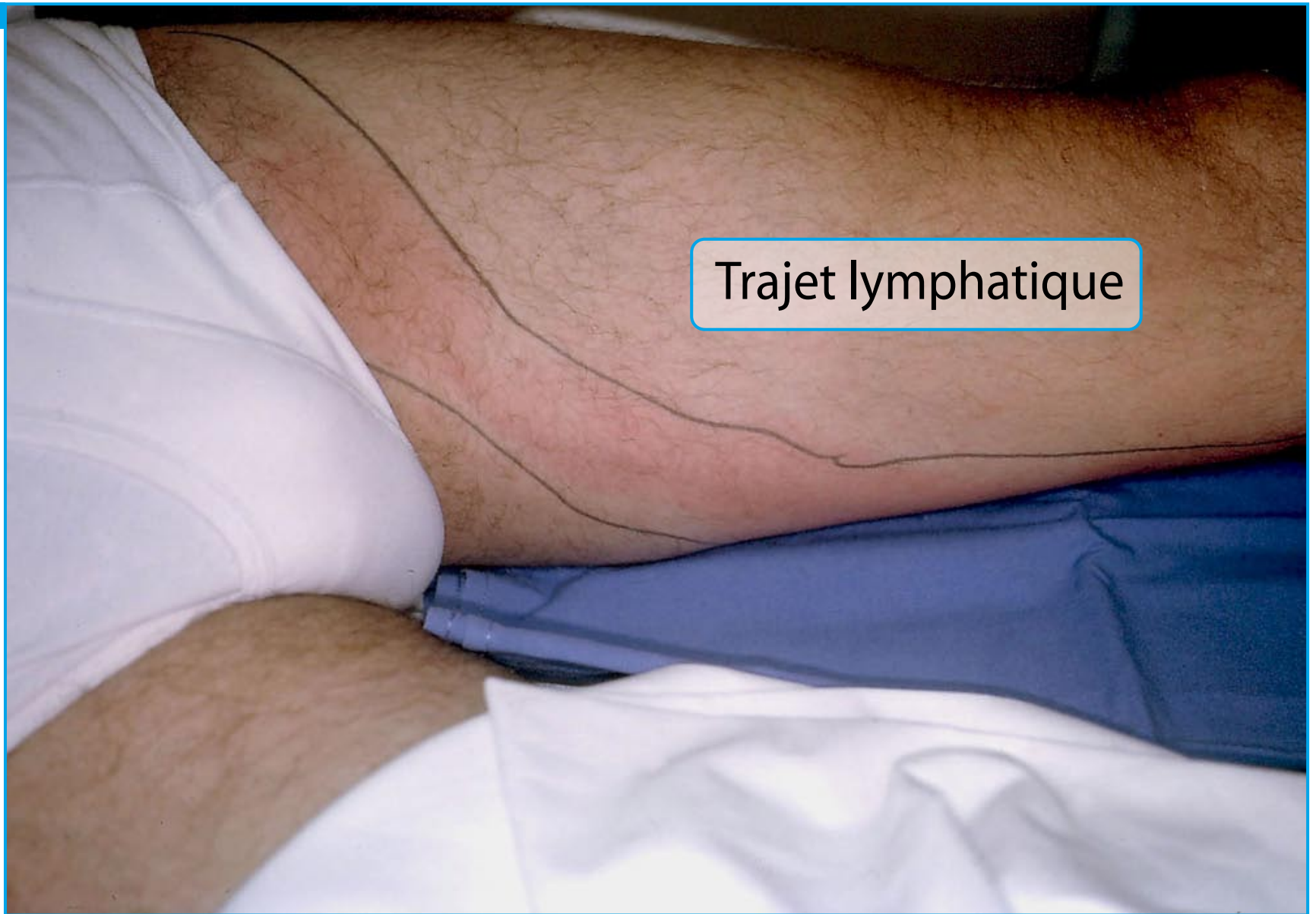



Syndrome de Raynaud

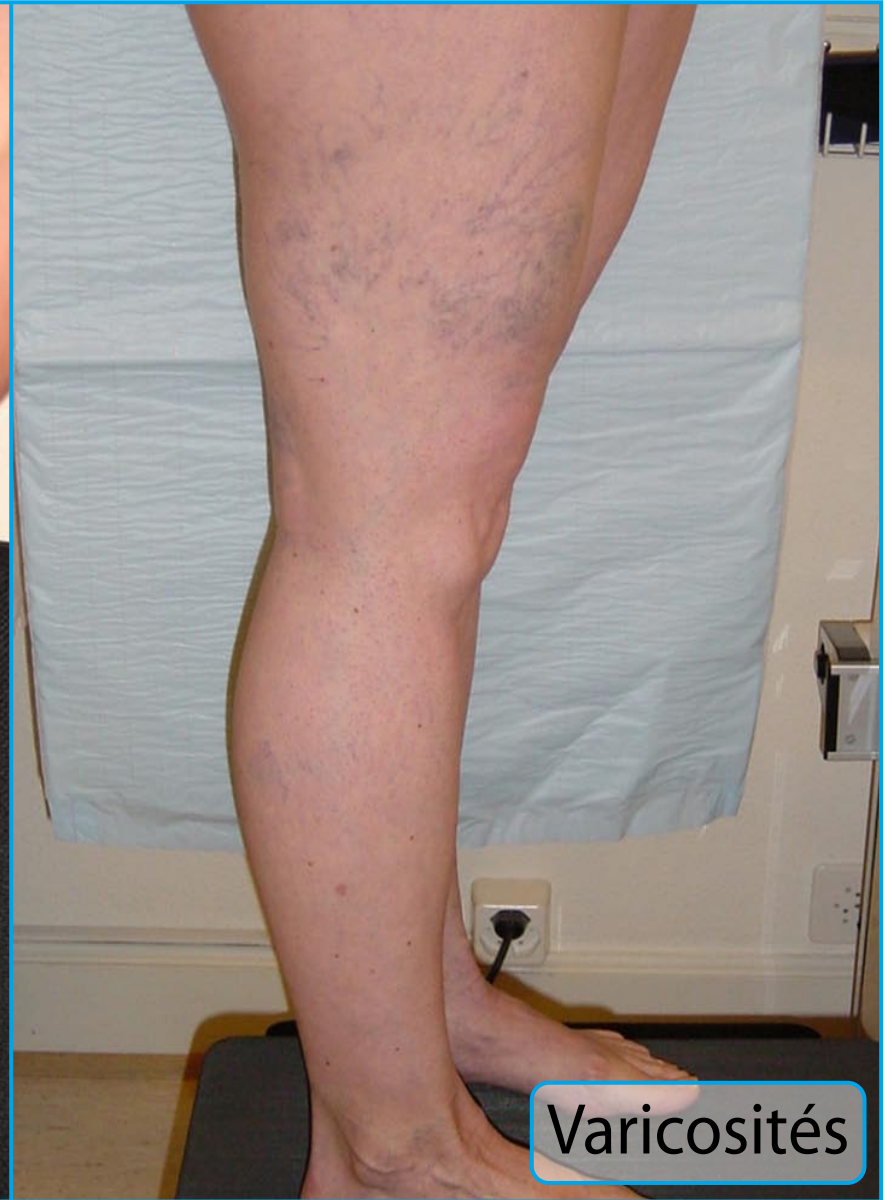
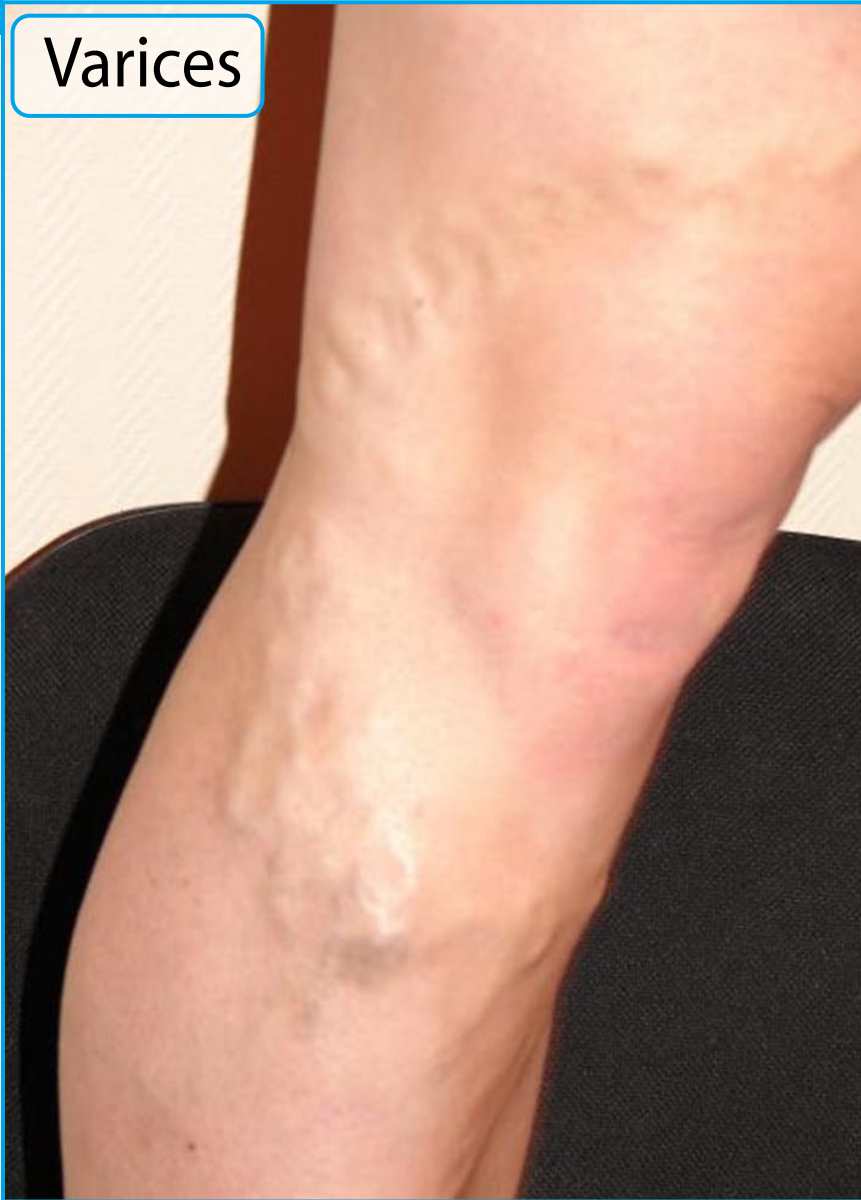




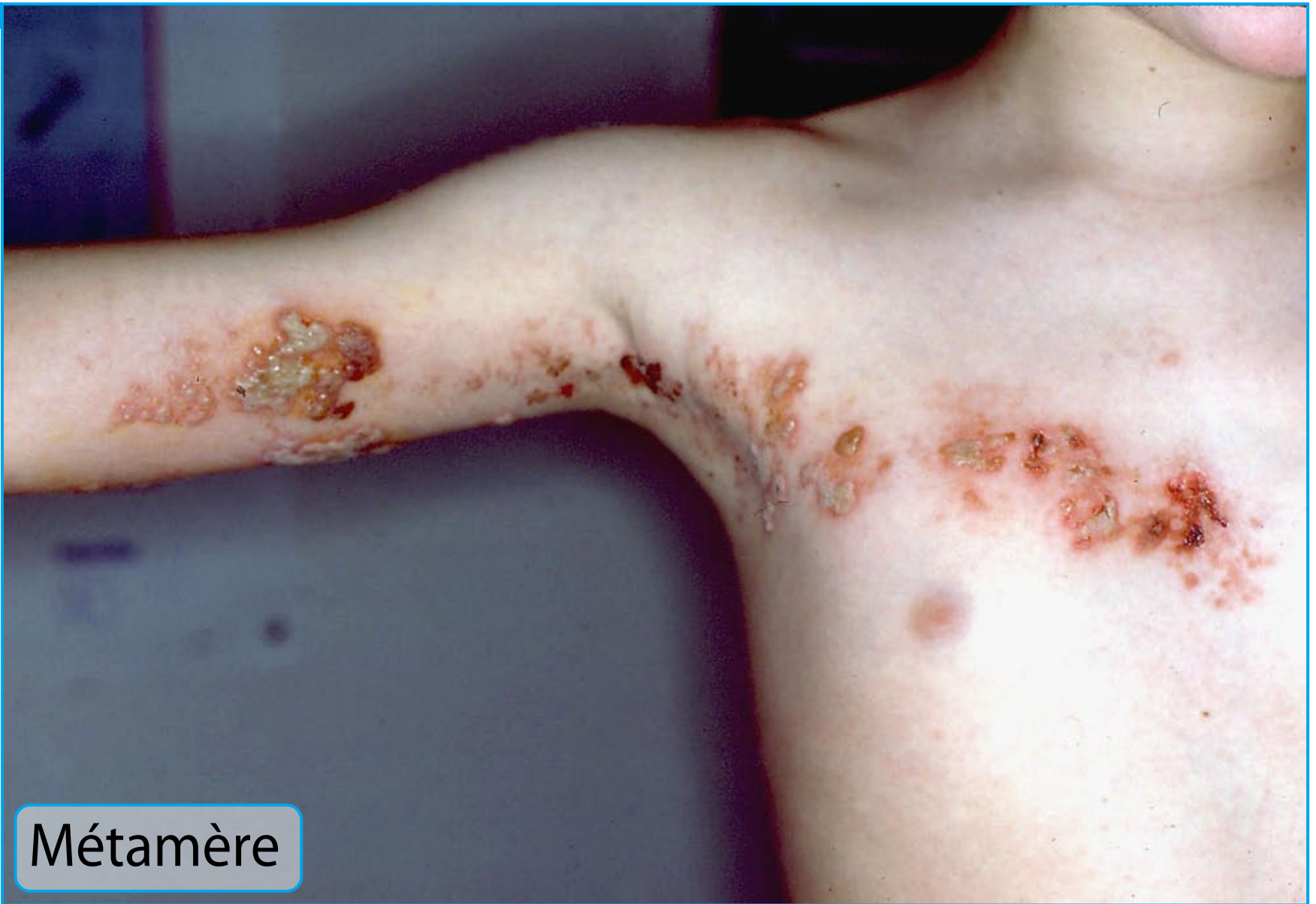Trajet lymphatique

Varices

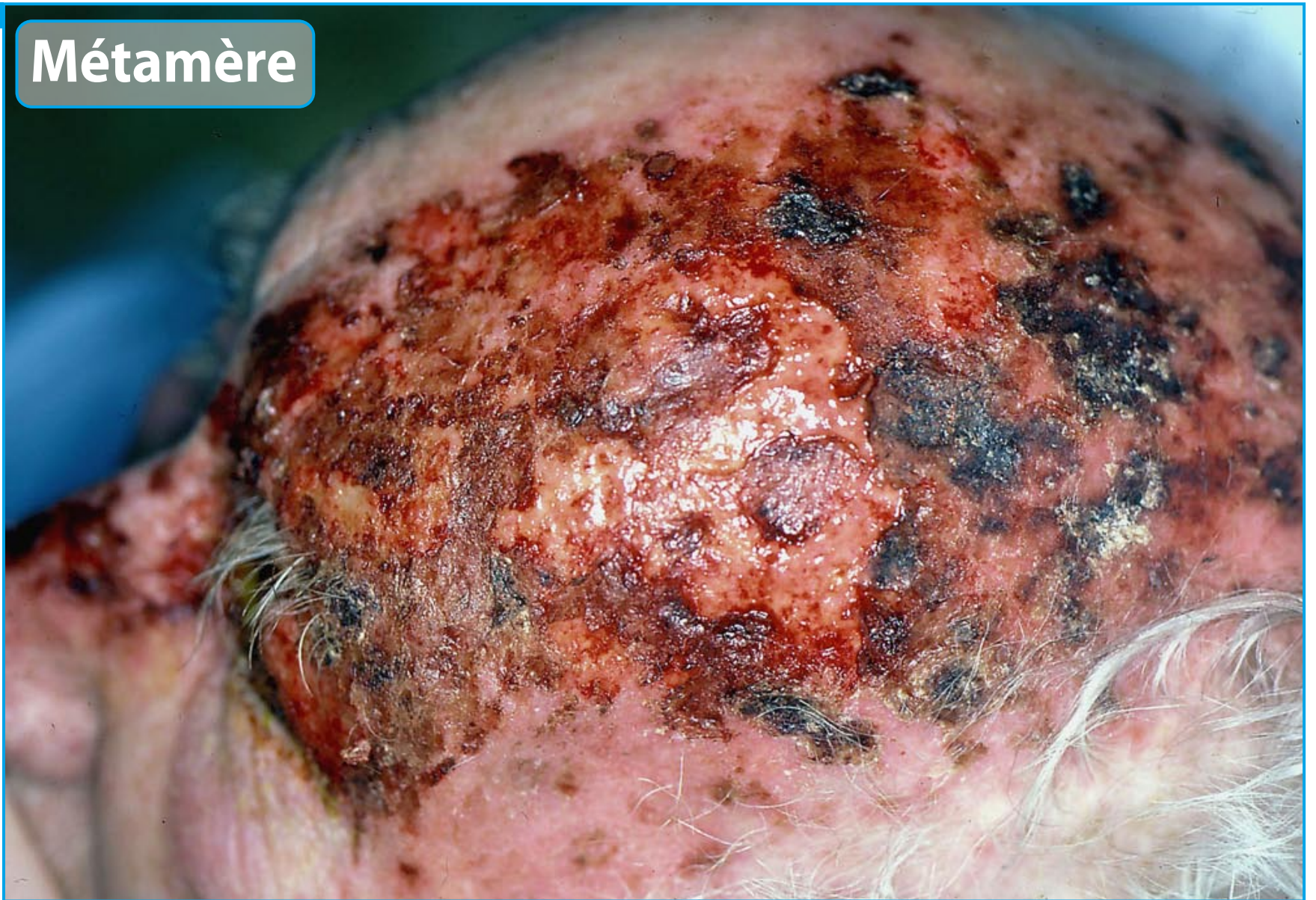

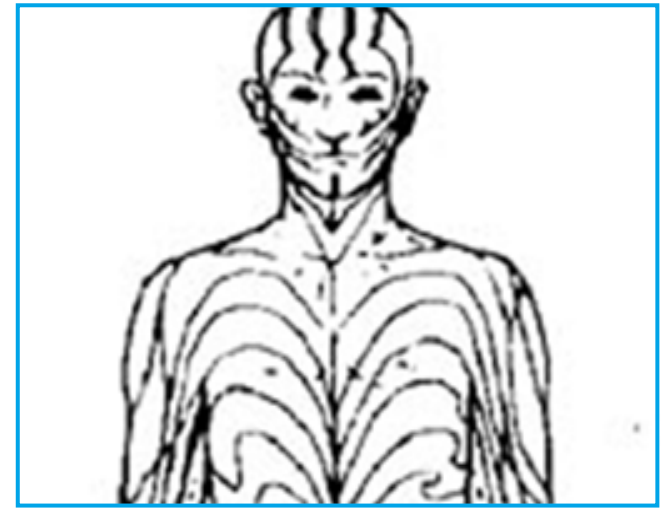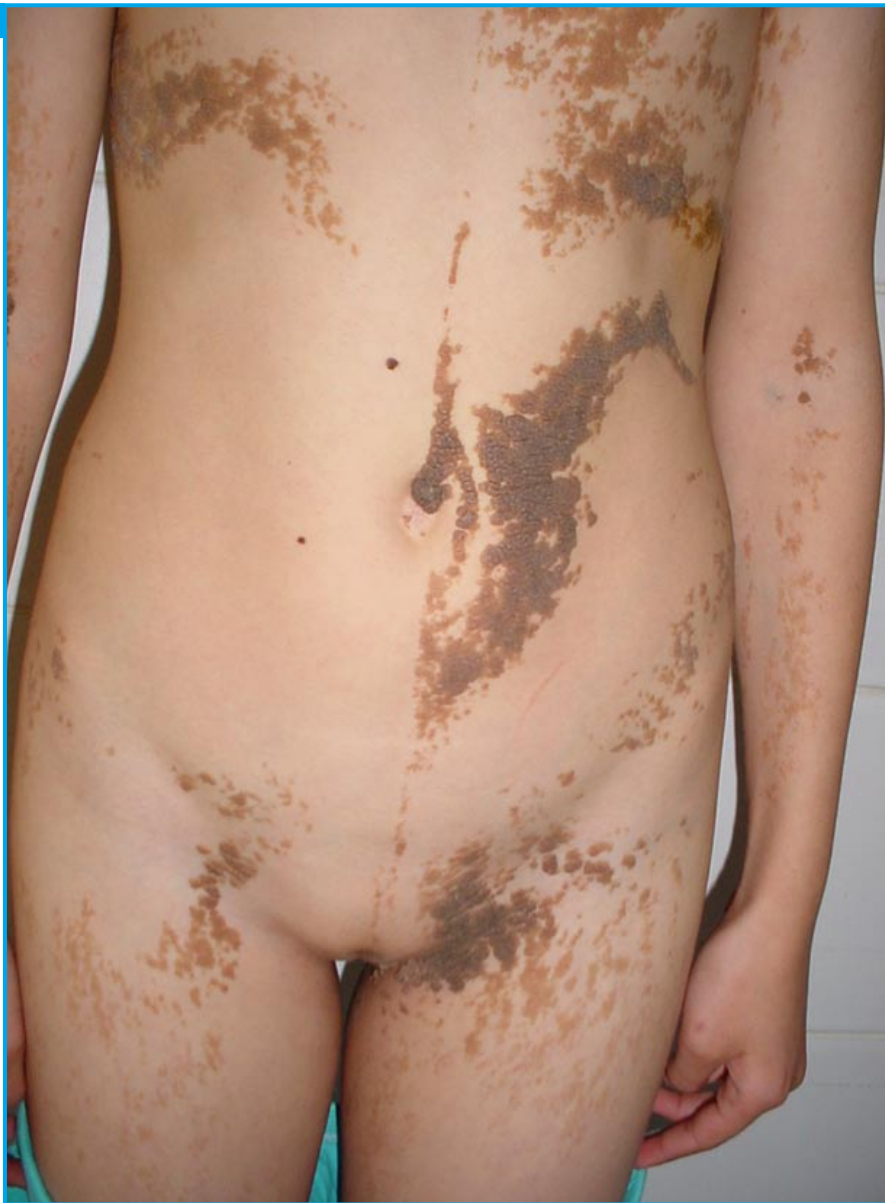Varicosités



Métamère

Métamère

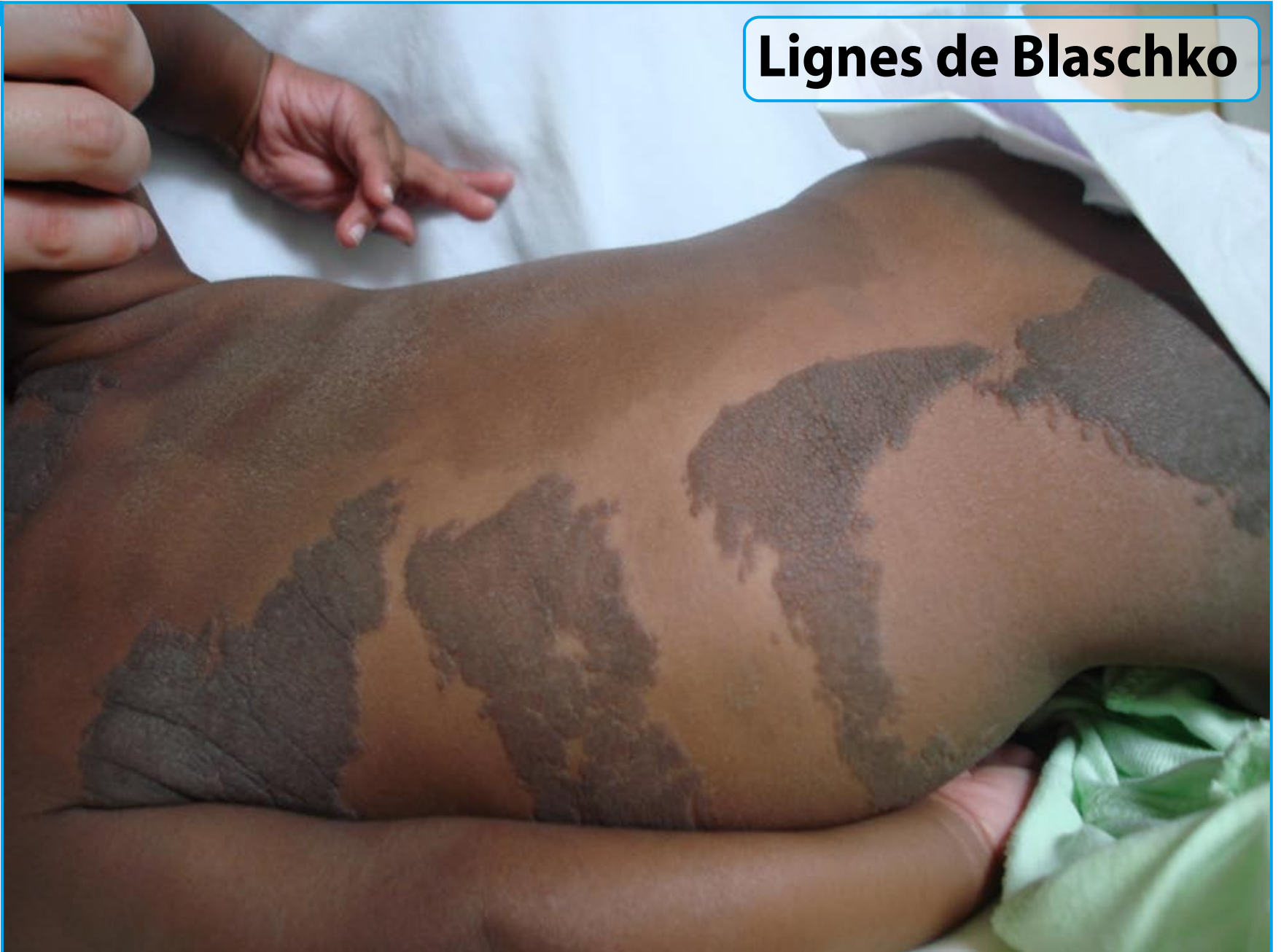


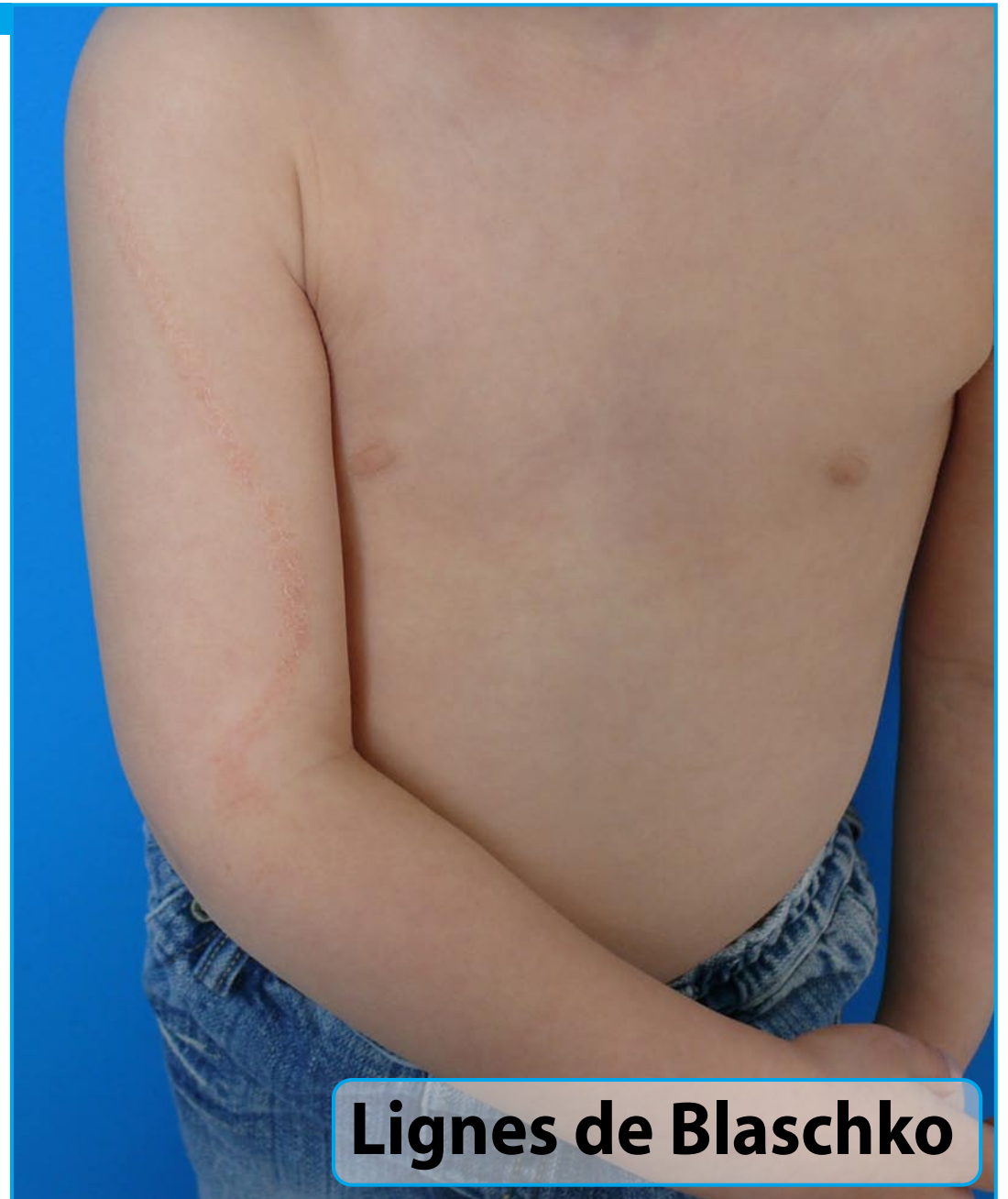
■ Lignes de Blaschko

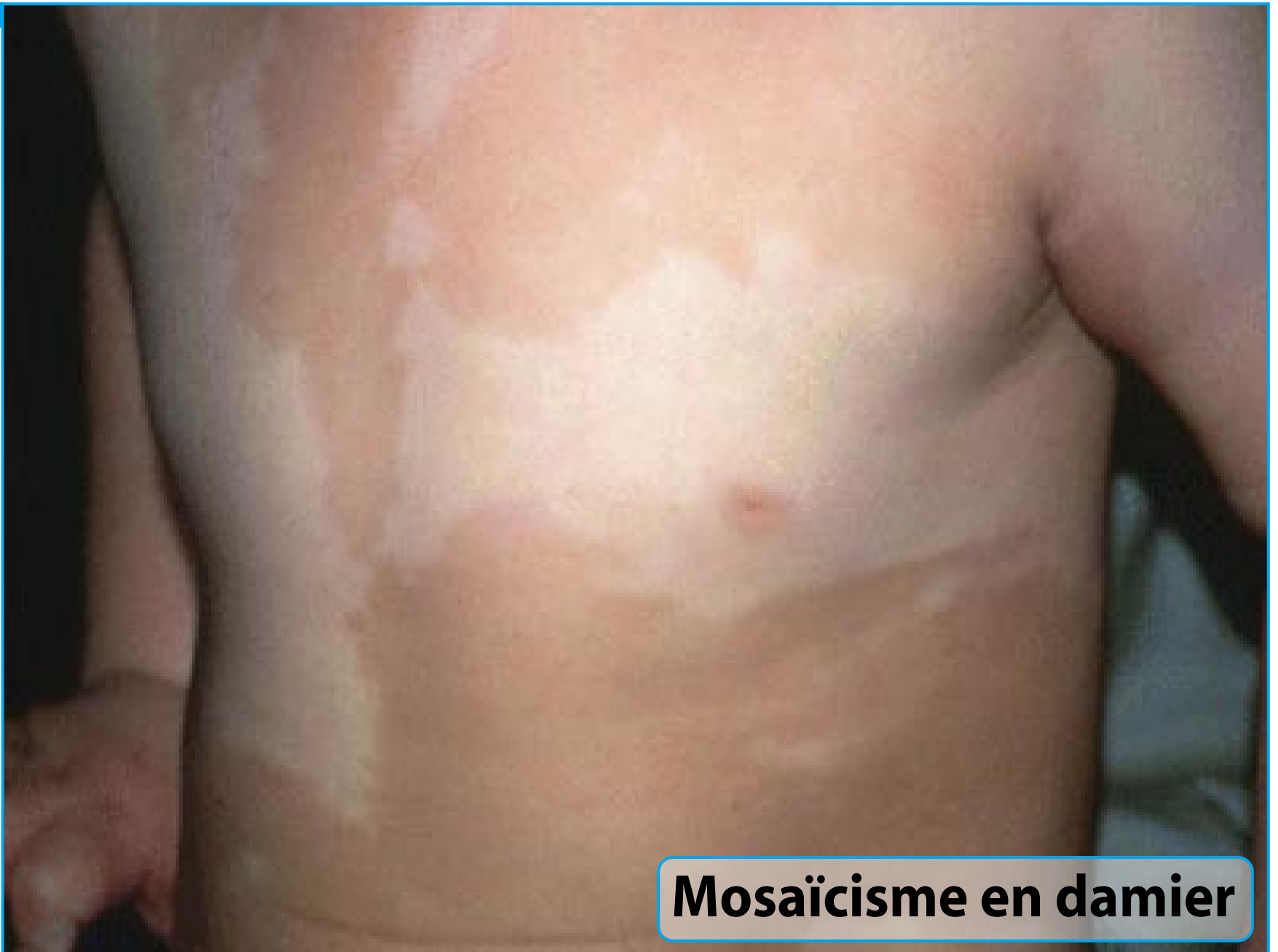■ Revêtement cutané

Lignes de Blaschko



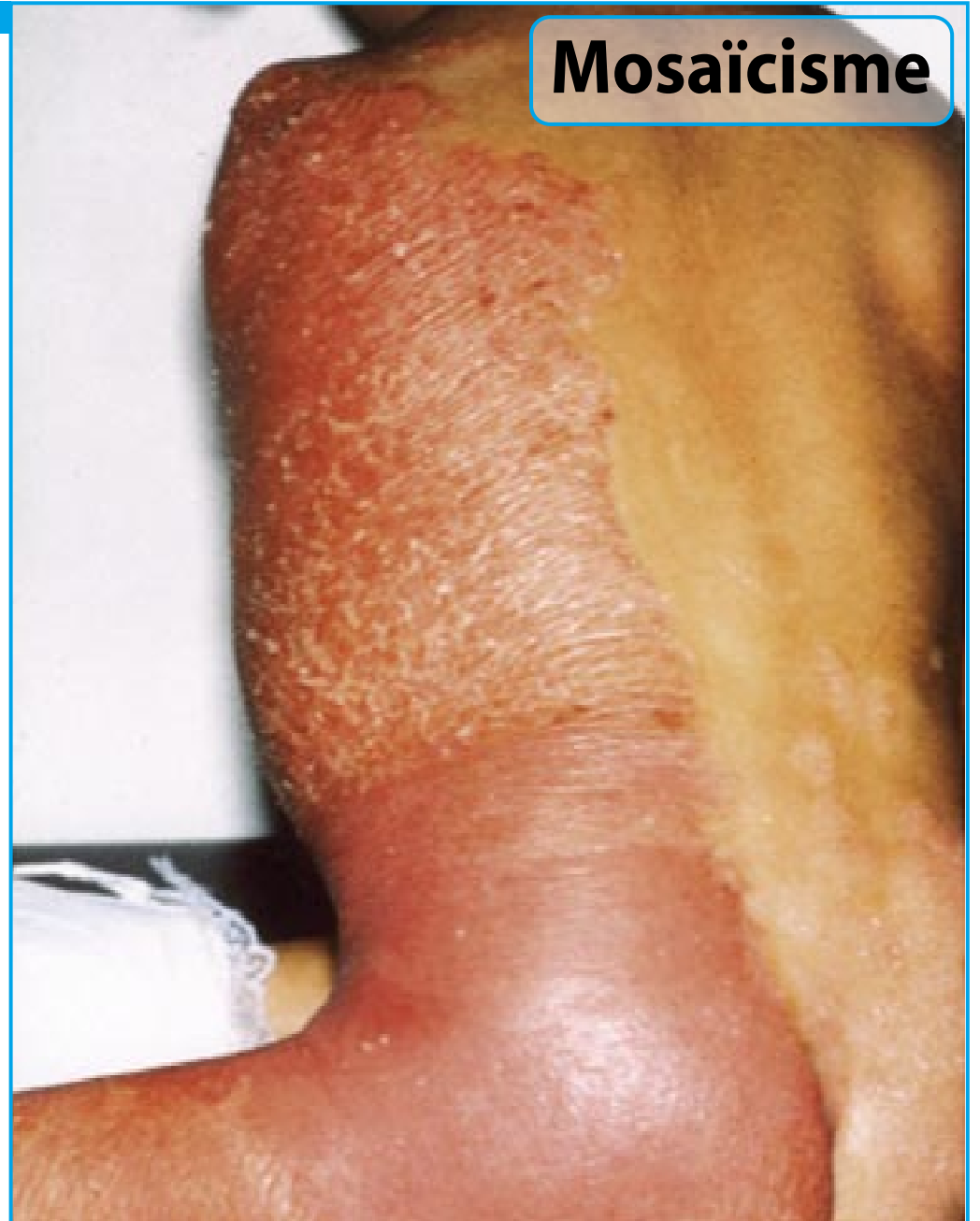

Lignes de Blaschko

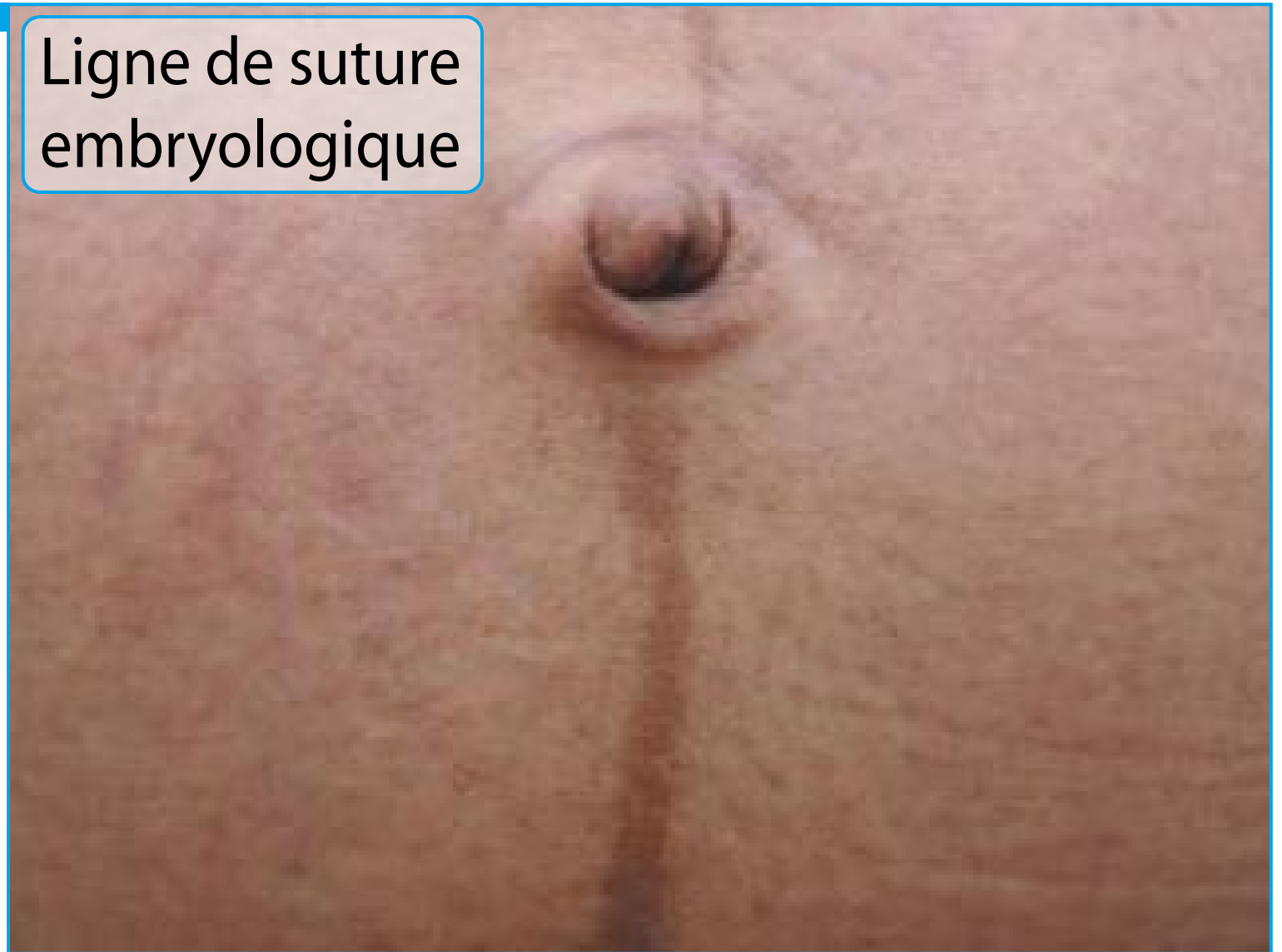

Mosaïcisme en damier

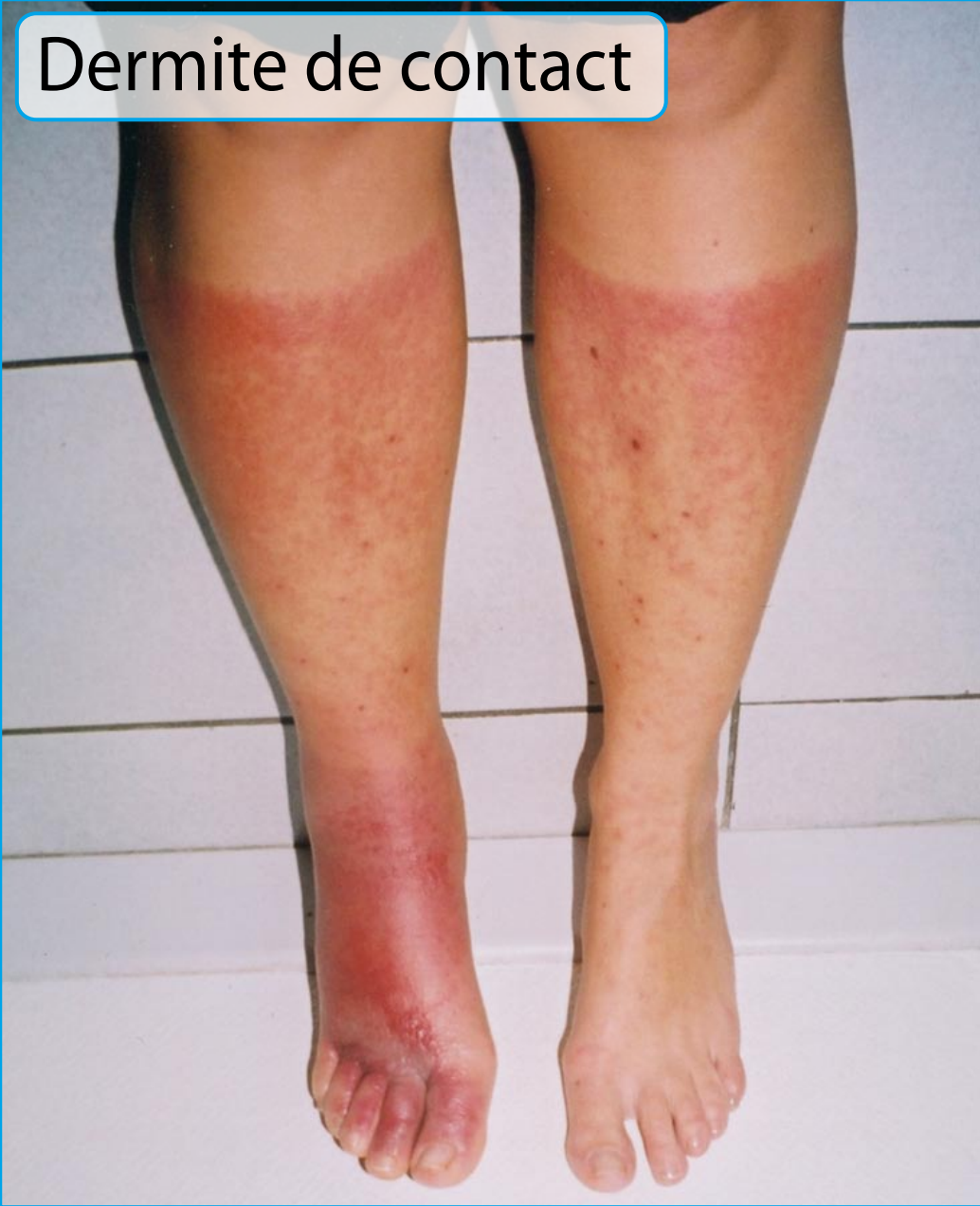Mosaïcisme



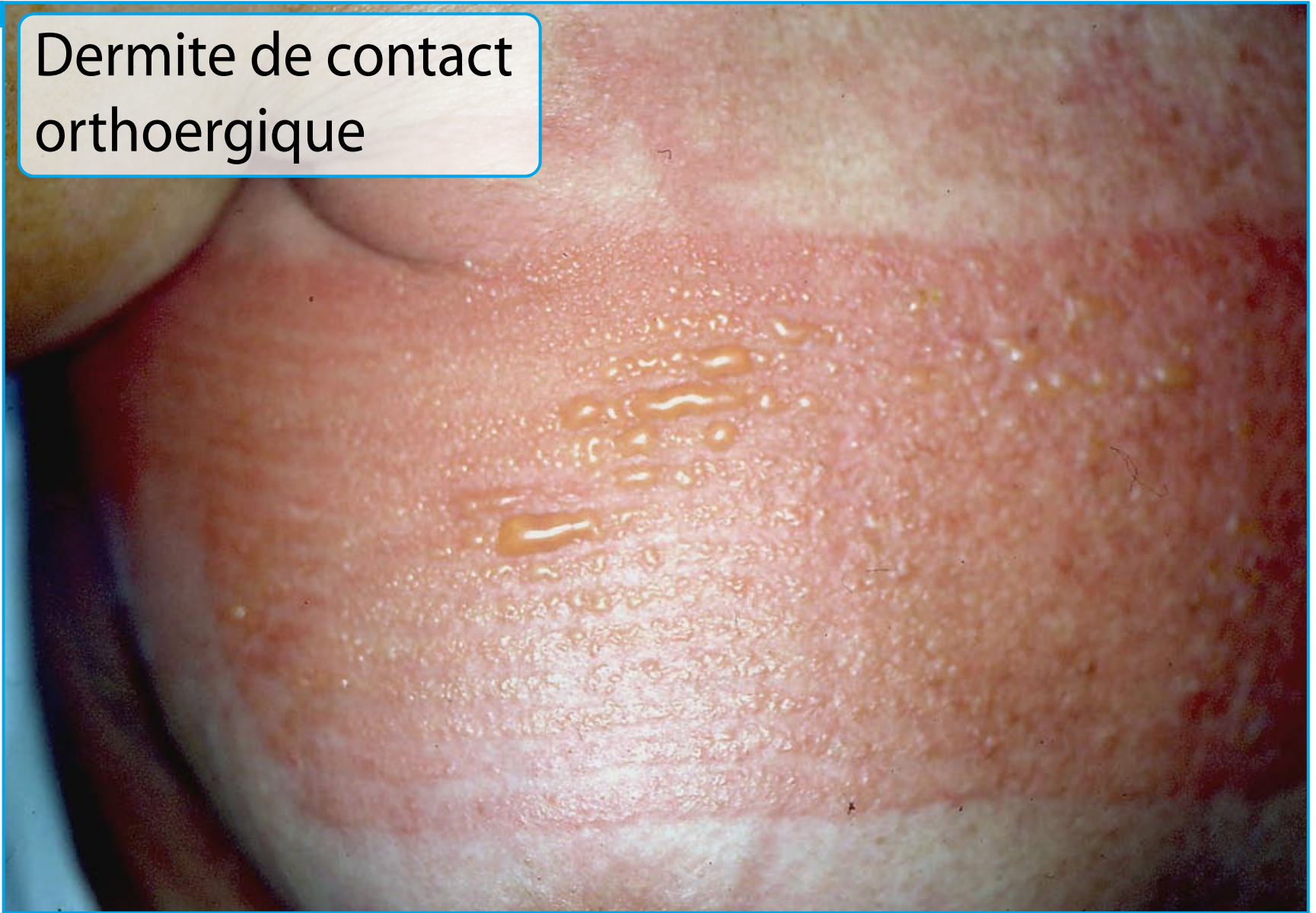Ligne de suture
embryologique

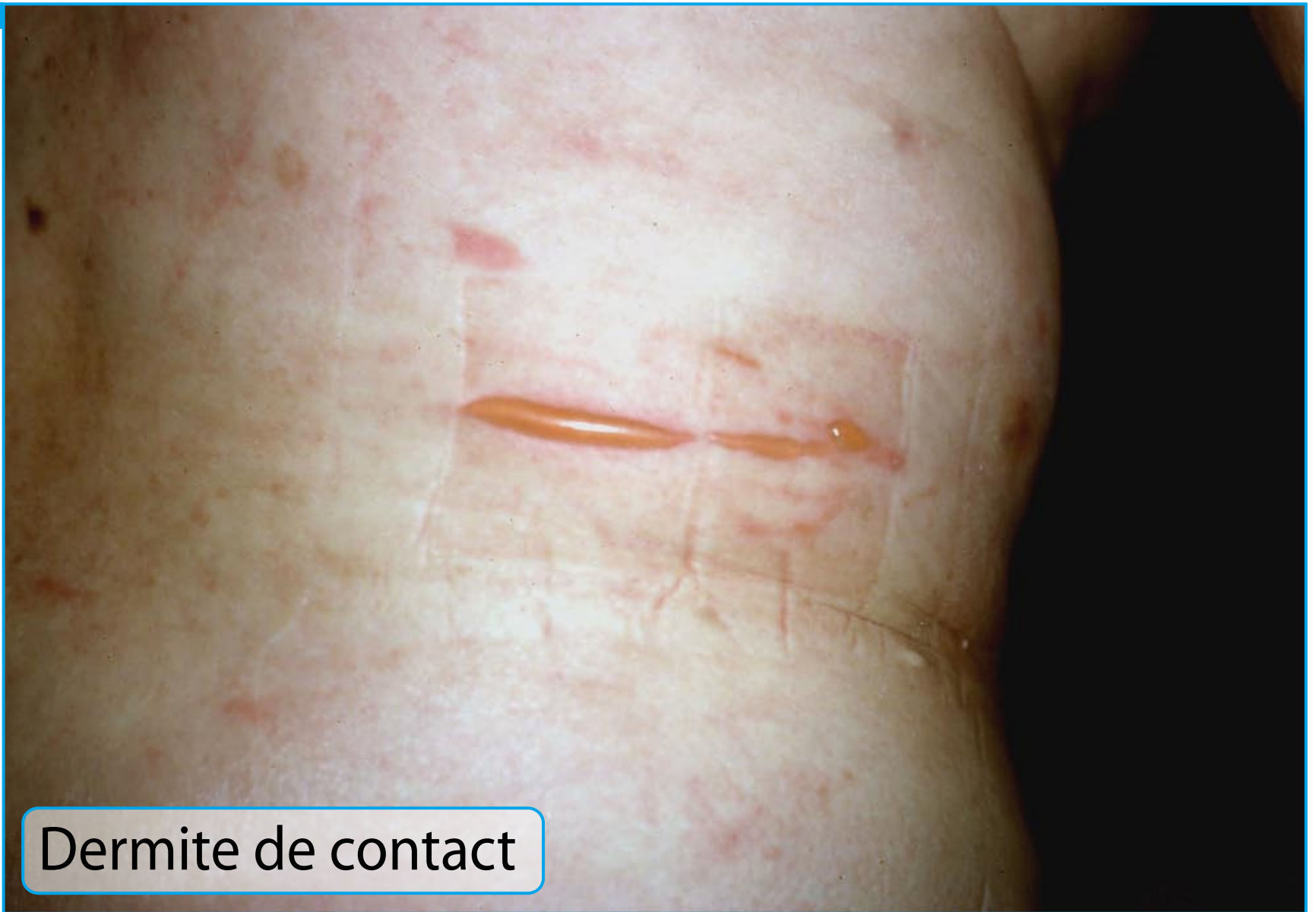

Dermite de contact



Dermite de contact
orthoergique



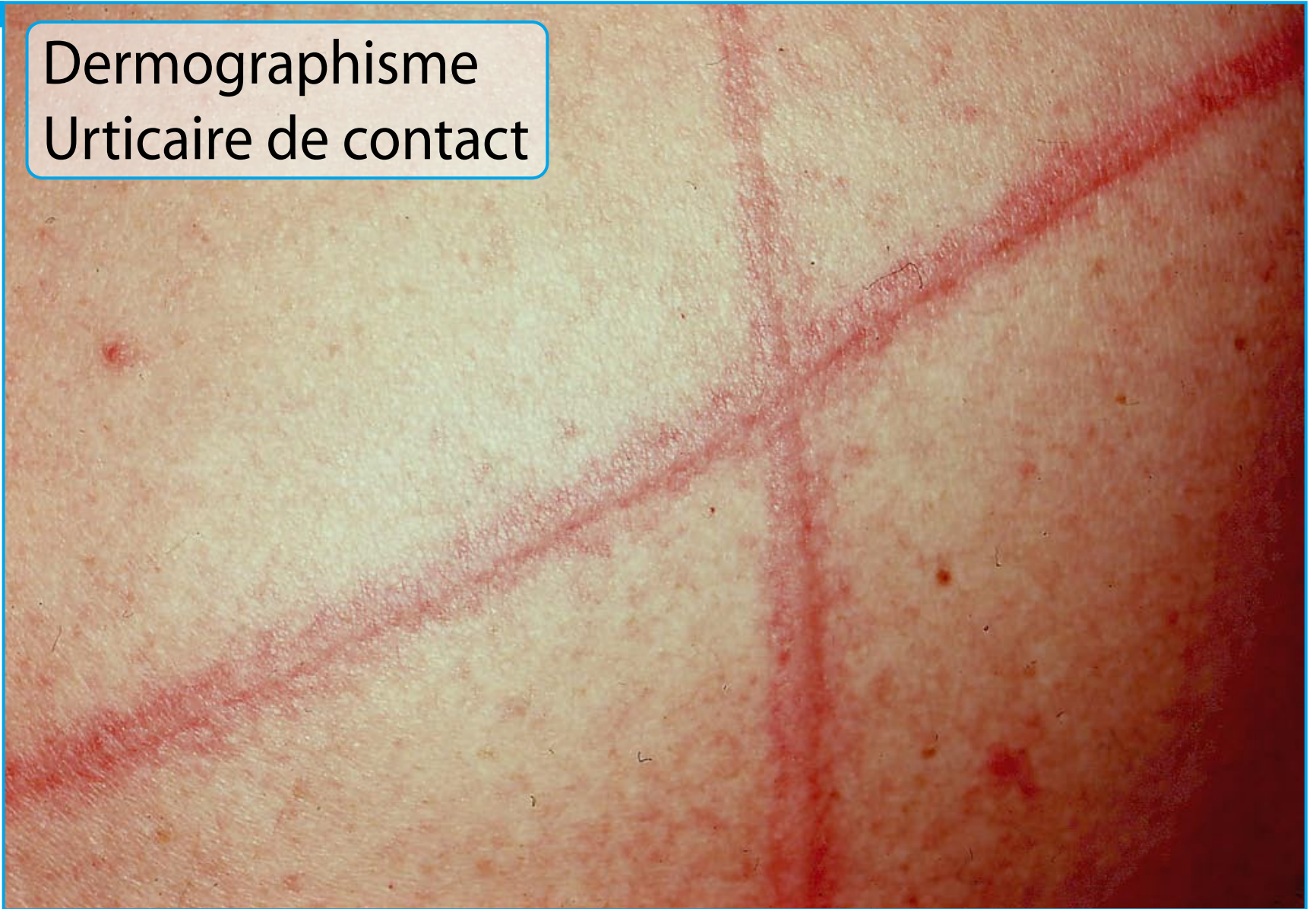

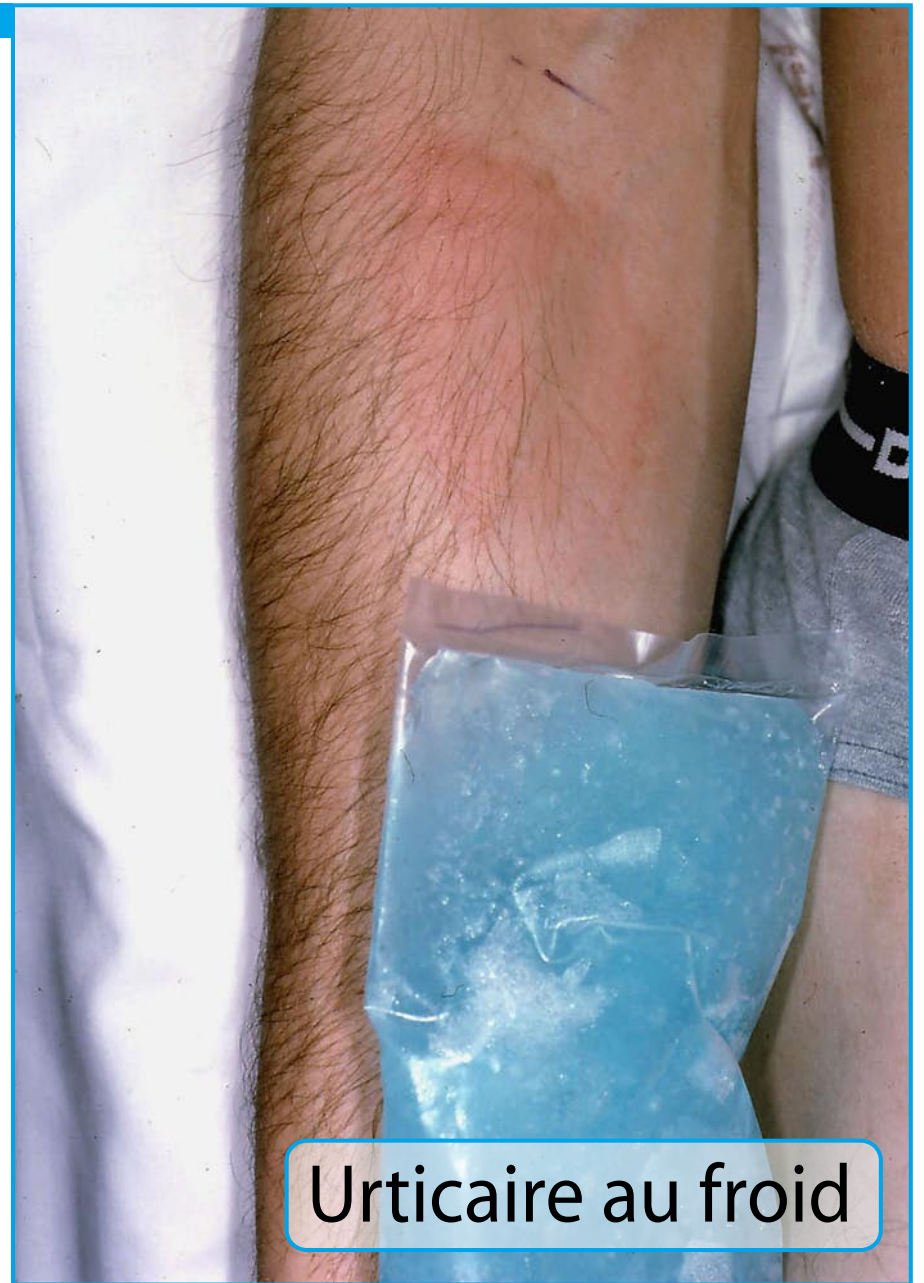Dermite de contact



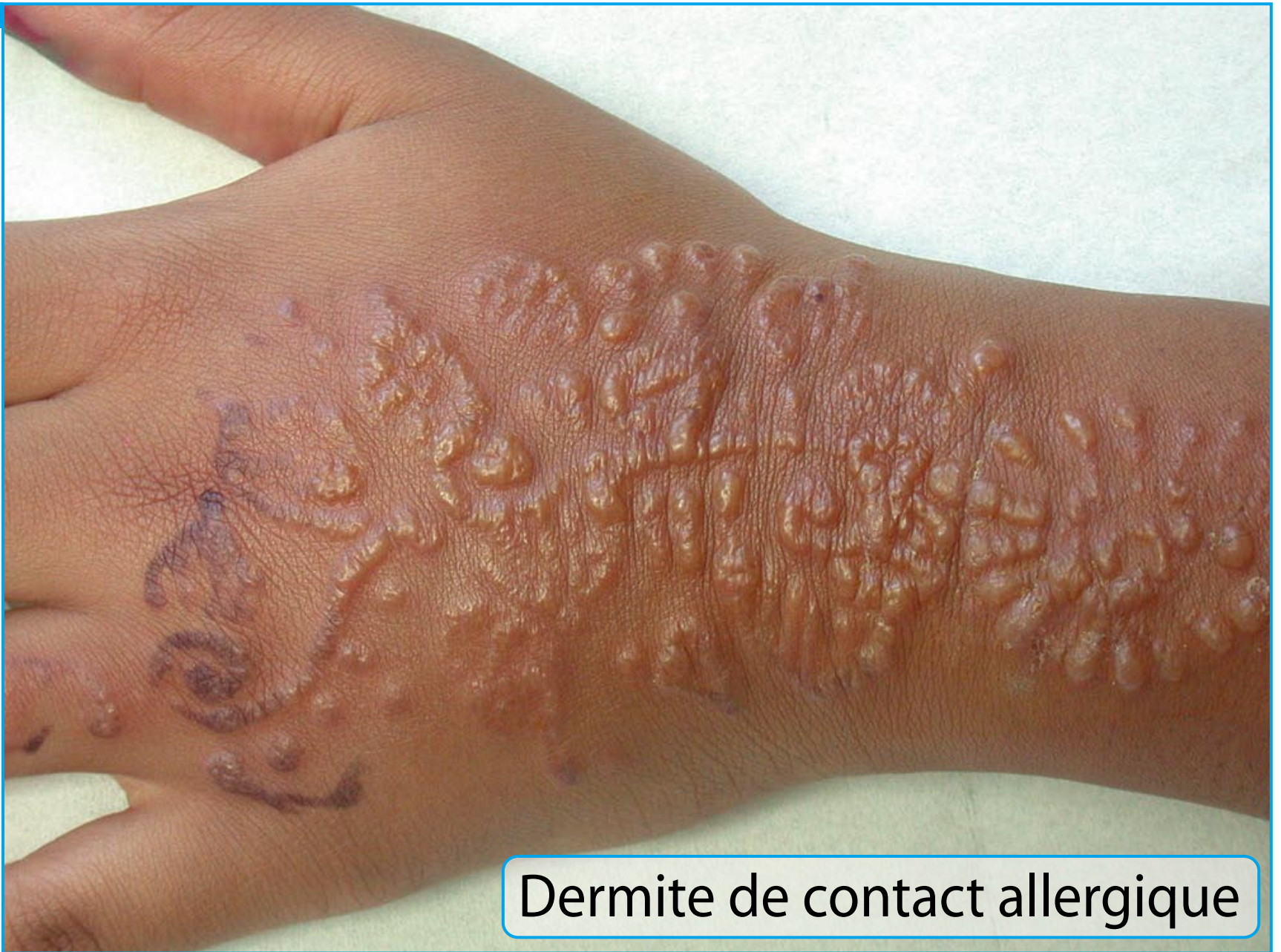Dermite de contact

Dermographisme
Urticaire de contact



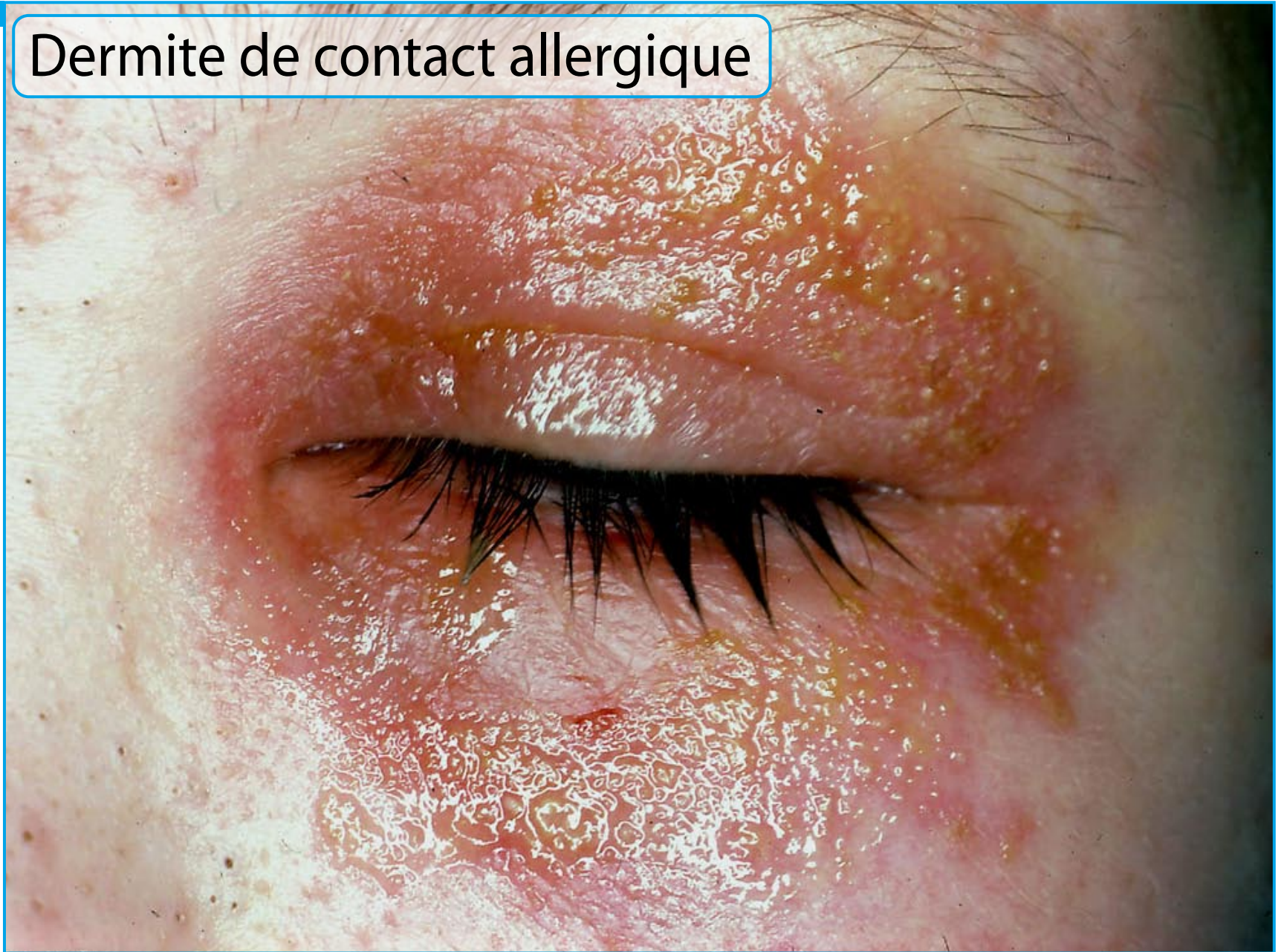

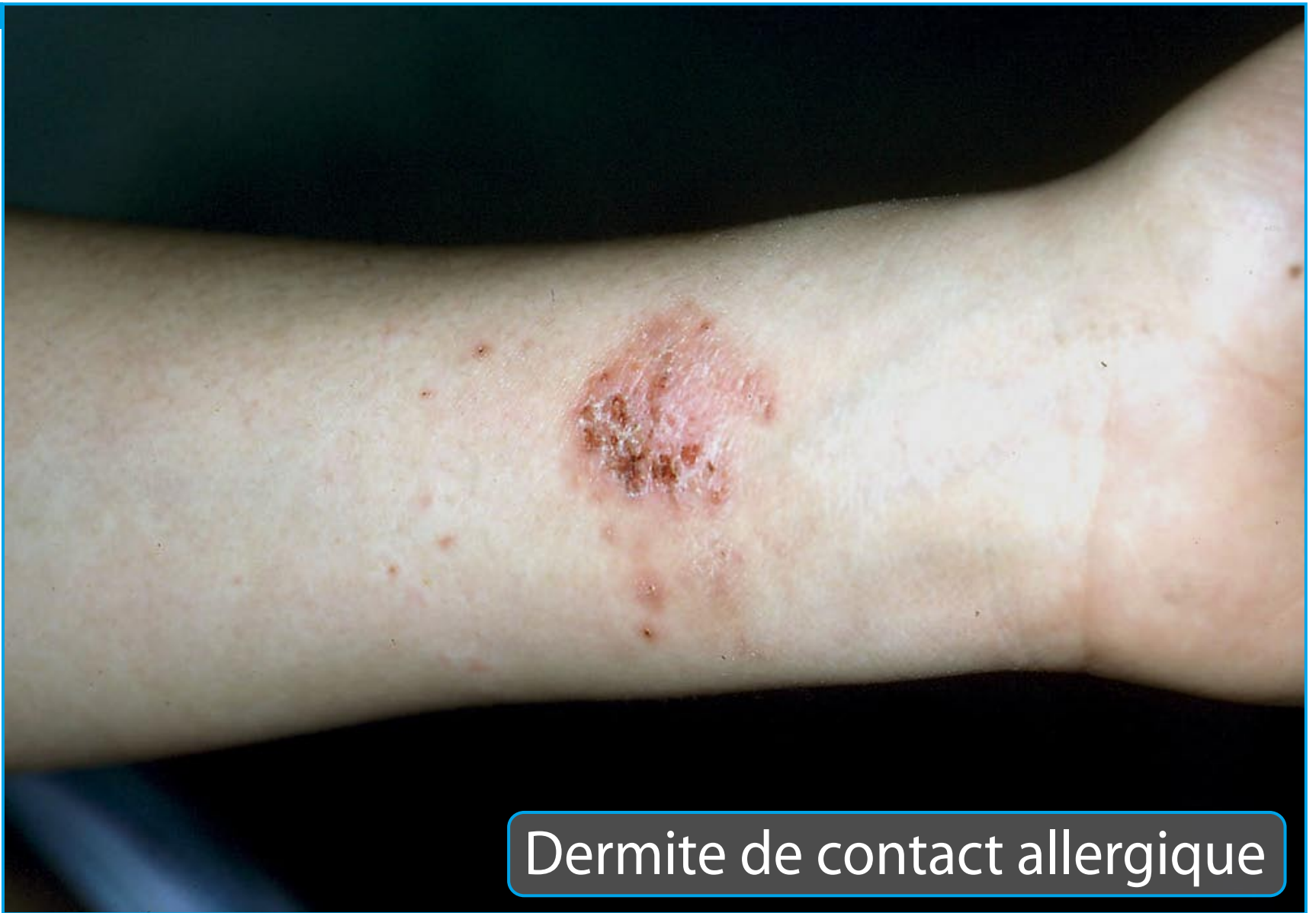Urticaire au froid



Dermite de contact allergique

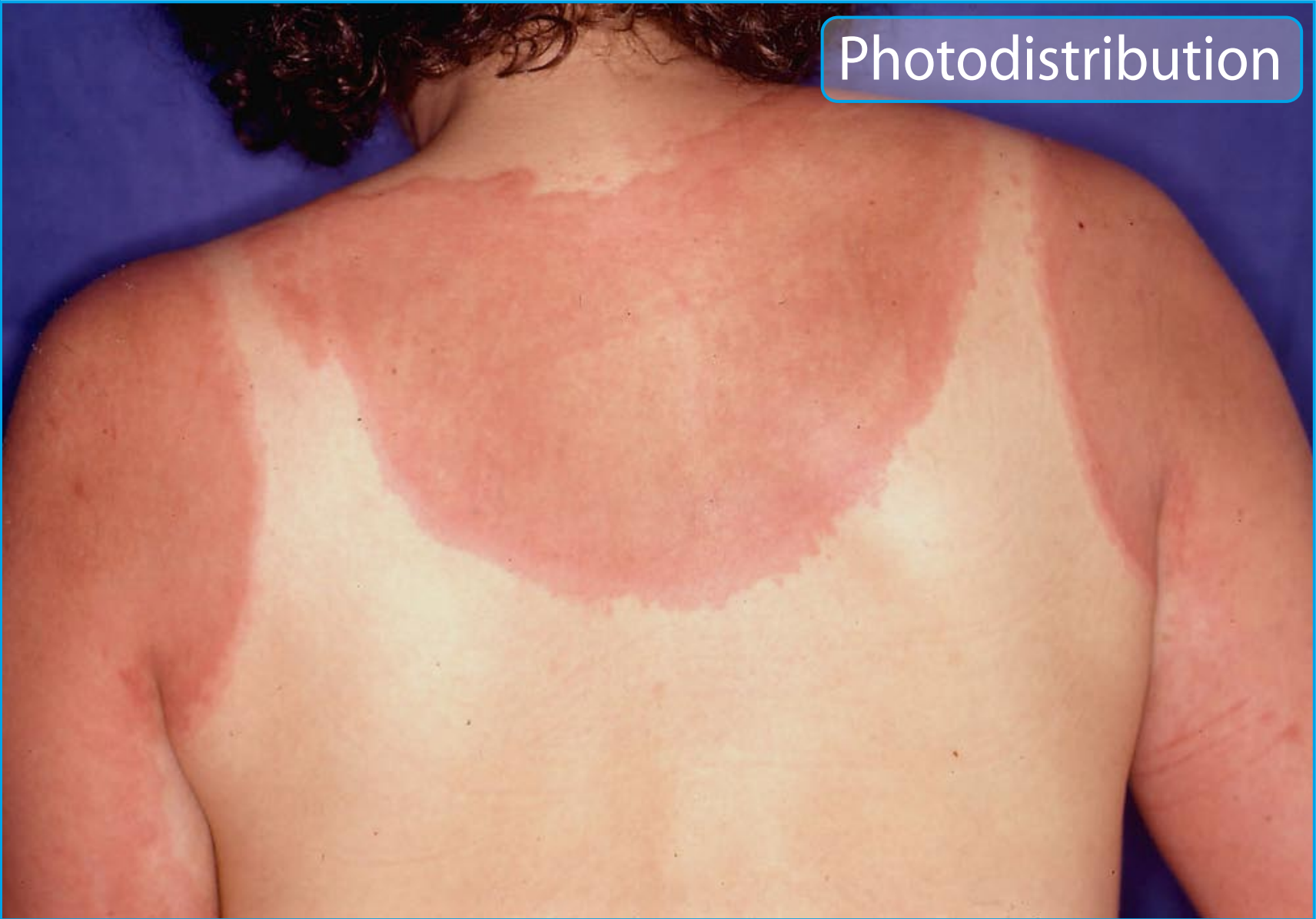Dermite de contact allergique

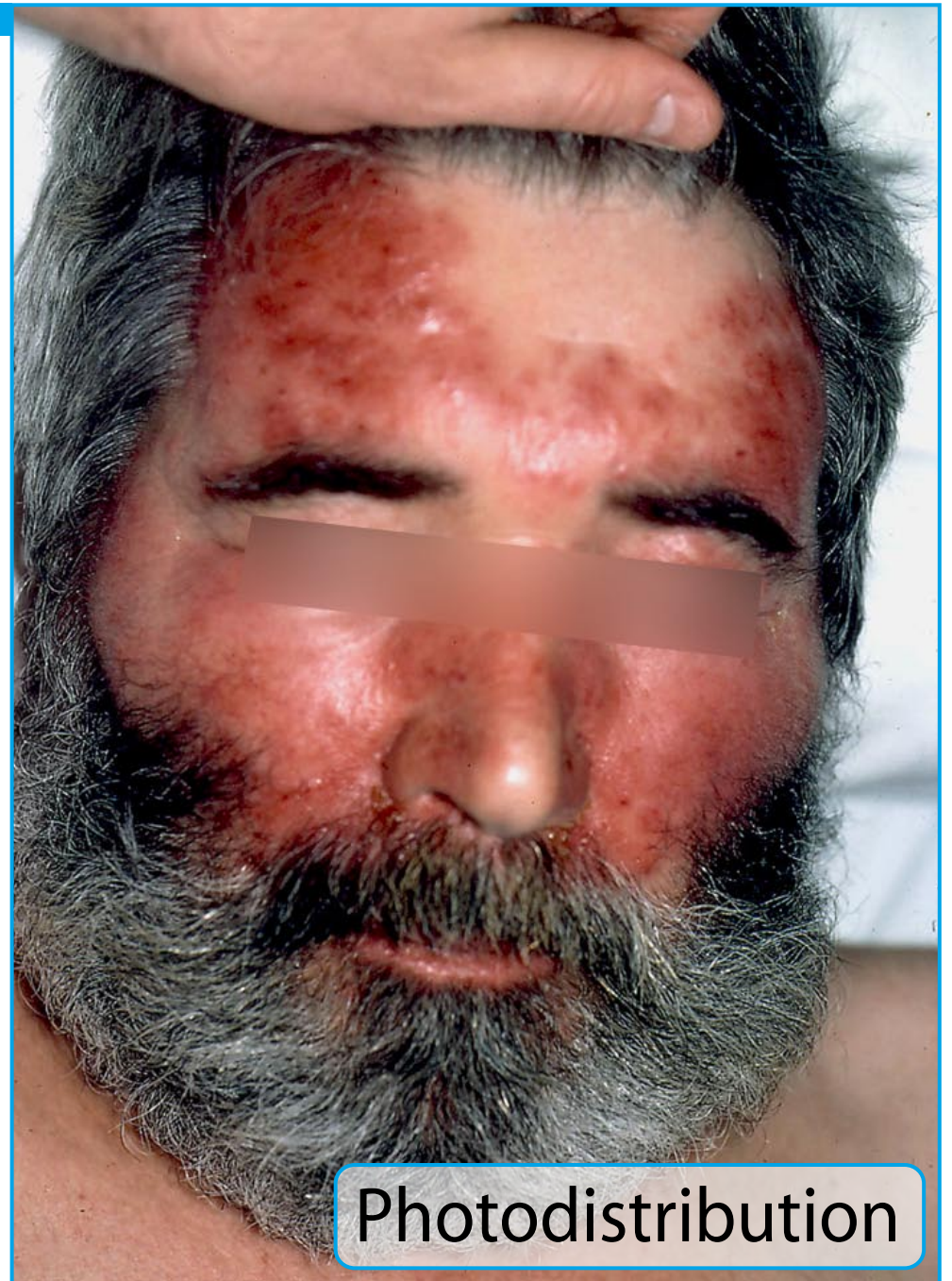



Dermite de contact allergique

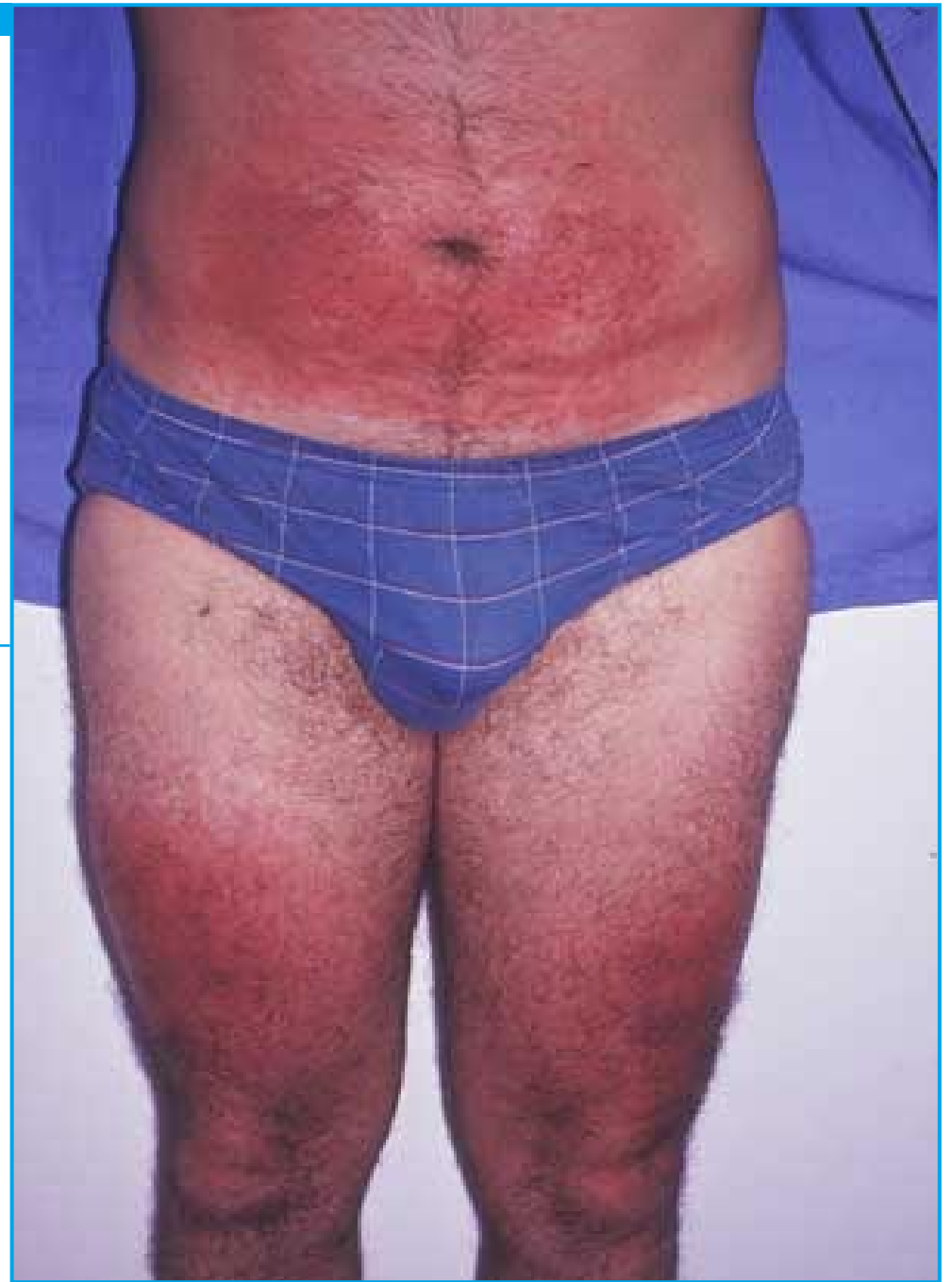Photodistribution



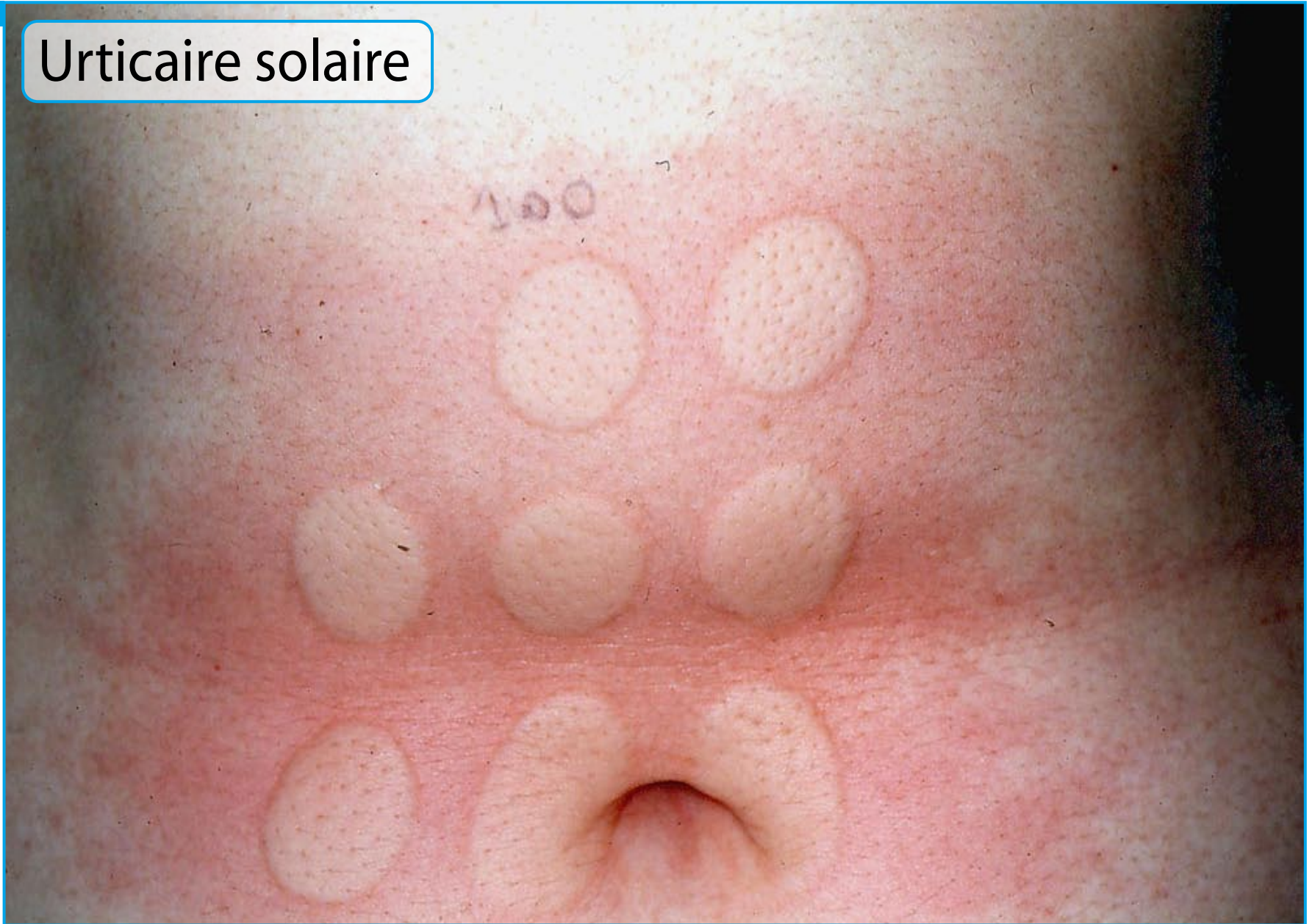


Photodistribution

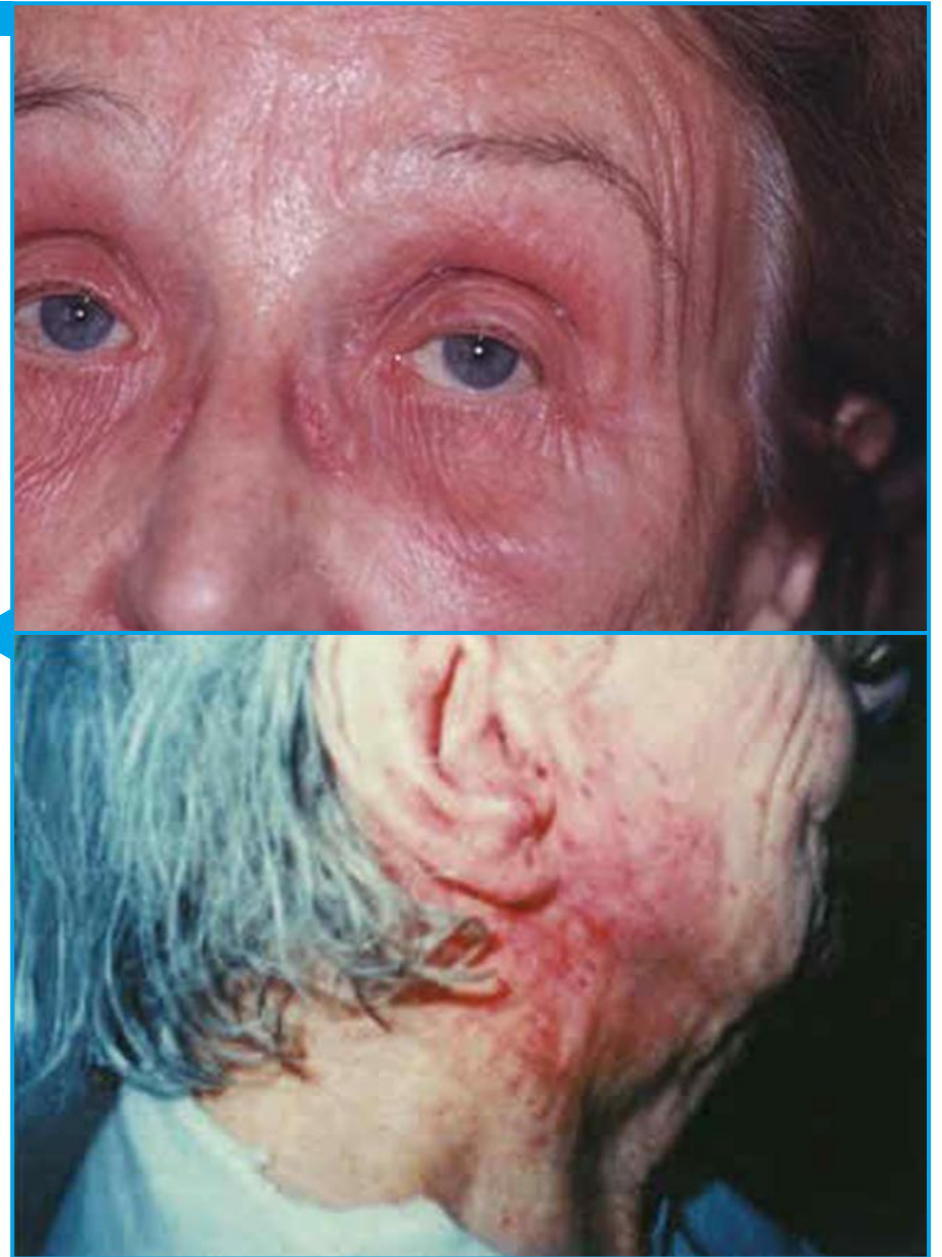■ Photodistribution
Photo-allergie



Urticaire solaire



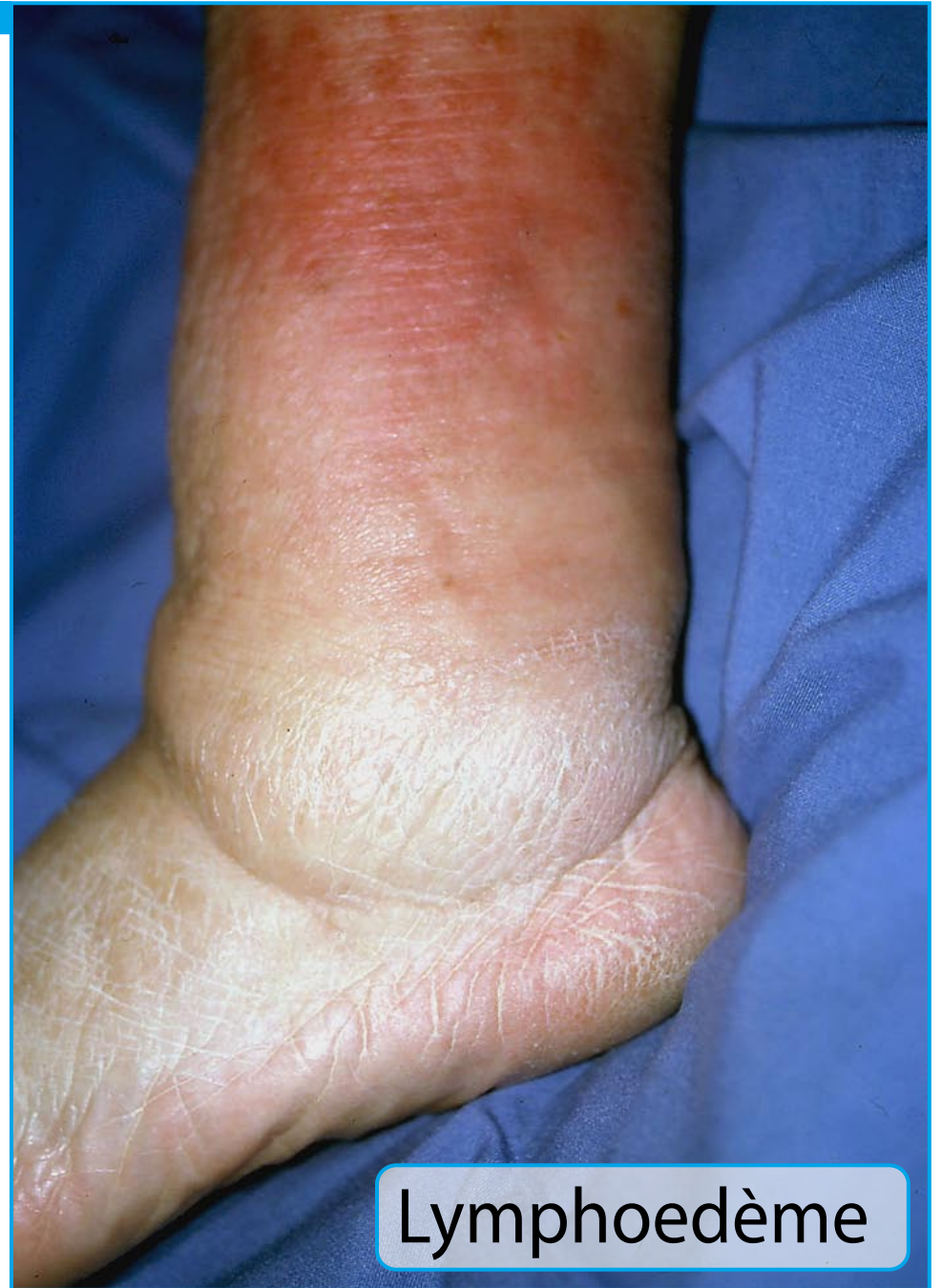Aérodistribution
allergie
de contact



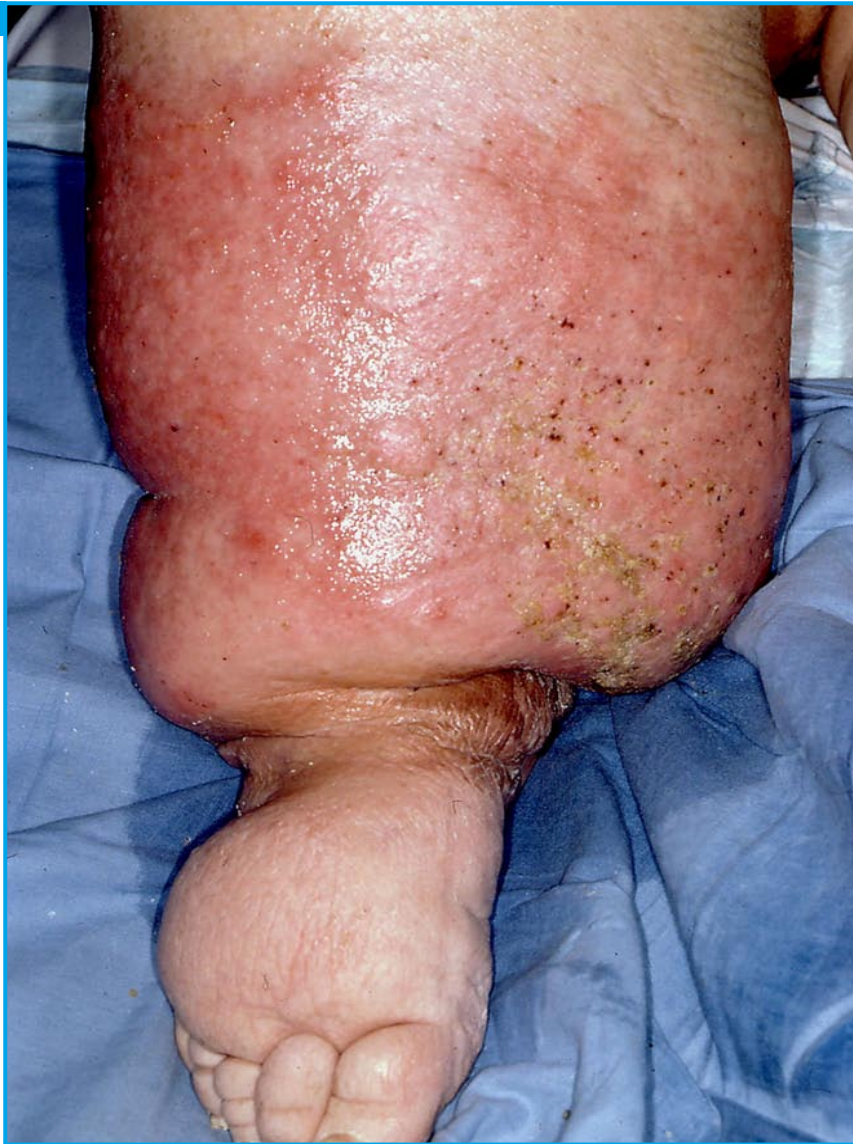Oedèmes

■ Dr. Anne Croué

■ Pr. Ludovic Martin



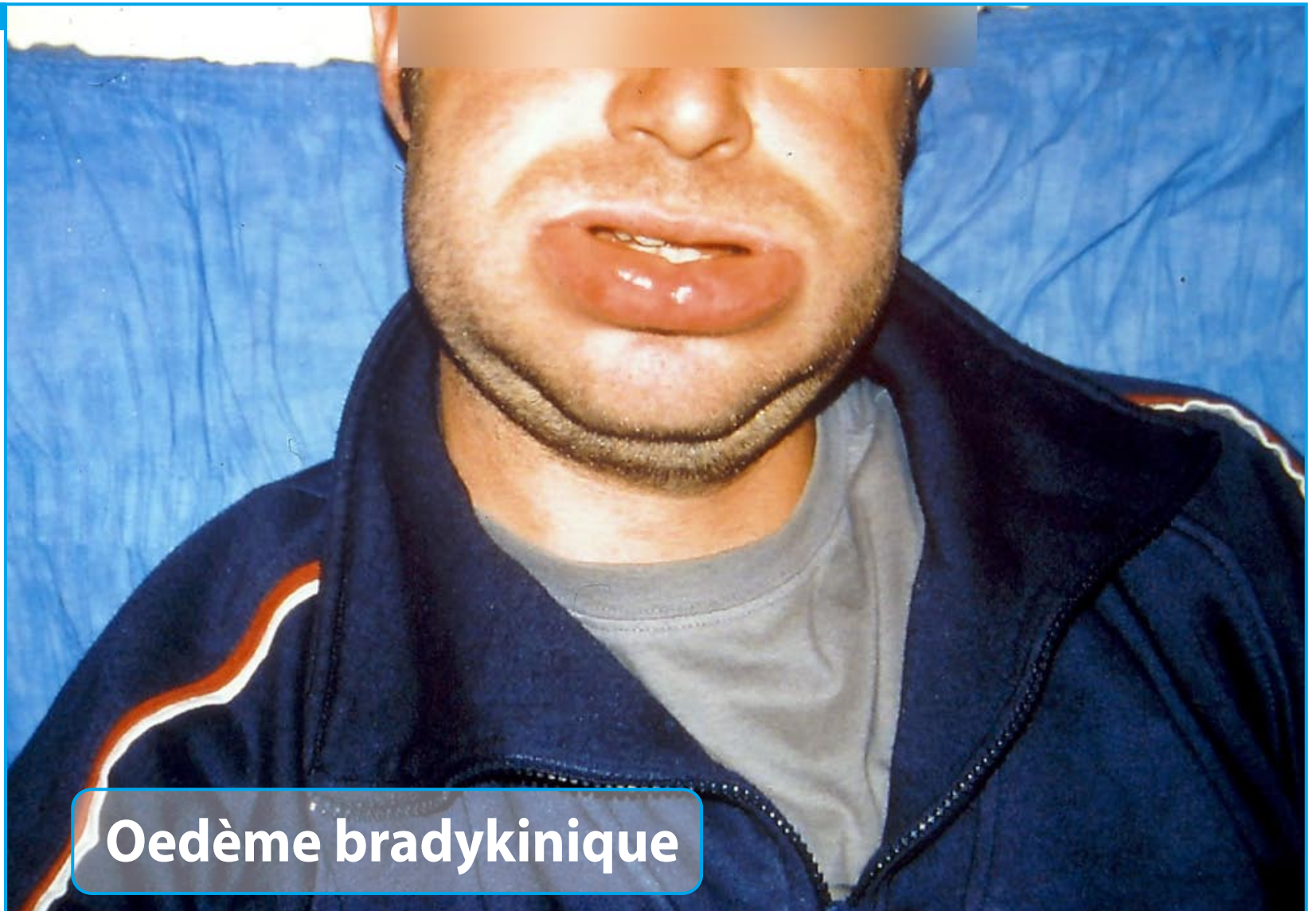Lymphoedème



Lymphoedème

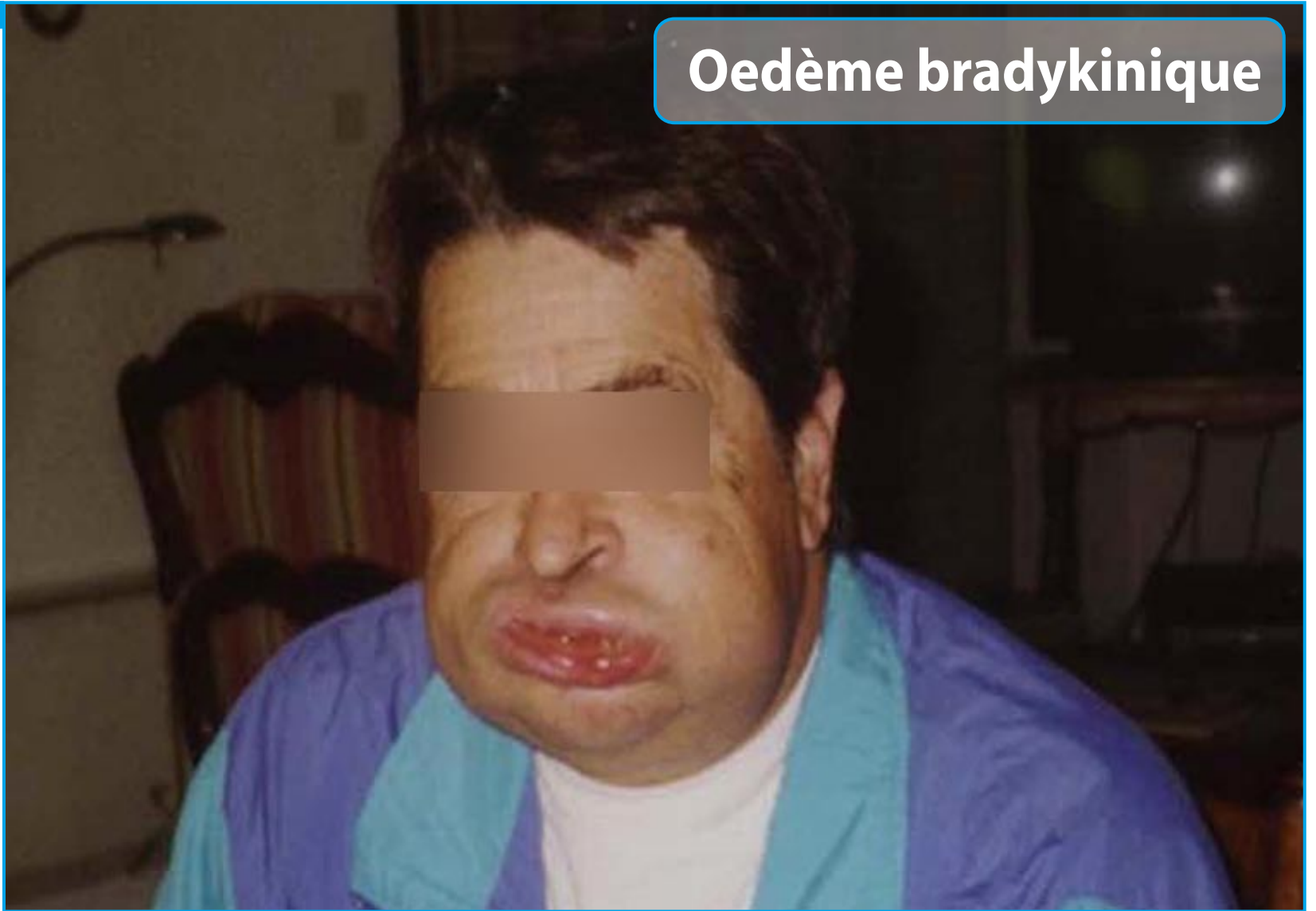Éléphantiasis

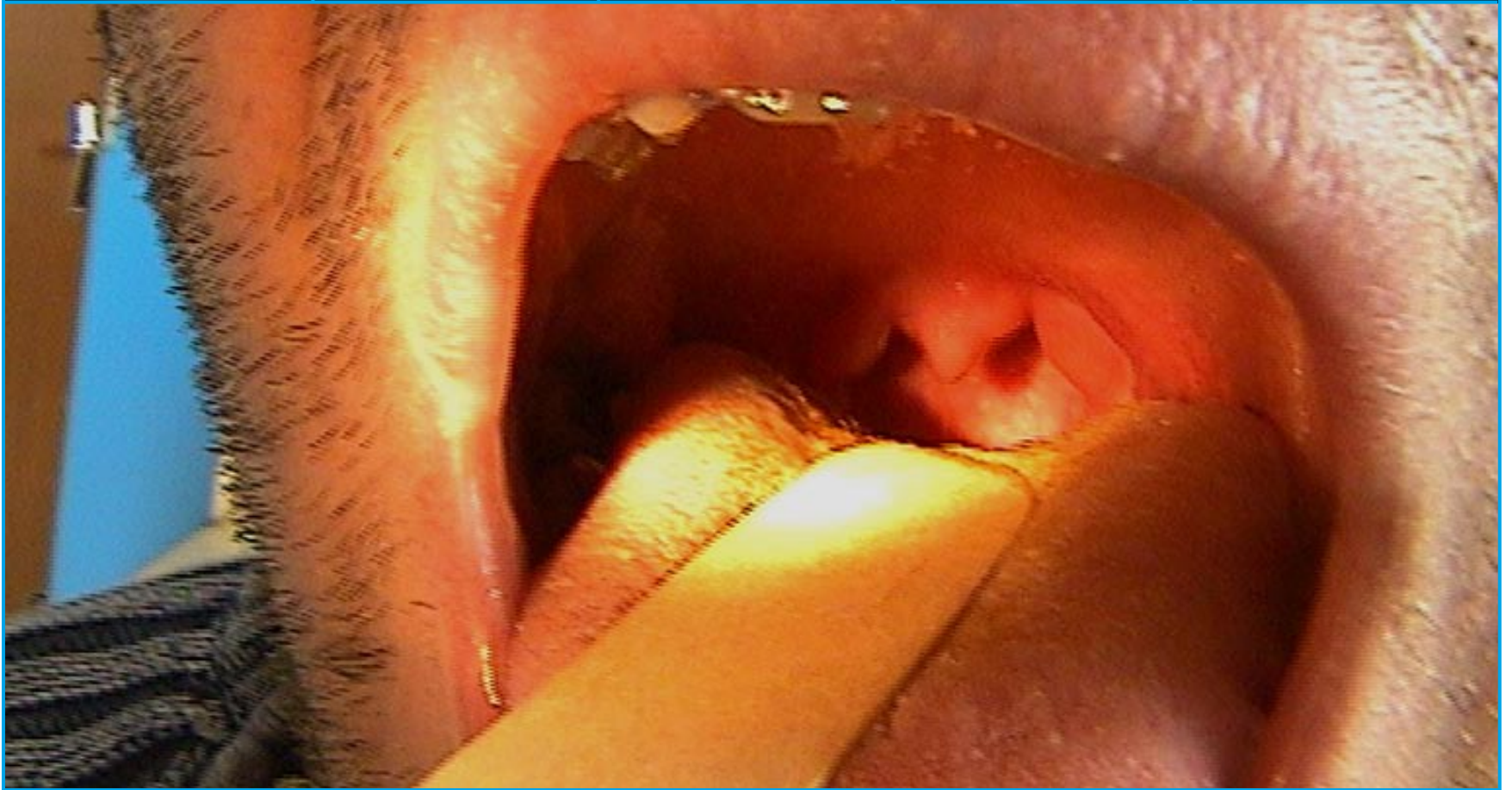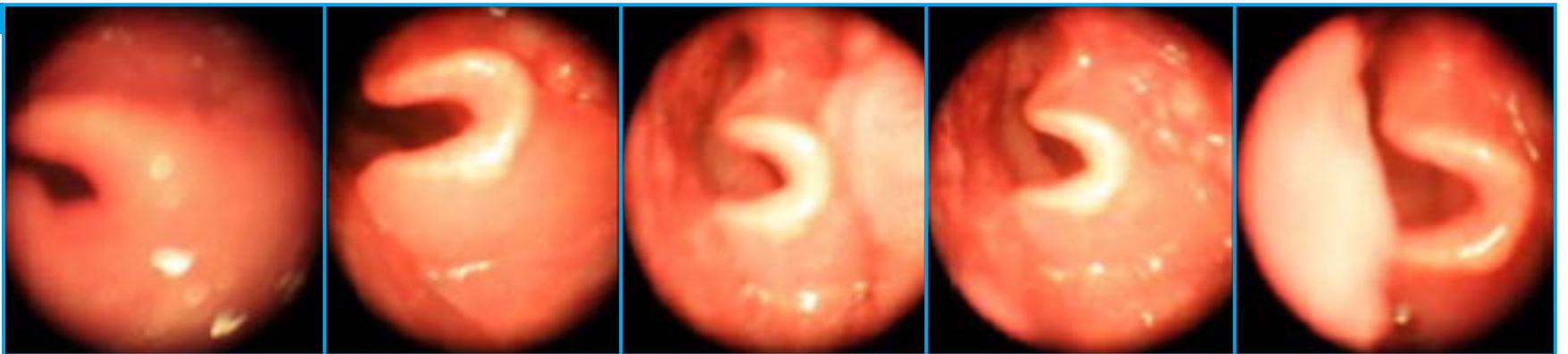
Signe de Stemmer



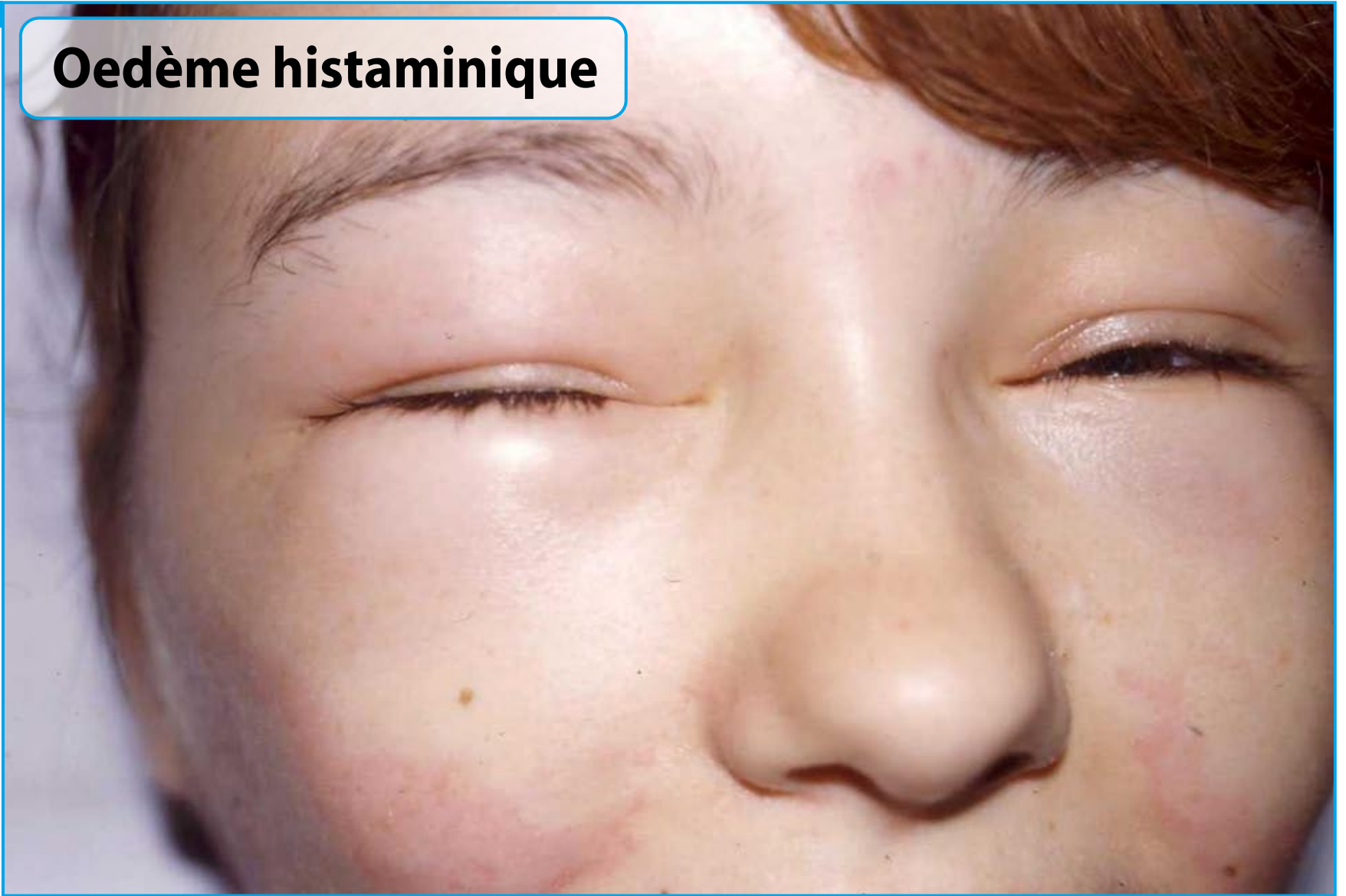Oedème bradykinique

Oedème bradykinique





Oedème histaminique





■ Conception graphique | teddy.louisy@univ-angers.fr | 02.41.22.69.89

■ STIC : 02.41.22.69.80 | stic@listes.univ-angers.fr